PHACOEMULSIFICATION SURGERY

AN INTERACTIVE MULTIMEDIA ATLAS FOR OPHTHALMOLOGY TRAINEES

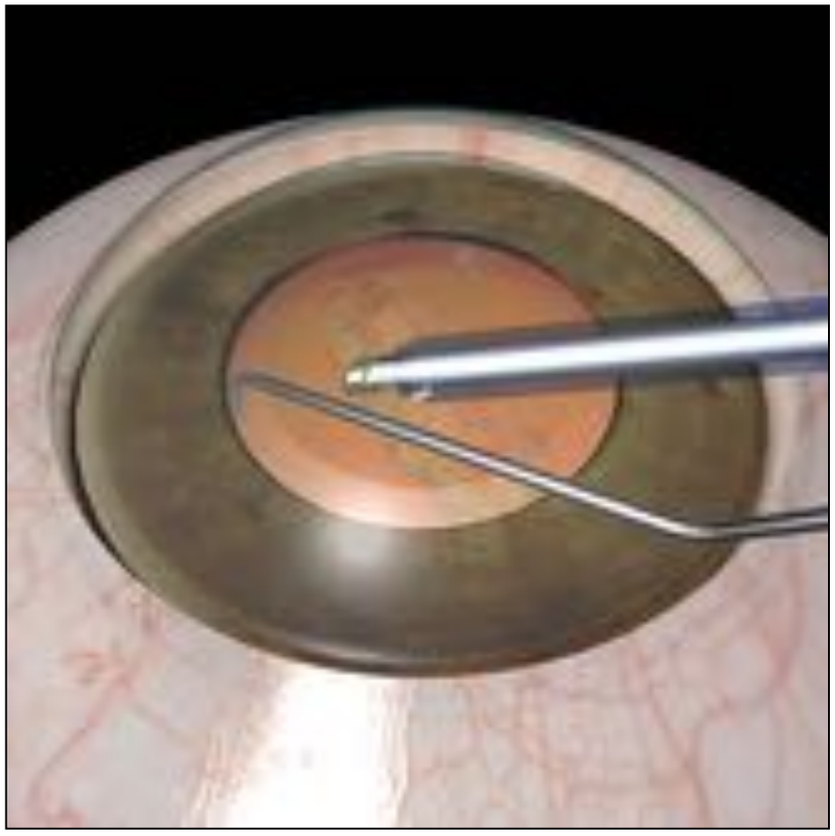

Paul Sullivan Larry Benjamin Brian Little

BAUSCH + LOMB

PHACOEMULSIFICATION SURGERY

AN INTERACTIVE ATLAS FOR OPHTHALMOLOGY TRAINEES

Paul Sullivan
Consultant Ophthalmic Surgeon
Director of Medical Education
Moorfields Eye Hospital

Larry Benjamin
Consultant Ophthalmic Surgeon
Buckingham Healthcare NHS Trust

Surgery Skills Sub-committee Chair,
Royal College of Ophthalmologists

President, UK & Ireland Society of Cataract and Refractive Surgeons

Brian Little
Consultant Ophthalmic Surgeon and
Cataract Training Director
Moorfields Eye Hospital
London

Past-President, UK & Ireland Society of Cataract and Refractive Surgeons

© 2018 Eyelearning Ltd.

Published by Eyelearning Ltd.
London
www.Eyelearning. Co.uk

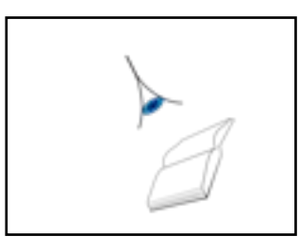

DEDICATION

We wrote this book for all ophthalmology trainees everywhere in the hope that they do not make all the mistakes we did at their stage.

It is dedicated to our wives for putting up with us.

Acknowledgements

The authors would like to thank the following who have contributed to this book:

Sid Liyanage Omar Mahroo Lav Joshi Mani Bhogal Julian Stevens Conor Ramsden Nicky Brennan Paul Ursell

This book was supported through an Unrestricted Educational Grant from Bausch & Lomb.

Versions of this book

There are 2 versions of this book:

- A pdf readable on all devices. The interactive features (videos, image galleries and knowledge reviews) do not work in this version.
- An electronic book which can only be read using the latest version of the Apple iBooks reader on iPads, iPhones and Apple computers.

If you have access to an iPad or Apple computer the interactive version of the book can be downloaded free from iTunes or the iBookstore.

Preface

This book has been designed to be dipped into, following links or using the search function to find areas of interest, rather than read from beginning to end. It is a practical educational tool for ophthalmology trainees, not a comprehensive well referenced textbook on every aspect of cataract surgery.

This book has been designed as an atlas for visual learners - most of the information can be gleaned by ignoring the text and looking at the picture galleries and movies.

The Eyelearning web site may be of interest to anyone who finds this book useful. You may also be interested in the previously published books in the series - 'The Open Globe' (which deals with the principles of ocular trauma repair) and 'Vitreoretinal Surgery'. Both are available free of charge from the Apple iBook store.

The number of videos in this book is limited by the maximum file size on ebooks. The Eyemovies DVD series features several hours of high quality instructional videos on cataract surgery,

All versions of this book are completely free. If you find it useful please consider a donation to a charity such as Moorfields Eye Charity , Fight For Sight or Orbis or to Wikipedia.

This book is a work in progress - the next edition is currently being written. It will be extended to cover the prevention and management of capsular trauma and vitreous loss. It will be published in October 2021.

NAVIGATING IN THIS BOOK

Many of the images are actually interactive widgets. The function of most is obvious. Some are 3d renders. These have been used sparingly as some people have difficulty using them. To view these the reader should fixate on the images and then let the eyes drift apart. At this stage 3 images will be seen and a conscious effort is made to look at the central image.

Figure Preface.1 Navigating backwards

Touching a blank area of the screen activates the menu bar. The small page icon can be clicked.

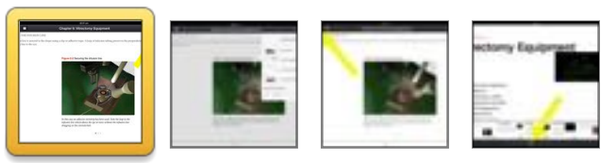

KNOWLEDGE REVIEWS

Each chapter in this book ends with a knowledge review. These assume some prior knowledge. Sometimes the information required to answer the questions is buried in one of the hyperlinks. These tests are designed to be used in a formative way (to learn, not to test). If the reader does not know the answer to a question they will learn more if they do their own research before coming back to the question rather than guessing the answer.

CHAPTER 1

Phacofluidics

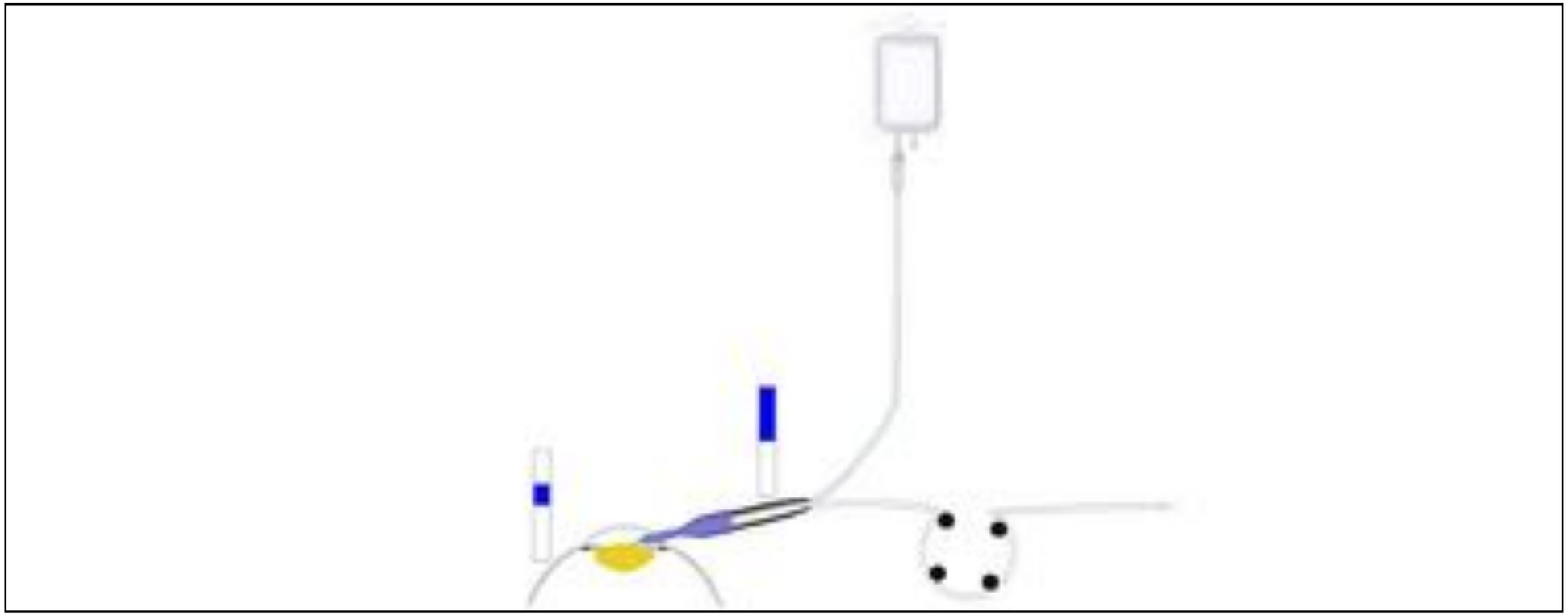

It is impossible to perform phacoemulsification safely without an understanding of the underlying physical principles employed by phacoemulsification machines. This chapter is a brief introduction to a very complicated subject. For further reading the author would strongly recommend Barry Siebels' excellent book on phacodynamics (ISBN: 9781556426889).

Introduction (Please double click on the image below)



The Handpiece

The handpiece design reflects its 3 functions:

- Infusion
- Aspiration
- Emulsification

Interactive 1.1 The handpiece

Interactive 1.2 The handpiece

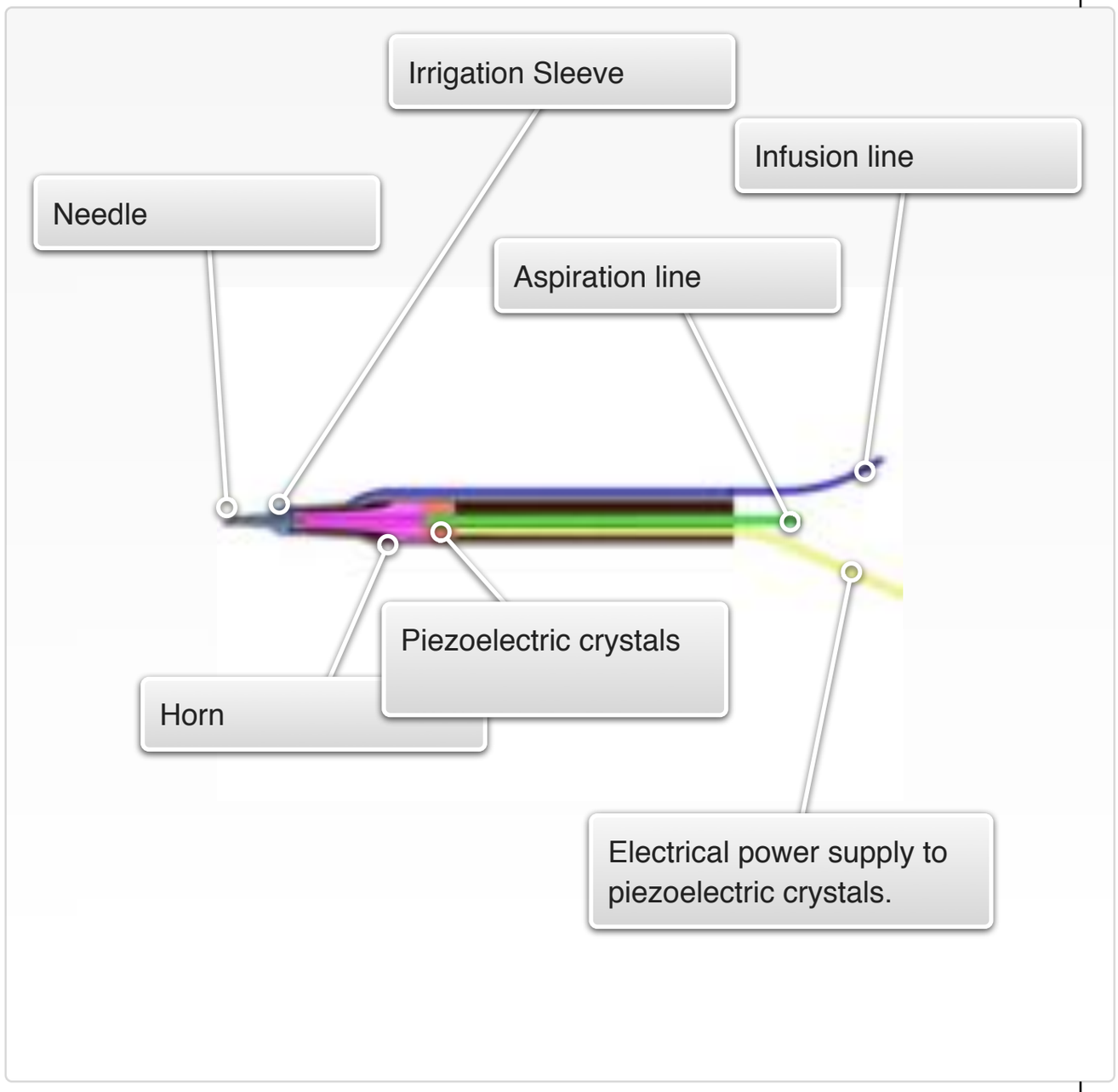

Infusion - aspiration mismatch

The infusion port in the sleeve is a little way from the aspiration port at the tip. Ideally, the irrigation ports are placed in the horizontal plane with respect to the bevel-up tip to ensure the irrigating fluid travels across the AC not up to the endothelium. If the phacoemulsification probe is partially withdrawn from the eye the infusion ports may lie within the incision. If aspiration is then activated (or if there is leakage due to the presence of an instrument in a side port) the anterior chamber will collapse.

This problem is exacerbated if the sleeve is moved further back up the tip. There are times when this may be necessary (for example while dealing with infusion-deviation syndrome or chopping). Under these circumstances great care must then be taken to keep the infusion ports within the anterior chamber.

Illustration 1.1 Infusion ports outside the anterior chamber.

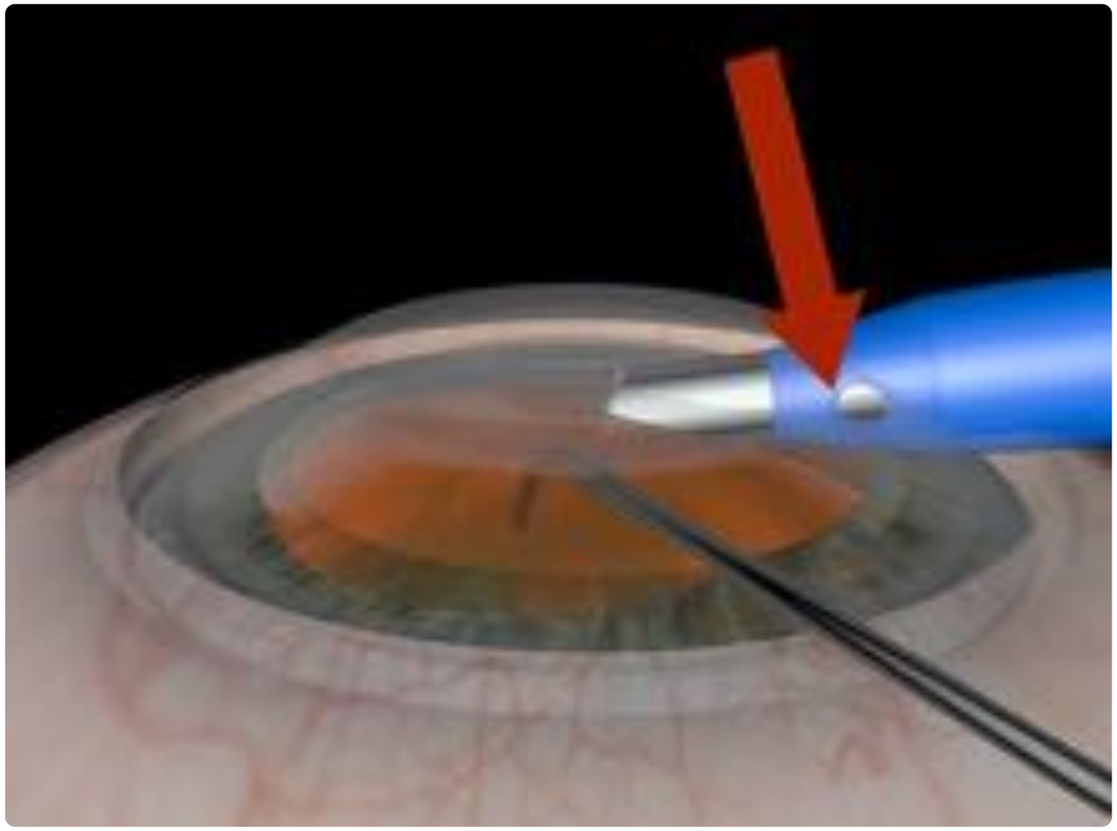

The infusion sleeve has been partially withdrawn for chopping. As the phacoemulsification probe is withdrawn the infusion ports lie within the incision (i.e. outside the anterior chamber). There is no infusion into the anterior chamber, which has consequently collapsed.

The foot-pedal

Many aspects of a phacoemulsification machines' performance are set on the console. Some can be controlled with the foot pedal.

Foot-pedals vary somewhat in design and complexity and may be individually configured.

A basic foot-pedal has 4 position depending on the degree of depression:

- Position 0 (undepressed) - no infusion, aspiration or fragmentation.
- Position 1 - infusion only.
- Position 2 - infusion + aspiration.
- Position 3 - infusion + aspiration + ultrasound.

The aspiration function can be either linear (variable - controlled by the foot pedal) or panel (fixed - changed by altering the settings on the console).

Most machines give some form of audible feedback to help the surgeon determine which position the footswitch is in.

Gallery 1.1 Foot pedal positions

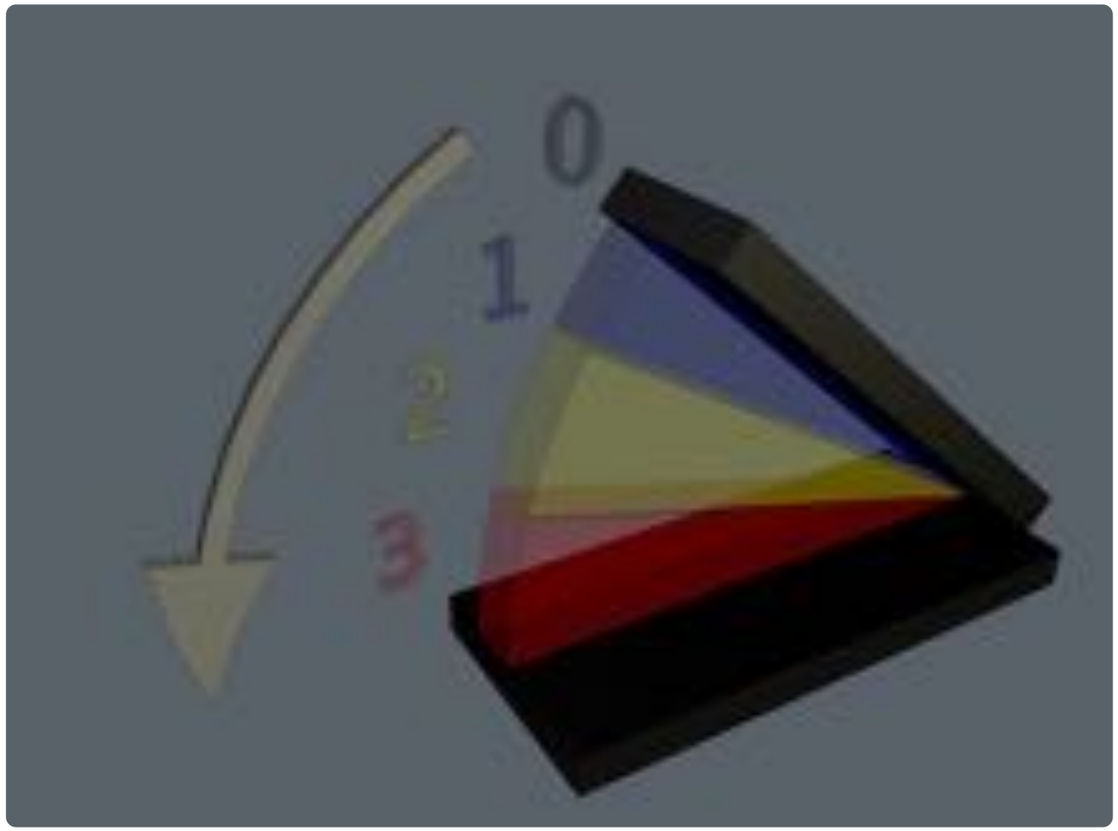

0 - no infusion

1 - infusion only

2 - infusion + aspiration

3 - infusion + aspiration + phacoemulsification

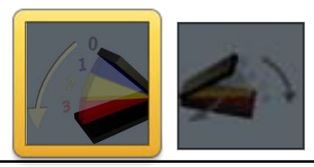

Pitch control

Conventional foot pedals move in a sequential up and down movement (Pitch). On most phaco machines depressing the foot pedal will first engage irrigation into the eye followed then by a gradually increasing aspiration level. By the time the foot pedal is depressed into the third pitch position, to control ultrasound, the aspiration rate has achieved its maximum preset rate. It remains fixed at this maximum level whilst ultrasound is being delivered.

Illustration 1.2 Pitch control

Yaw control

Dual linear foot pedals provide surgeons with a rapid response to all eventualities during surgery owing to the simultaneous, but independent, linear control of fluidics and phaco power in the two planes of foot pedal movement. This design offers enhanced control sensitivity because of the increased range of travel for aspiration and

Aspiration on yaw

In this setting, the pitch movement of the pedal is set up conventionally with irrigation and then aspiration gradually building to a preset level as you move into ultrasound delivery. This maximum setting is usually lower than would be set on a conventional pedal. If more aspiration is required, whilst aspirating or delivering ultra-

Ultrasound on yaw

In this setting, rather than the usual three positions in the pitch movement there are only two positions, irrigation and irrigation with linear aspiration.

Access to linear ultrasound is achieved via the yaw movement of the foot pedal. This setup carries the benefit of

Illustration 1.3 Yaw control

Illustration 1.4 Types of yaw control

Aspiration on yaw

Infusion

The infusion may be:

- Gravity driven, using an infusion bag or bottle which can be elevated or lowered to control the infusion pressure.
- Air driven, using a compressed air line feed into a rigid bottle. The infusion pressure is controlled by the pressure in the air line.
- Mechanical, using plates which squeeze a compressible infu-

Movie 1.1 The path of infusion fluid



Infusion fluid passes from lateral openings in the infusion sleeve, circulates in the anterior chamber and is removed via the aspiration port on the tip of the probe.

Gallery 1.2 Infusion systems

A gravity fed infusion system. Adjusting the bottle height alters the infusion pressure.

Infusion and intraocular pressure (IOP).

If aspiration rate exceeds infusion rate the anterior chamber collapses. This is always undesirable as as it may damage the endothelium and/or the posterior capsule.

- In foot position 0 a pinch valve squeezes the infusion line. There is no flow.
- In foot position 1 the pinch valve opens but while the tip of the phacoemulsification probe is in the anterior chamber there is still no flow.*
- In foot position 2 there is active aspiration so flow starts.



Foot position 0 :

The height of the infusion bottle has no influence on the IOP.

Foot position 1:

There is a pressure gradient between the infusion and the eye.

Foot position 2:

As well as the pressure gradient, the resistance to fluid flow through the tubing must be considered. The laws of hydrostatics ("still

Avoiding infusion aspiration mismatch:

Some modern machines control the IOP by continuously measuring the flow rate. These data, along with the infusion pressure, are

** Assuming a closed system - i.e. no leakage from the incisions.*

Aspiration

Aspiration pumps are of 2 types:

- Flow based, such as peristaltic pumps.
- Pressure based, such as Venturi systems.

There are significant differences in the behavior of these machines, particularly during and immediately after occlusion of the tip of the probe.

Some machines have both systems installed. The performance of pumps of both types may be modified to overcome some of their shortcomings. Understanding the principles of their operation makes the competing claims of rival manufacturers intelligible.

Figure 1.1 Key to demonstration of fluidics parameters in this book

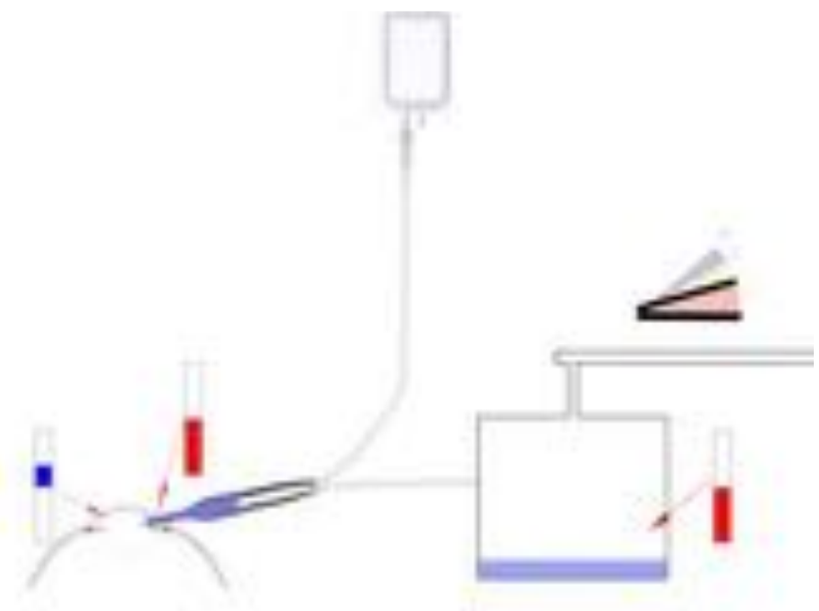

There are two pressure displays - one in the anterior chamber showing an above atmospheric (blue) pressure and one just inside the tip of the phaco probe demonstrating a vacuum (red).

Basic peristaltic pumps

Peristaltic pumps generate flow through the rotation of a set of rollers which squeeze the infusion line, milking fluid along it. The faster the rollers rotate, the greater the flow rate (known as aspiration rate - usually measured in mls/min).

Movie 1.2 Peristaltic pump

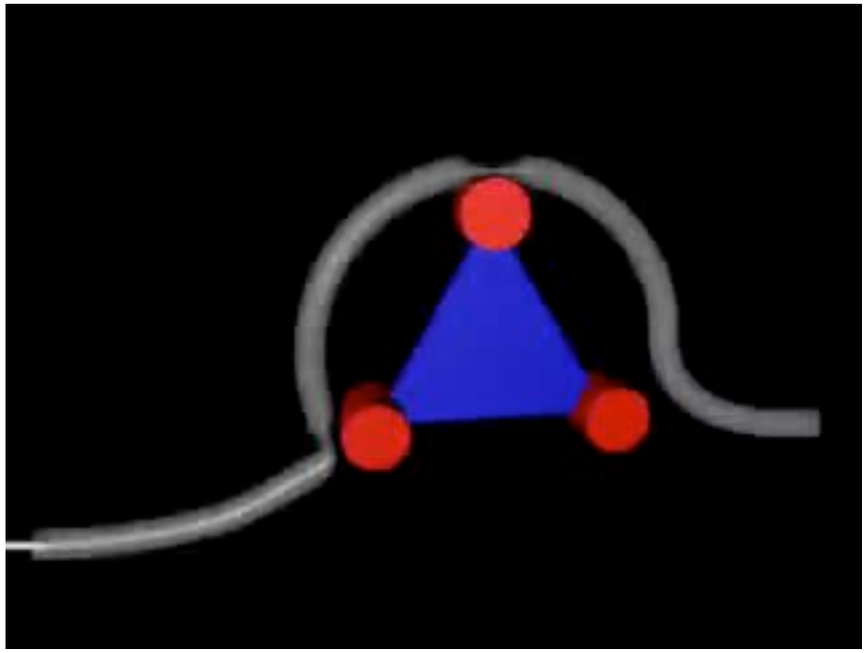

In a peristaltic pump fluid is milked along a tube with rollers.

Movie 1.3 Peristaltic pump in flow mode



Foot pedal depression affects the flow rate.

Flow and vacuum mode in peristaltic pumps

In peristaltic pumps 2 variables may be controlled: the flow rate and the maximum vacuum at which the rollers stop rotating. When using a conventional foot pedal only one of these variables can be controlled at a time using the foot pedal ('surgeon controlled') while the other is adjusted by changing the settings on the machine console ('panel controlled').

When the flow rate is controlled by the foot pedal the machine is said to be in linear flow mode. When the vacuum limit is controlled by the foot pedal the machine is said to be in linear vacuum mode.

In practice linear vacuum mode is most commonly employed for

Movie 1.4 Peristaltic pump in vacuum mode.

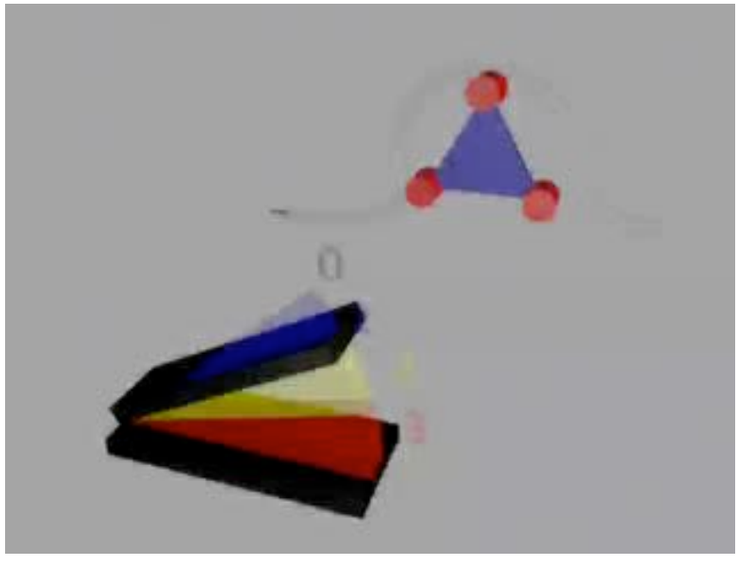

Note that the rotational velocity of the rollers does not change as the foot pedal is depressed.

Occlusion in a peristaltic system

Changes in pressure in the tubing of a peristaltic pump occur in the presence of fluidic resistance. This is fixed and quite low when the aspiration port is open. Significant vacuum therefore only develops in practice if the port is occluded, for example by a piece of lens material.

This vacuum is clinically useful for holding pieces of lens material.

The perception that Venturi systems are easier to control but less efficient is historical and is not relevant to modern machines.

Movie 1.5 Occlusion in a peristaltic system

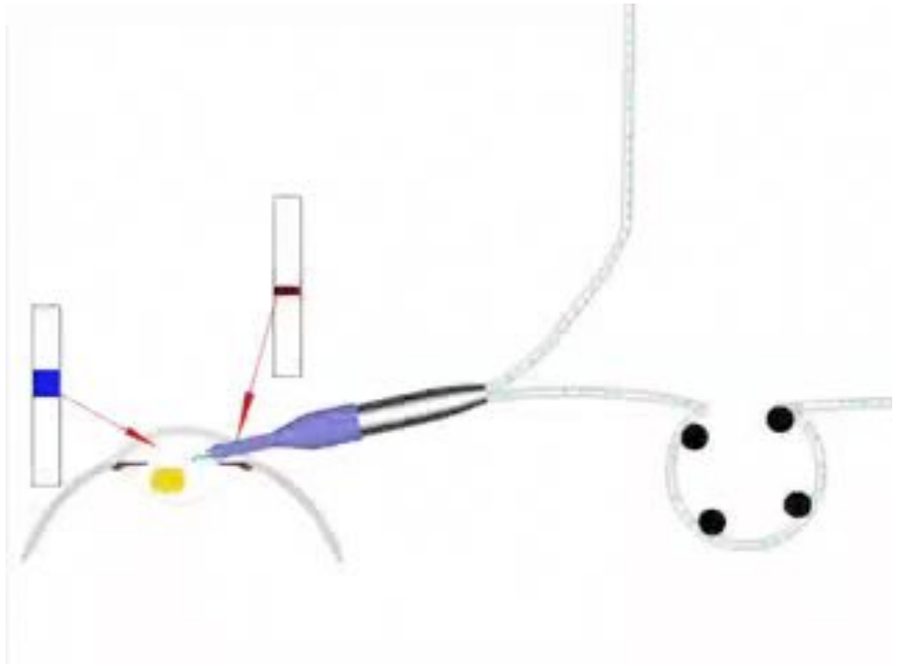

Note that following occlusion flow stops, a vacuum develops (red = sub-atmospheric pressure) in the tip of the phaco handpiece and the intraocular pressure rises to the level dictated by the infusion system (as described in the infusion section of this chapter).

Rise Time in a peristaltic system

If the tubing in a flow pump was totally rigid the creation of vacuum after occlusion would be instantaneous. This does not happen because peristaltic pumps require compliant tubes which can be squeezed by the rollers. Vacuum develops after occlusion as fluid is pumped out of the occluded aspiration line, which partially collapses.

The rate at which vacuum builds up is called the rise time.

As the rate of flow increases the vacuum builds up more quickly - the rise time falls.

Movie 1.6 High flow rate

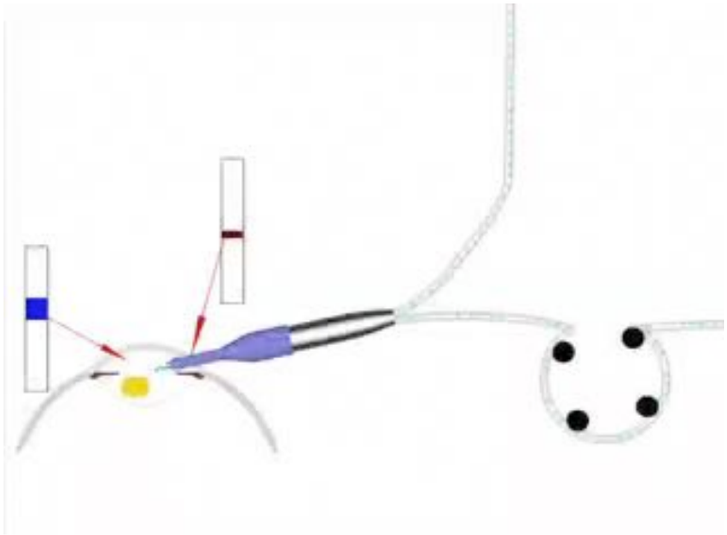

The rollers are moving quickly so the rise time is short. As there is no outflow from the anterior chamber the IOP rises.

Movie 1.7 Low flow rate

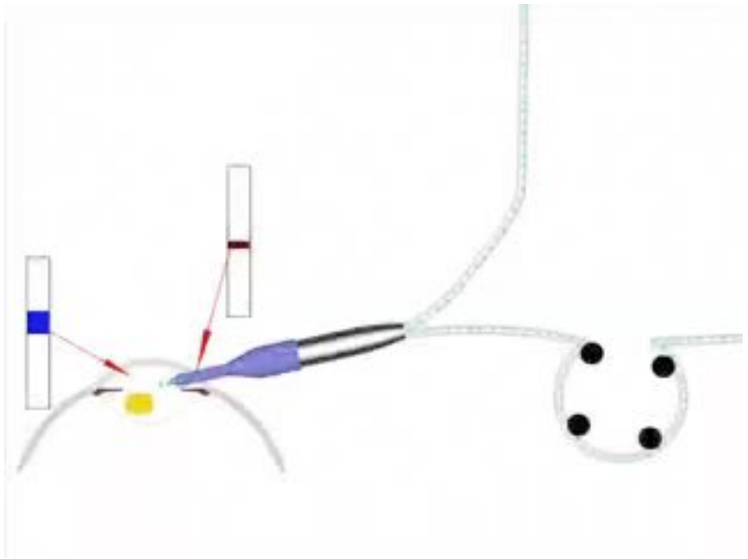

The rollers are moving slowly so the rise time is long.

Use of the vacuum limit in a peristaltic system

Depression of the footswitch within position 2 to increase the vacuum limit is particularly useful during the quadrant removal stage of the operation. Depression of the footswitch increases the holding power ('holdability') of the probe, allowing nuclear fragments to be moved in the eye.

Movie 1.8 Insufficient vacuum

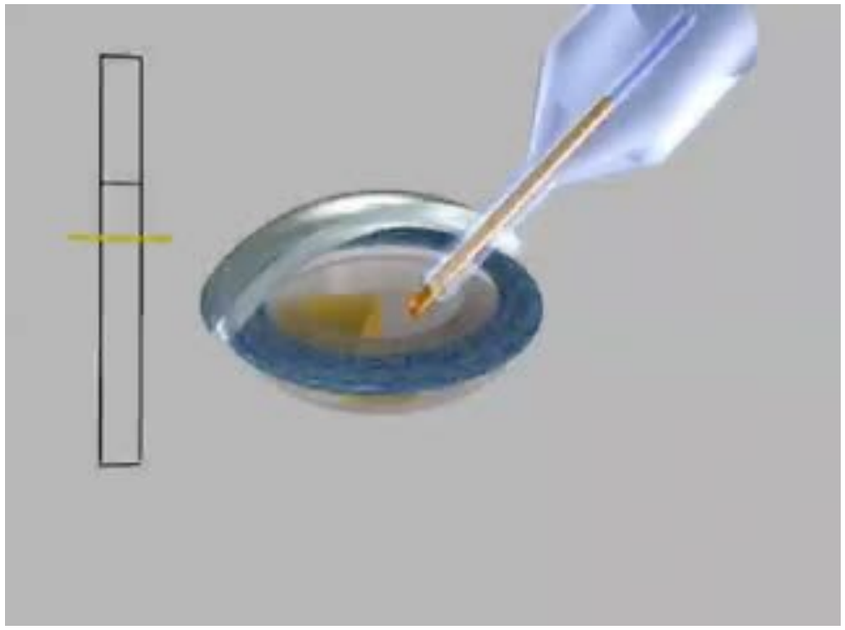

Occlusion has occurred. The footpedal is 25% of the way through position 2. Some vacuum has been generated. However the foot pedal has not been depressed enough to generate sufficient vacuum to hold the nuclear fragment.

Movie 1.9 Correct use of vacuum

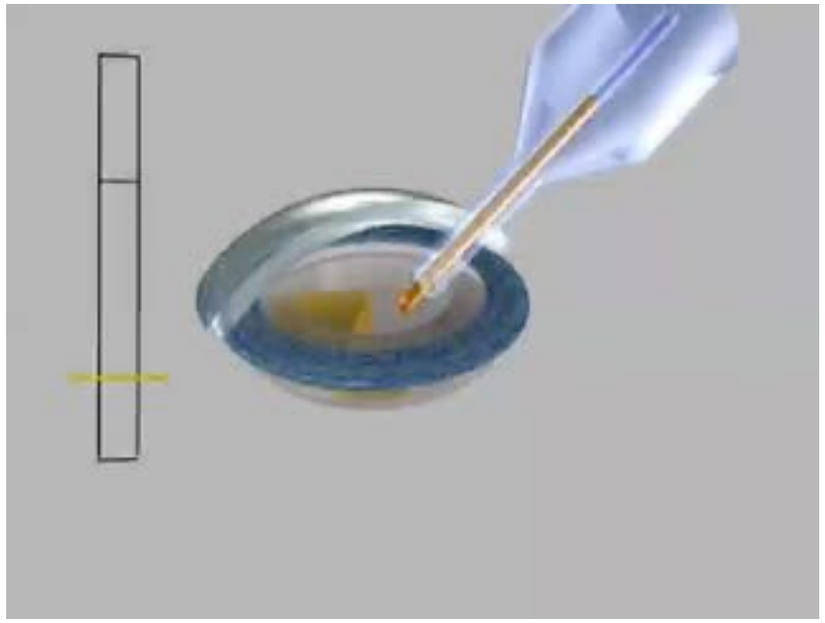

The foot pedal has been depressed further (to 75% of the way through position 2). The higher vacuum generated is sufficient to hold the nuclear fragment and move it.

Post occlusion surge in a peristaltic system

The tubes within peristaltic pumps are compressible, or compliant.

In the presence of vacuum (i.e. During occlusion) they partially collapse. Once occlusion ceases the collapsed parts of the infusion line spring open very quickly. This results in a surge of fluid into the aspiration line. If this exceeds the maximum infusion capacity the anterior chamber collapses and the capsular bag or iris may be drawn into the phaco tip (post occlusion surge).

The amount of compliant tubing is minimized to reduce post-occlusion surge. Other design features to reduce surge are discussed later in this chapter. Modern tubing is much more non-compliant reducing the risk of post-occlusion surge which potentially makes the vacuum rise time more rapid.

Movie 1.10 Infusion line collapse

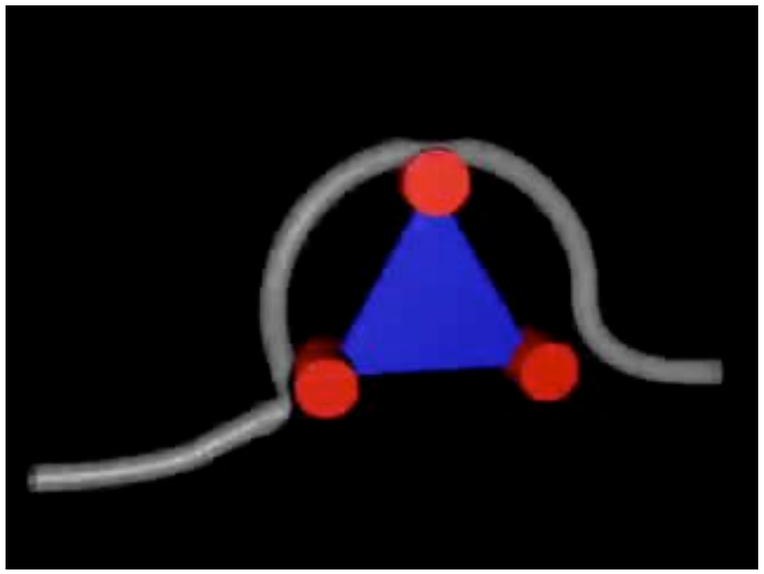

As the pump squeezes the dregs of fluid out of the occluded aspiration line its walls collapse. The elastic energy stored in the collapsed walls is the basis of post occlusion surge as they spring open when the line is no longer occluded.

Movie 1.11 Post occlusion surge

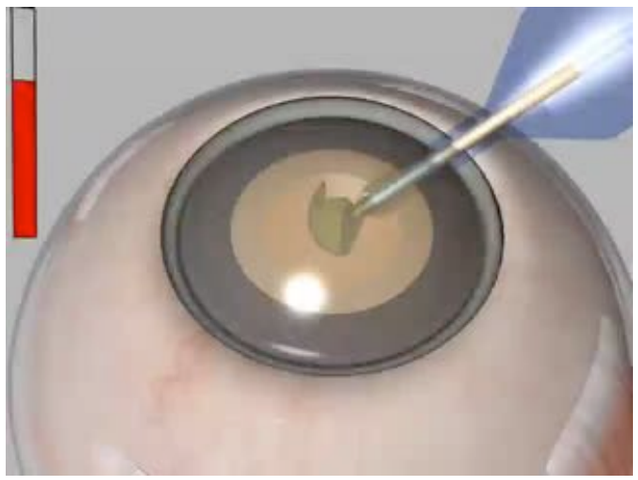

The anterior chamber collapses and there is a risk of trauma to the capsular bag.

Movie 1.12 Surge and posterior capsule tear

Note the radial posterior capsular 'star' folds as the capsule is breached.

Air in the aspiration line and post occlusion surge

The presence of air in the aspiration line increases the risk of post occlusion surge.

When the phacoemulsification equipment pack is opened all the lines are full of air. The handpiece is primed with saline by placing its tip in a sealed test chamber containing saline and no air. The infusion and aspiration are allowed to run until no air is left in the lines.

Case study:

A 0.1 ml bubble of air is accidentally entrained in the aspiration line. This can easily happen as the handpiece is moved around: flexion of the tube squeezes a few drops of water out. When the tube is

Movie 1.13 Effect of air bubbles in the aspiration line

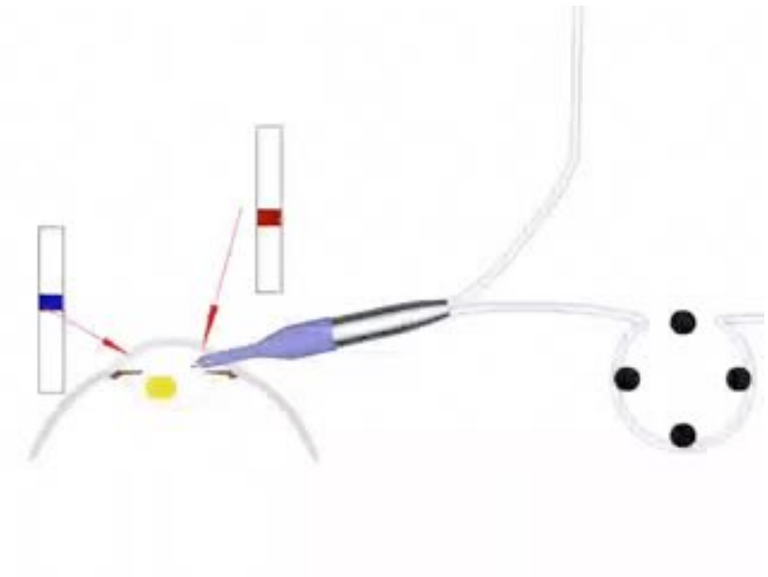

During occlusion the vacuum in the aspiration line increases and the bubbles expand. When the occlusion is broken the vacuum falls and the bubbles contract to their original volume, drawing fluid out of the anterior chamber. This causes it to collapse. The pump shown here carries on rotating after occlusion - in reality most pumps stop as soon as a preset vacuum is reached.

Notification of occlusion in a peristaltic system

Peristaltic phaco machines have pressure transducers which detect the build up of vacuum in the aspiration line.

When vacuum develops the machine gives an audible clue (such as a repeated ping) to indicate to the surgeon that occlusion is present.

Movie 1.14 Sounds during phacoemulsification

Four different types of sound are heard. The pulse of the ECG can be heard throughout. The pitch of the high pitched whining indicates the degree of vacuum (indicated by the blue vacuum indicator bar). When occlusion occurs a repeated chiming is heard (and an orange indicator bar lights up on the panel). When ultrasound is present a hissing noise is heard (and the level in the green power indicator bar rises above zero).

Venting in a peristaltic system

Very high vacuums are undesirable because of the very large post occlusion surge that could develop. A pressure limit is therefore set at which fluid or air from a reservoir can be introduced into the aspiration line (venting). This immediately reduces the vacuum.

Venting also occurs when the footpedal is moved from position 2 to position 1 or 0. This allows aspiration to be discontinued quickly (for example if iris or capsule become engaged in the tip of the probe).

Interactive 1.3 The venting system

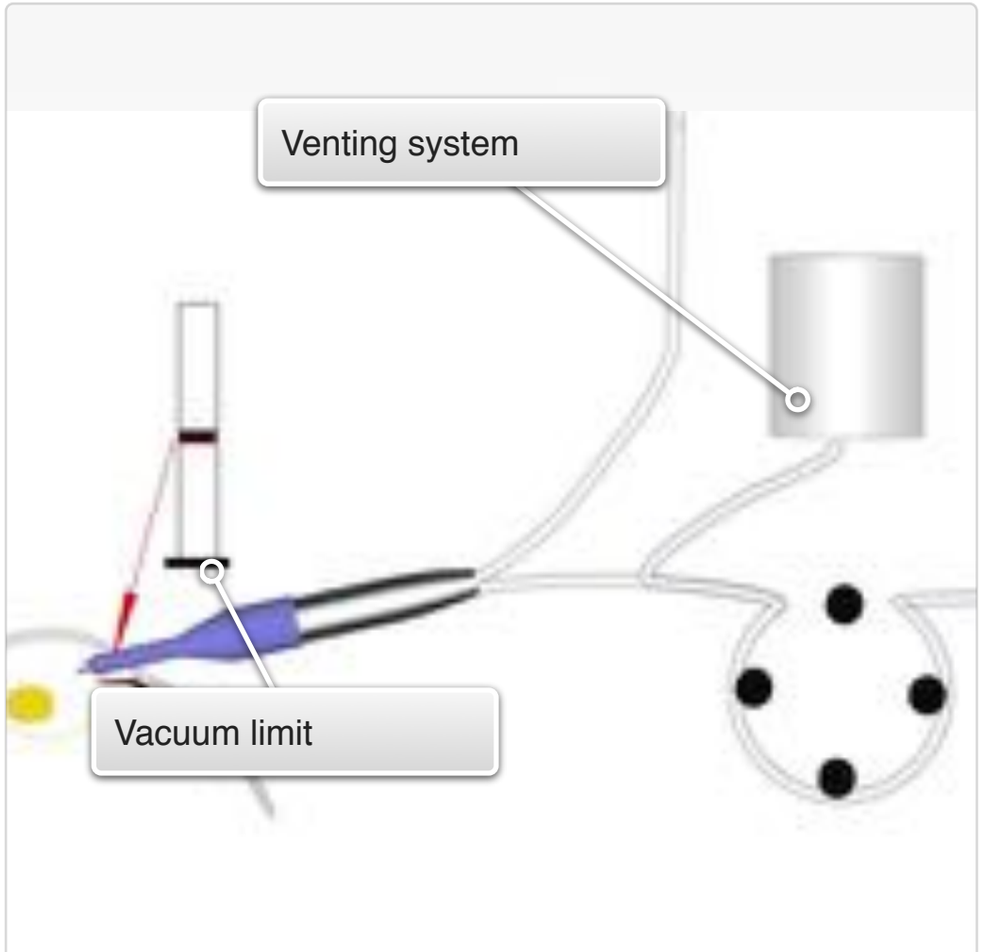

Movie 1.15 Venting

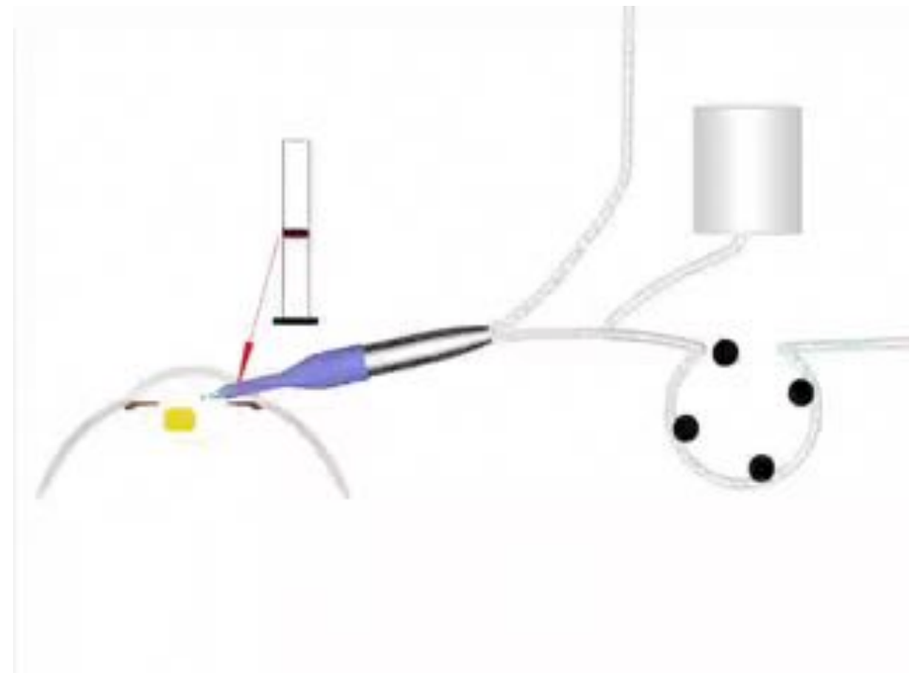

Occlusion causes an increase in vacuum. When the preset limit is reached fluid is released into the aspiration line from the fluid reservoir. This causes the vacuum to fall.

Basic Venturi Pumps

Venturi pumps have no moving parts and operate on the Venturi principle.

Movie 1.16 The Venturi principle.

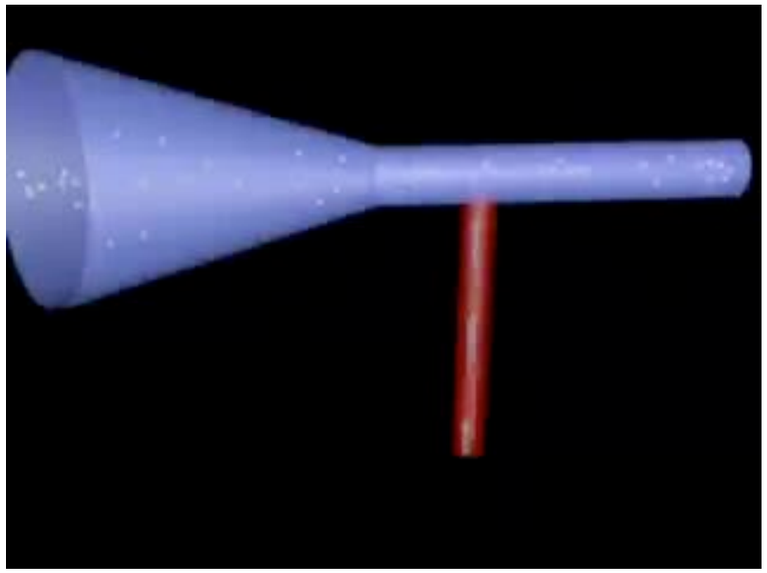

The Venturi pump is an application of the Bernoulli principle. The gas particles in the blue tube accelerate when they move into the narrow section and the pressure drops. This is used to draw gas or fluid up the red tube. Note that the vacuum is the controlled variable and the flow changes are a secondary consequence.

Movie 1.17 The Venturi pump in phacoemulsification

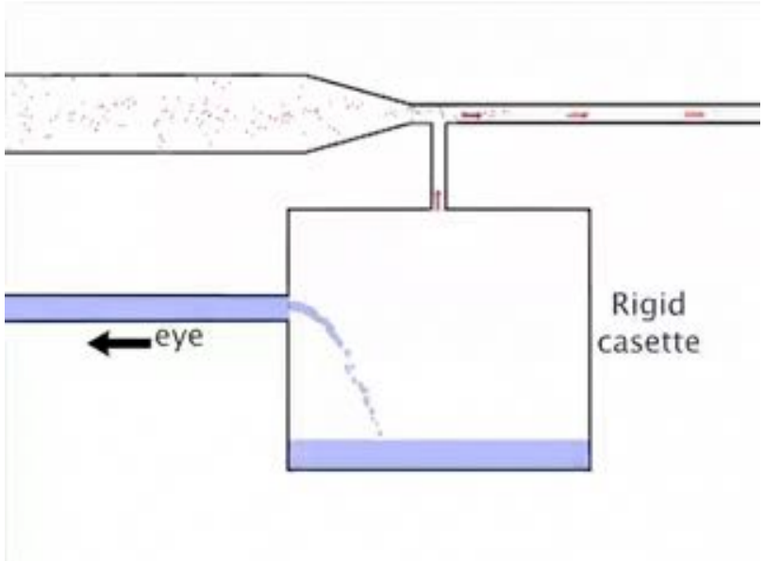

The Venturi system draws air out of a rigid cassette. This generates vacuum inside the cassette. This draws fluid along the aspiration line from the eye which gathers in the cassette.

Flow and vacuum in a Venturi system

In a Venturi pump the vacuum is changed by altering the pressure in the high pressure air line which generates the Venturi effect. The higher the pressure in this line, the greater the vacuum in the cassette chamber. Changes in flow occur as a secondary consequence and depend on the fluidic resistance of the system. Flow is controlled indirectly by damping the vacuum.

Figure 1.2 Control of vacuum in a Venturi system

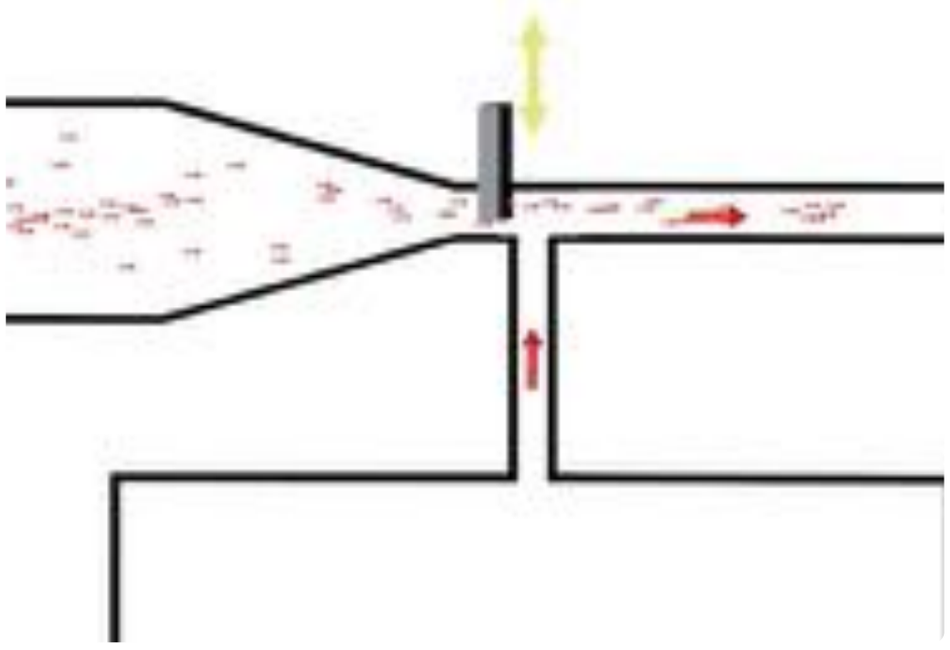

The vacuum may be altered by partially occluding the high pressure air line. Complete occlusion stops all flow.

Movie 1.18 Vacuum and flow in a Venturi pump.

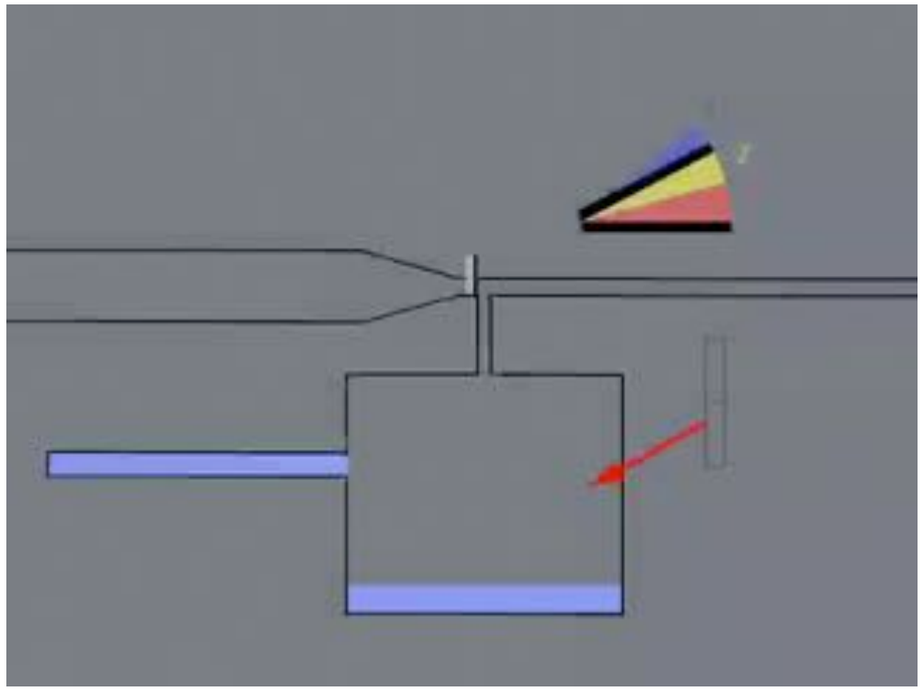

Depressing the foot pedal increases the vacuum in the rigid cassette, which increases flow. The flow changes follow the change in pressure and cannot be controlled independently.

Vacuum and occlusion in a Venturi system

Venturi pumps tend to have a shorter rise time than peristaltic pumps. They also have some vacuum at the tip of the phacoemulsification probe even in the absence of occlusion (unlike peristaltic pumps).

When the pump is operating with an unoccluded port there is a drop in vacuum between the port and the aspiration cassette due to resistance to flow in the tubing (Poisseuille's Law).

Once occlusion develops the changes in vacuum at the aspiration port occur very quickly. This is a consequence of Pascal's Law. This is in contrast to peristaltic pumps where the generation of vacuum is damped by partial collapse of compliant segments of tubing, which takes time and depends on the flow rate of the peristaltic pump and the rigidity of the tubing.

The perception that Venturi systems are more efficient but sometimes more difficult to control is historical and is not relevant to modern machines.

Movie 1.19 Vacuum, occlusion and rise time in a Venturi system

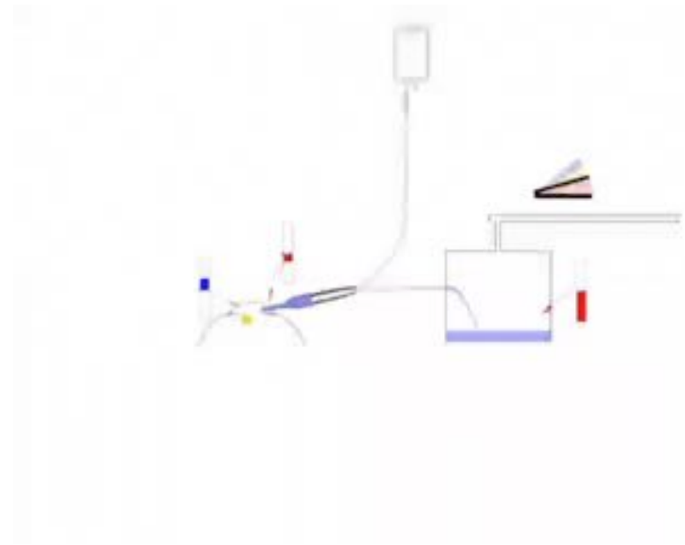

At the start of this video the pump is operating without occlusion and the vacuum is lower just inside the probe tip than in the aspiration cassette. Once the lens fragment occludes the port the vacuum rises very quickly to the level of vacuum in the aspiration cassette.

.

Followability in a Venturi system

The infusion generates fluid currents within in the anterior chamber. These may be used to draw mobile pieces of lens material to the port of the handpiece. Whilst in a peristaltic system depression of the foot pedal in vacuum mode has no effect of flow, in a Venturi system it increases the speed of these currents. Thus in a Venturi system depression of the footpedal may be used to draw lens material to the port (i.e.increase followabilty).

Movie 1.20 Foot pedal depression in a Venturi system

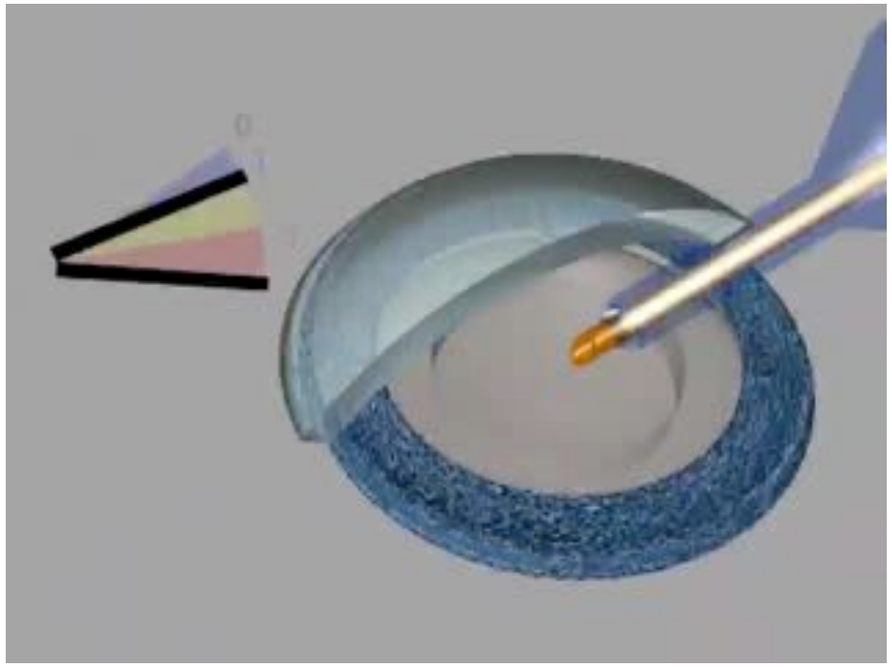

Foot pedal depression within position 2 increases vacuum and therefore flow and therefore the velocity of the currents in the anterior chamber. This does not occur with peristaltic pumps when used in vacuum mode, as they often are.

Movie 1.21 Use of fluid currents

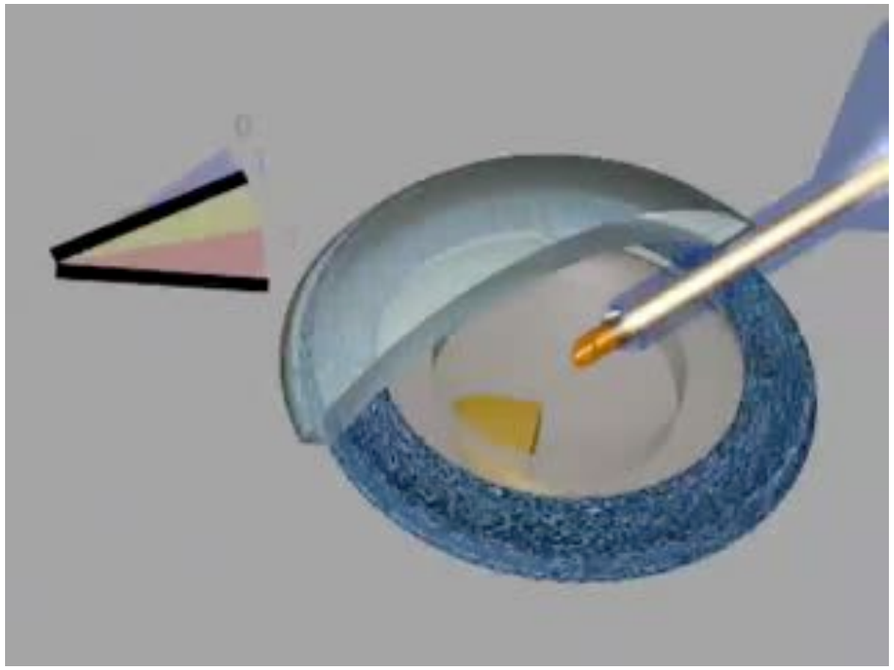

The increasing currents as the foot pedal is depressed may be used to draw mobile lens material to the aspiration port. Note how the streams of fluid converge as they approach the aspiration port. The ability to attract mobile lens material is greatest near the port.

Post occlusion surge in a Venturi system

A surge in flow may develop after occlusion break in Venturi systems as with peristaltic systems, albeit for slightly different reasons from a peristaltic system.

During phacoemulsification vacuum is increased (by the surgeon, using the foot pedal) to hold the mobile nuclear fragment on the tip of the needle. If this high vacuum is maintained after the nuclear fragment is cleared there is a surge of fluid through the aspiration line. If this exceeds the infusion flow into the anterior chamber it collapses. Modern machines are able to detect and respond very quickly to sud-

Movie 1.22 Post occlusion surge

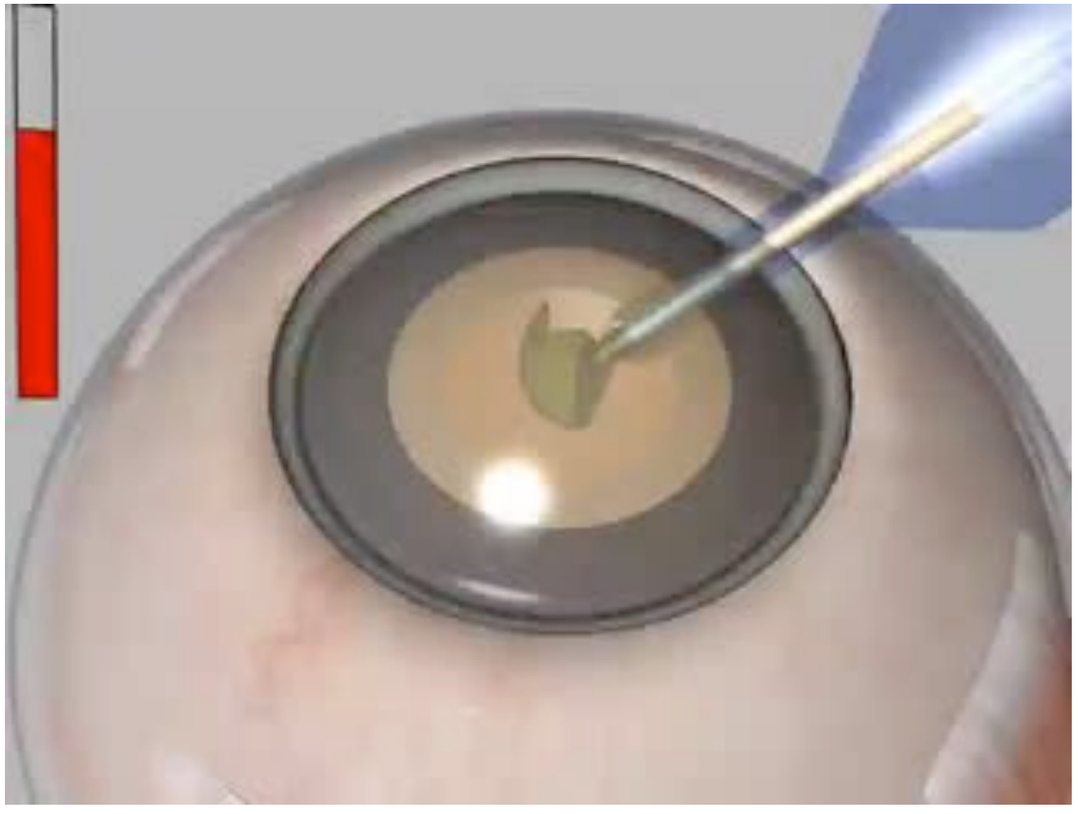

If a very high vacuum is maintained after occlusion break, the anterior chamber collapses.

Movie 1.23 Prevention of post occlusion surge

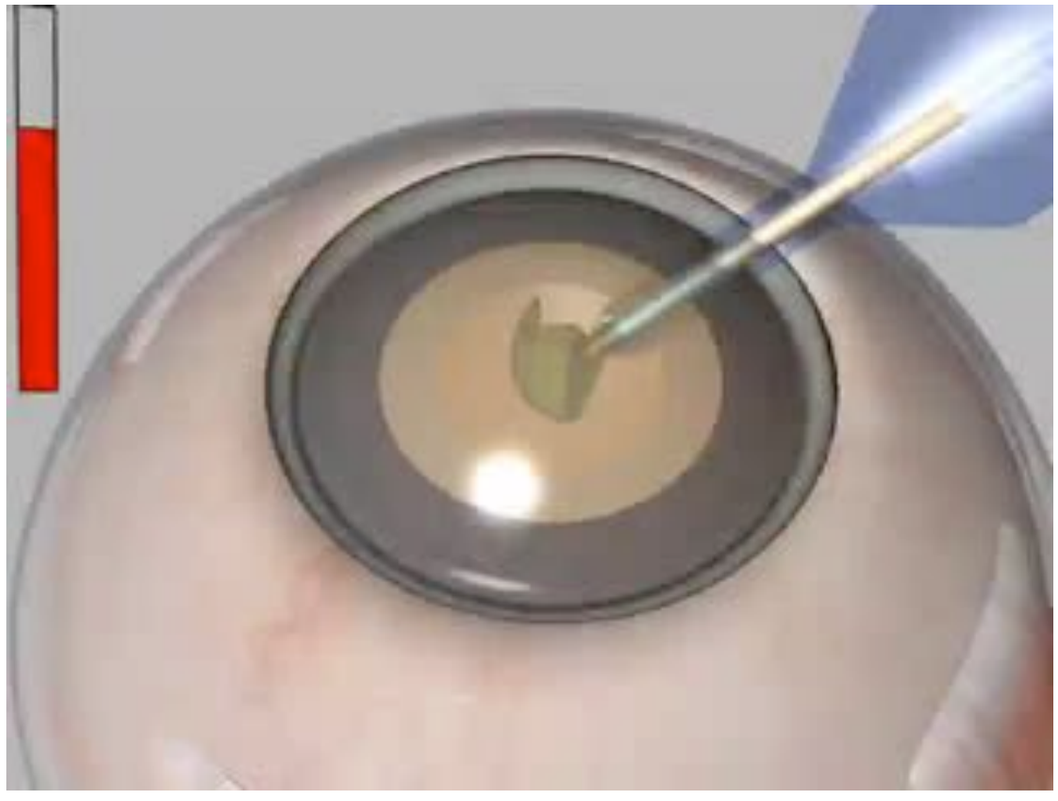

The vacuum is progressively reduced in anticipation of a post occlusion surge and the infusion pressure has been elevated. The anterior chamber does not collapse.

Basic peristaltic and Venturi pumps in clinical practice

Modern phacoemulsification machines of both types use major design modifications, in particular microprocessor control, which alter their behavior. These have improved the performance of both peristaltic and Venturi pumps. There is currently no consensus on which system is more effective. Both systems have very eminent and vocal advocates. This chapter compares basic Venturi and peristaltic pumps.

Peristaltic and Venturi pumps

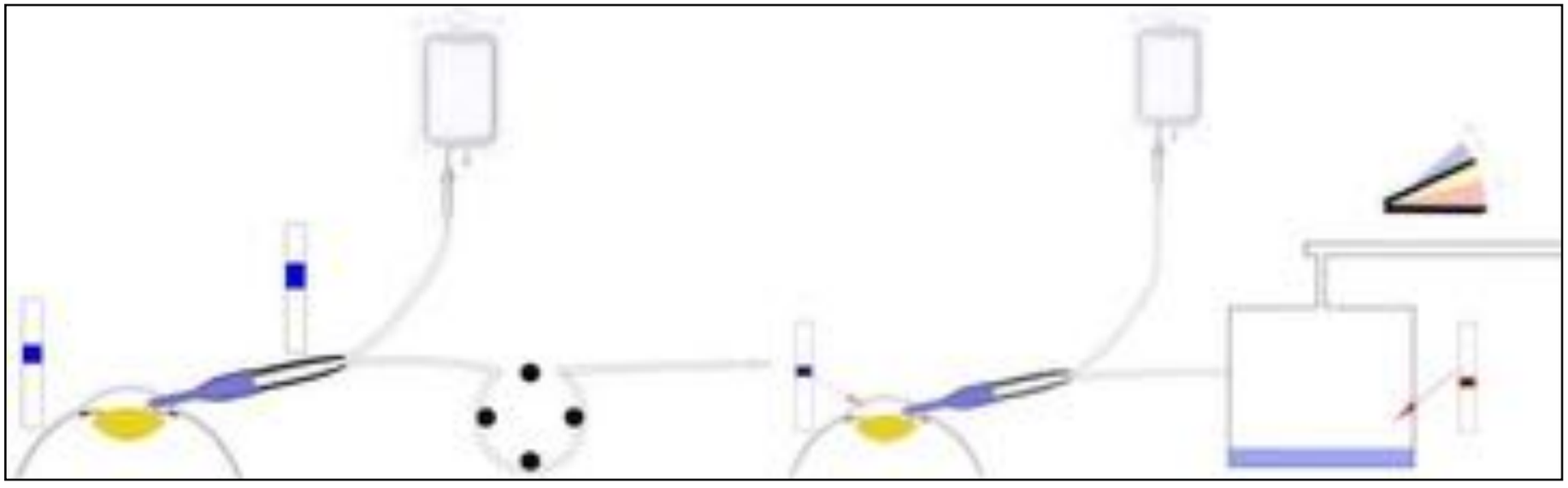

Infusion pressure and flow

In a Venturi system there is no physical barrier between the infusion and the pump. The infusion pressure therefore affects flow. The higher the infusion pressure the higher the flow - irrespective of the vacuum generated by the pump. The infusion pressure contributes to the pressure drop between the bottle and the pump which determines flow.

In a peristaltic system the infusion pressure has no effect at all on flow, which is solely dependent on the speed at which the rollers rotate. The fluid in the aspiration line cannot circumvent the rollers. Even if the infusion pressure is very high indeed the flow will be very slow if the rollers are moving very slowly. The slow velocity of the rollers would then actually be impeding flow through the pump, which would be much higher if the rollers were not present.

Movie 1.24 Infusion pressure is a peristaltic system

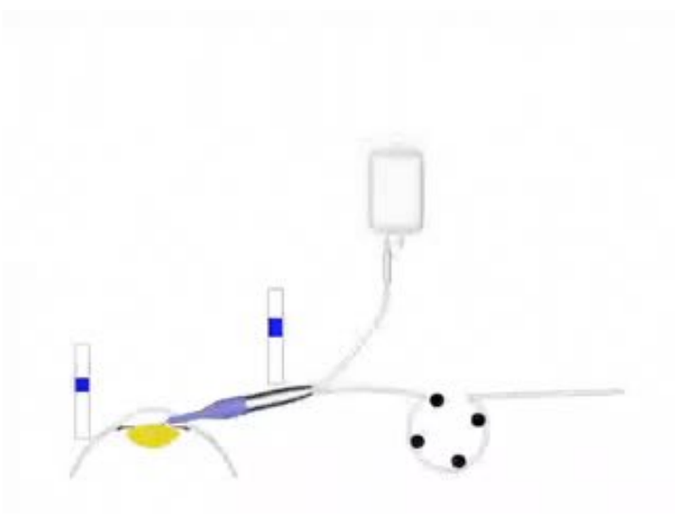

Elevation of the infusion pressure has no effect on flow. The rollers prevent an increase in flow and the IOP increases significantly.

Movie 1.25 Infusion pressure in a Venturi system

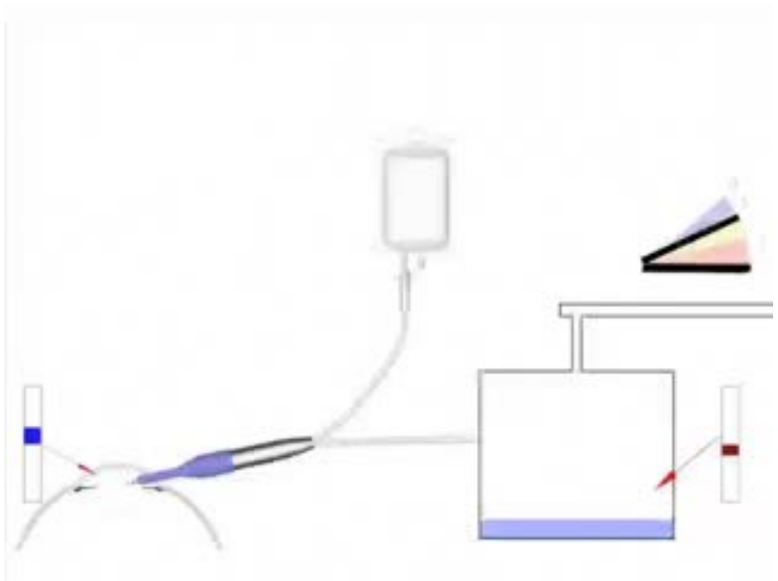

Elevation of the infusion bottle increases flow.

Rise time

The rise time of Venturi systems is shorter than peristaltic systems. Because of the delay in development of vacuum some time must be allowed after tip occlusion before there is sufficient holding power to apply traction to lens fragments when using a peristaltic system.

Followability

The term "followability" refers to the ease with which nuclear fragments are attracted to the aspiration port of the phaco tip. Flow in an unmodified peristaltic system (in vacuum mode) does not change when depressing the footswitch so depressing the footswitch will not draw fragments towards the tip. In Venturi systems the vacuum, and therefore flow, can be continually adjusted using the footswitch to alter flow. This makes it easier to draw mobile lens fragments to the tip of the probe.

Flow control

Because flow is dependent on vacuum in a Venturi system, flow can only be modified (independent of vacuum) by automatic vacuum dampening. In a peristaltic system it is possible to combine a high vacuum limit (the level at which the rollers stop moving) with a low flow rate (by adjusting the aspiration flow rate setting on the console) and vice versa. This may make surgery safer, especially in the learning curve.

Post occlusion surge

Post occlusion surge is generally greater in peristaltic systems due to the greater compliance of the tubing (since the peristaltic effect requires compliant tubing).

Modern machines - an important disclaimer

Many of the above statements are less relevant than used to be the case as sophisticated algorithms within the machines modify their performance.

Emulsification

Figure 1.3 The piezoelectric crystals, horn and needle.



Ultrasound energy is used to fragment solid pieces of lens matter, allowing their aspiration.

It is generated in piezoelectric crystals (red in the above schematic). It is conveyed by the horn (purple), whose funnel shape amplifies the amplitude, to the metallic tip at the end. This is used to fragment sold pieces of lens matter, allowing their aspiration.

The piezoelectric phenomenon

Piezoelectric materials change size as a result of an electrical current.

The arrangement of piezoelectric components of phacoemulsification probes was illustrated earlier in this chapter.

Increasing the power of the current increases the degree of deformation of the crystal (and therefore the amplitude of vibration).

A single application of current will produce a single deformation of the crystal. Alternating current causes deformation (and therefore vibration) at the frequency of the applied current.

Movie 1.26 The piezoelectric effect

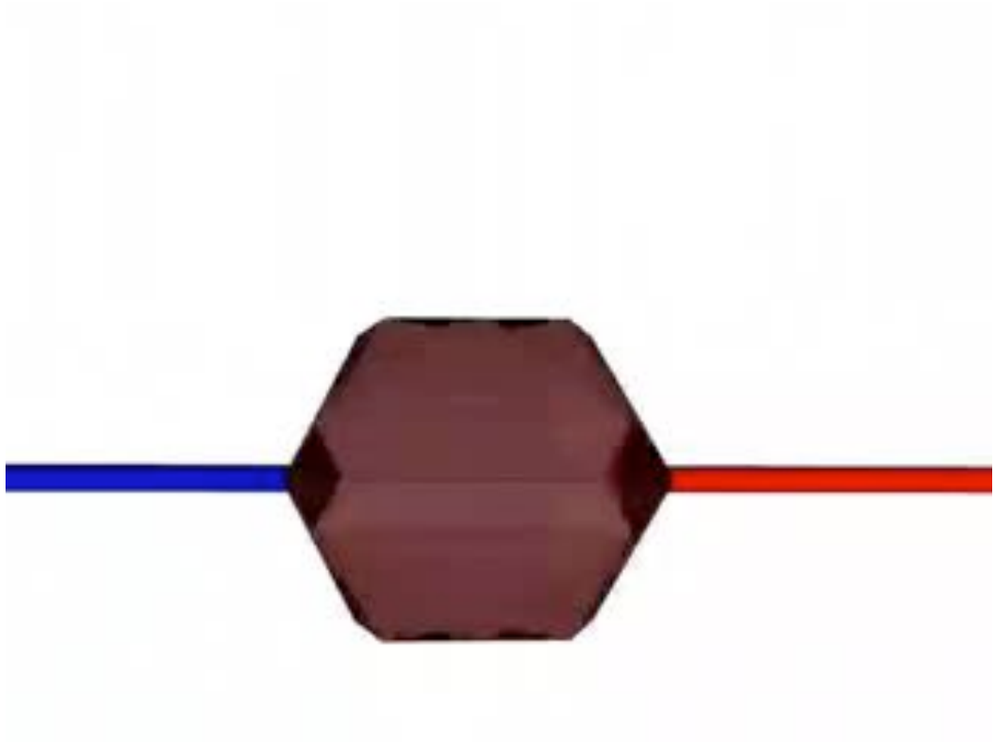

Note that the changes in size of this piezoelectric crystal are in phase with the changes in polarity of the alternating current. Although oscillation occurs with the frequency of the current, each material has an optimal frequency at which it operates most efficiently.

The needle

The arrangement of piezoelectric components of phacoemulsification probes and was illustrated earlier in this chapter.

Vibration of the piezoelectric crystals is transmitted to a detachable needle with a bevelled tip.

The degree of the bevel varies.

Conventional phacoemulsification uses a straight needle - the excursions of the tip are longitudinal.

A bent needle allows rotational oscillations of the needle tip ('torsional phacoemulsification").

Figure 1.4 Tip bevels

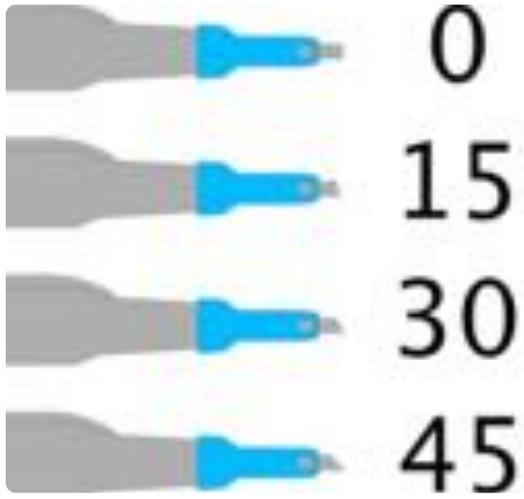

Various tip bevel angles are available. Occlusion is optimal with a blunter tip and sculpting with a more angled one. The widely used 30^0 tip represents a compromise between these considerations.

Movie 1.27 Longitudinal phacoemulsification

The movements of the probe tip are longitudinal (in and out).

Movie 1.28 Torsional phacoemulsification

When combined with a bent (Kelman) tip this allows rotational oscillation of the tip.

Movie 1.29 Elliptical phacoemulsification

A straight needle - the tip moves in an ellipse

Stroke length.

The distance the tip travels is termed its stroke length. The amplitude of the current supplied to the piezoelectric crystal increases its deformation and therefore the stroke length. The greater the stroke length the greater the ultrasound energy that is delivered to the lens.

Frequency

The frequency of the current supplied to the crystal determines the frequency of oscillation of the crystal (and therefore of the tip of the probe). The greater the frequency, the greater the energy delivered to the lens. This varies (from machine to machine) between 28.5 kHz and 40 kHz but is fixed on each machine.

Power

Power variability

An important consequence of the way power is calculated is that, because it is relative rather than absolute, it is impossible to make meaningful comparisons between machines when power is expressed as a percentage.

Movie 1.30 Stroke length



The excursion of the needle tip is the stroke length. The maximum stroke length is much smaller than shown here (approximately 0.1 mm).

The physics of lens emulsification

During sculpting the lens appears to emulsify just in front of the advancing probe tip. This is not actually the case. However it is a very helpful way of conceptualizing the process as it reinforces the importance of not moving the nucleus during sculpting.

Movie 1.31 Sculpting



The lens appears to emulsify just in front of the advancing probe tip.

The physics of lens emulsification (contd.).

Several mechanisms have been proposed as the physical basis for fragmentation of lens matter:

1. The Jackhammer effect. Direct contact of the tip of the phaco probe (which travels at speeds of up to 72 km/hour) overcomes the weak attractive intermolecular forces, fracturing the lens.

2. Cavitation. Tiny air bubbles are created during the backward stroke of tip movement, due to the sudden reduction in pressure. They initially grow over several stroke cycles before imploding creating a pressure wave.

Movie 1.34 The Jackhammer effect



Physical contact overcomes intermolecular forces to deform and then fracture a rigid body.

Movie 1.32 The jackhammer effect in phacoemulsification



Note the repulsive force which pushes the nuclear fragment away. The alternation of this with attraction to the tip by fluid currents is the basis of carouselling.

Movie 1.33 Cavitation

Micro-bubbles are created in the wake of the receding tip during the backstroke of the vibration cycle due to the reduction in pressure. These grow over several cycles and then implode, releasing energy.

Problems with ultrasound

1. The ultrasound generates thermal energy. This is dissipated by the infusion fluid. Interruption of the infusion may occur if ultrasound is activated while the tip is occluded or if the infusion sleeve is squeezed in a small incision. The thermal energy causes the probe tip to heat up which can cause a corneal wound burn - the edges of the corneal wound opacify and retract slightly. It may also damage the corneal endothelium.

2. With mobile lens fragments the repulsive jackhammer effect pushes the lens away, preventing emulsifi

Figure 1.5 Wound burn

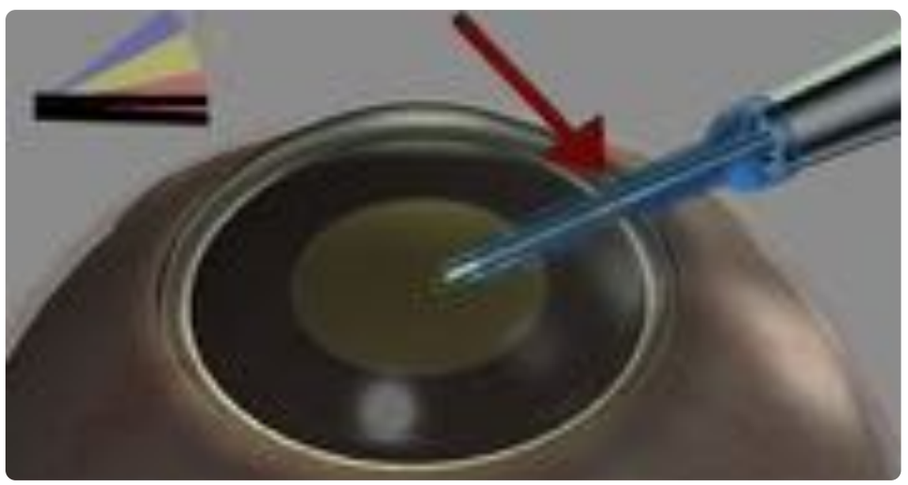

In this case the section is too small. This was due to use of an inappropriate keratome, designed for a narrower probe. The cataract is dense and requires high phaco power. The infusion sleeve is being squeezed in the cornea (red arrow) and this prevents delivery of enough fluid to cool the needle.

Movie 1.35 Chattering (carouselling)



Pulsed phacoemulsification is being used - the nuclear fragment is subject alternately to the attractive force of the infusion currents and the repulsive jackhammer effect. The size of these movements has been amplified (and their frequency reduced) for illustrative reasons. In practice large oscillations are undesirable because of possible trauma to the corneal endothelium.

Modulation of ultrasound.

- The corneal endothelium is very sensitive to increases in temperature.
- It is therefore desirable to minimize the energy delivered into the eye.
- There are a number of ways in which the ultrasound energy may be modulated to achieve this.

Figure 1.6 Modulation of ultrasound delivery

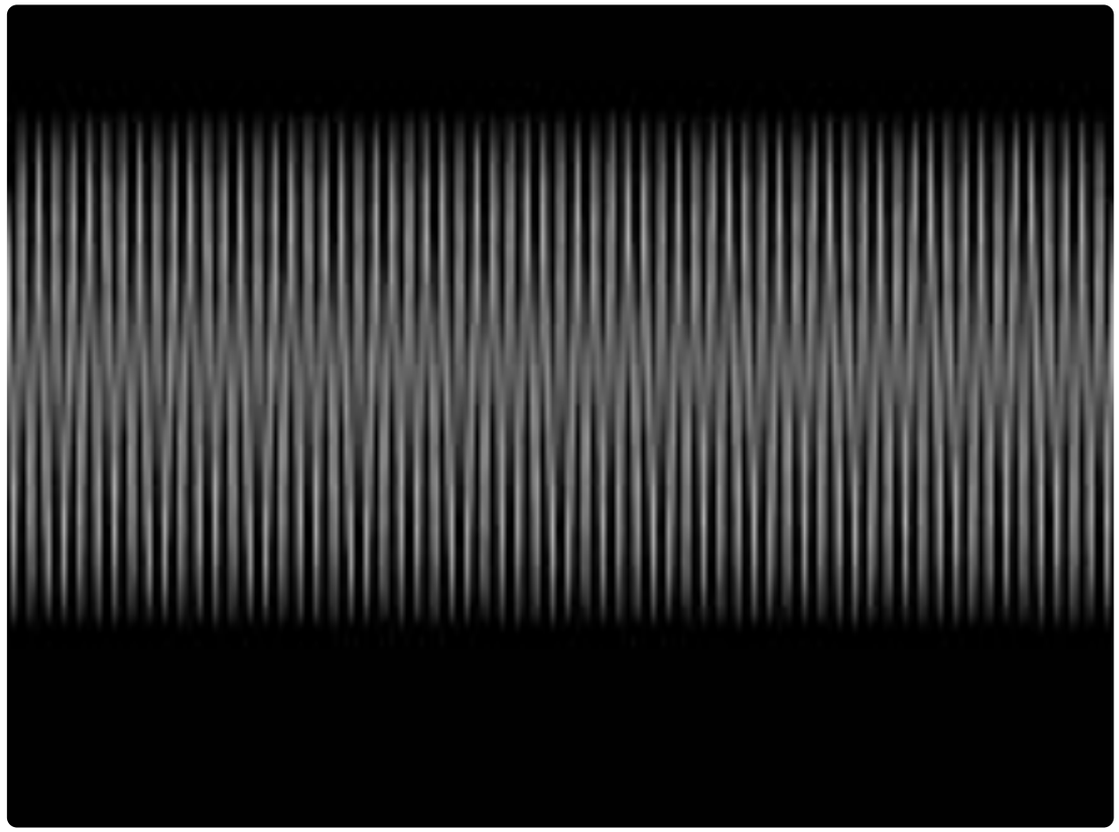

Continuous ultrasound delivers, as its name implies, a continuous stream of vibration (no off period). Depression of the foot pedal within position 3 increases the stroke length (i.e. power). The high energy levels may damage the corneal endothelium.



Machine Settings

Different machine settings are employed at each stage of the operation. The choice of available settings depend on the nature of the machine but there are some very basic general principles which are universal.

"Sculpt" settings "Quadrant removal" "Chop" settings "Epinucleus" settings

Sculpting

Adequate power should be used to emulsify the nucleus without moving it.

Movie 1.36 Fluid settings during sculpting.

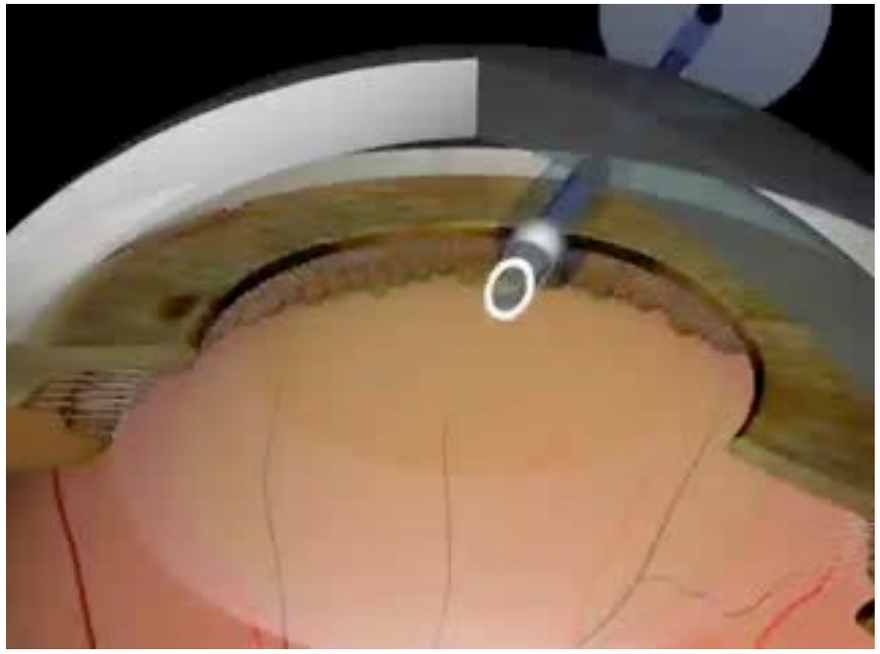

The aim is to make a trough or groove in the nucleus by shaving it off in successive slivers. This requires significant levels of ultrasound power. The flow is just sufficient to clear the lens particles. Excessive vacuum and occlusion should be avoided. This is because occlusion of the tip would move the nucleus and stress the lens zonules. Vacuum is not required to stabilize the lens as it is non mobile at this stage. Note the nucleus remains stable throughout.

Movie 1.37 Insufficient power during sculpting.

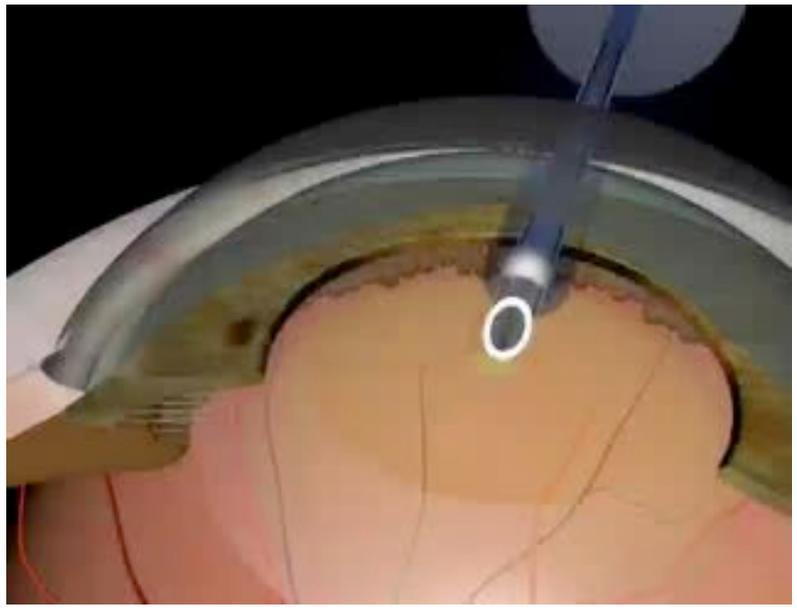

The nucleus is moving because the power is insufficient in relation to the density of the nucleus, the depth of the groove and the speed of movement of the tip. If the nucleus is dense the power should be increased and/or the tip moved more slowly and the groove made more shallow. The tip should not be used as a gouge or carving tool. This concept has given rise to the maxim "push with your foot, not with your hand".

Quadrant - removal of lens fragments

Whichever technique for nuclear disassembly is used, the pieces of nucleus produced need to be:

1. Engaged and moved centrally. This requires high vacuum and no phacoemulsification power.
2. Emulsified. This requires both ultrasound power and vacuum.

This may be easier if vacuum and emulsification can be controlled independently using the yaw function on the foot pedal.

Movie 1.38 Engagement

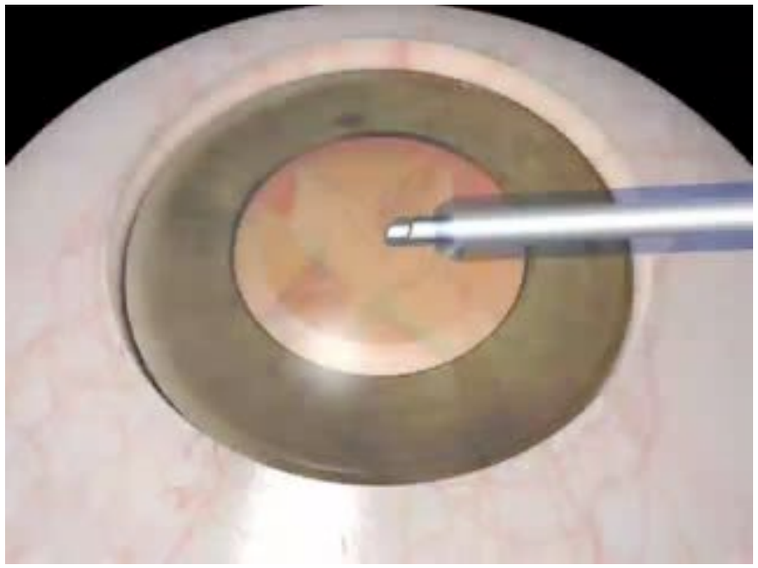

The tip is held against or embedded in the quadrant (a single very short burst of phaco - foot position 3 - may facilitate this). After this occlusion is present. The tip is then held still and the foot pedal backed off to position 2 to maintain vacuum, which is used to pull the fragment centrally. The vacuum is required to overcome the resistance arising from pressure by the remaining nuclear fragments.

Movie 1.39 Emulsification

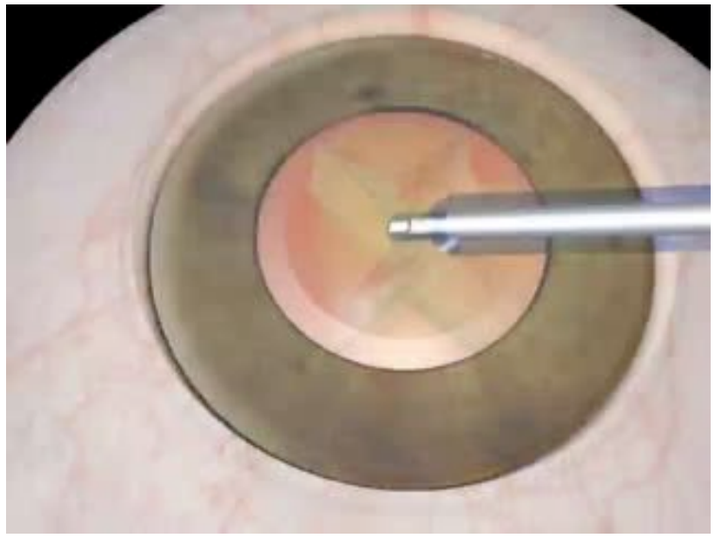

This requires high phaco power and sufficient vacuum and flow to counteract lens repulsion due to the jackhammer effect of the tip. The pedal is therefore moved into position 3. Emulsification is easier if some form of discontinuous (in this case pulsed) phacoemulsification is used.

Epinucleus

The epinucleus should have been separated from the capsule previously during hydrodissection. Initially only moderate vacuum is required to engage the epinucleus and lift it away from the capsule. Once free, the vacuum is increased to aspirate it in the centre of the anterior chamber. In the Epinucleus setting there is a small amount of phaco power (around15% by default) available at the end of footswitch position 3 to emulsify any harder pieces of epinucleus where aspiration alone is insufficient. The infusion pressure is high at this stage.

Movie 1.40 Removal of epinucleus

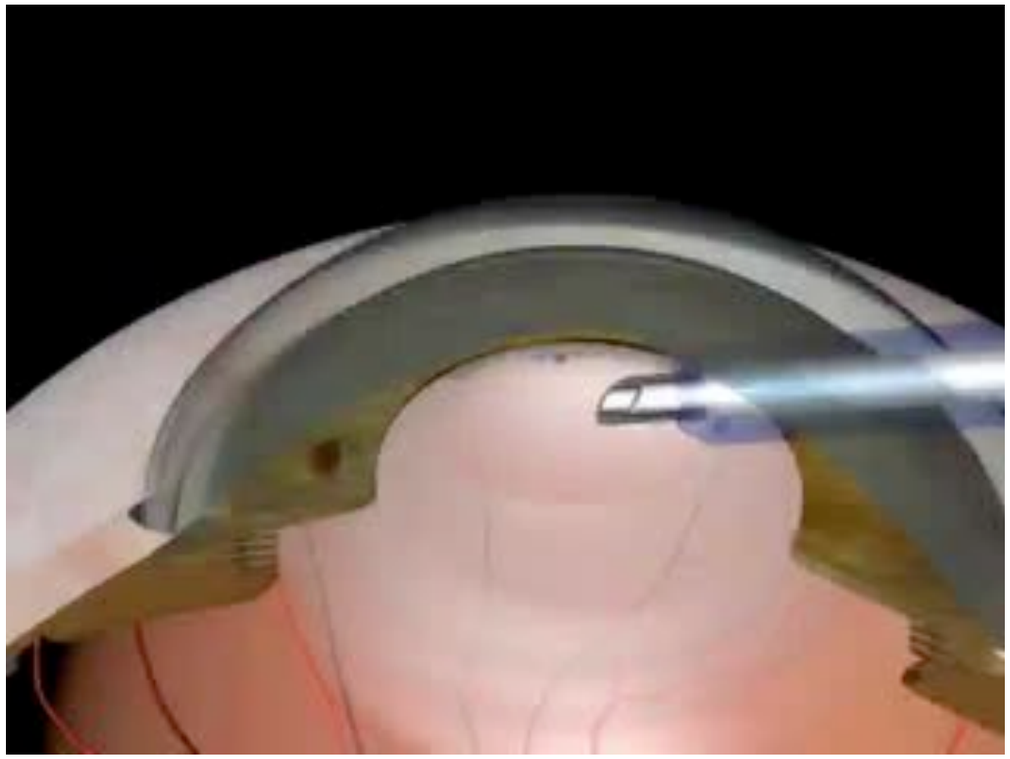

Occlusion with moderate vacuum is employed to engage and move the epinucleus. A high vacuum may be used once the epinucleus is safely positioned centrally, away from the capsule.

This may be easier if vacuum and emulsification can be controlled independently using the yaw function on the foot pedal.

Irrigation/aspiration

The different instruments at this stage used have radii which vary widely.

Poiseuille's law dictates that the resistance to flow in a tube is proportional to the fourth power of the radius.

So halving the radius increases the resistance to flow by a factor of 16.

It follows that the infusion and aspiration settings must be altered according to the instrument used.

Illustration 1.5 Irrigation/aspiration settings

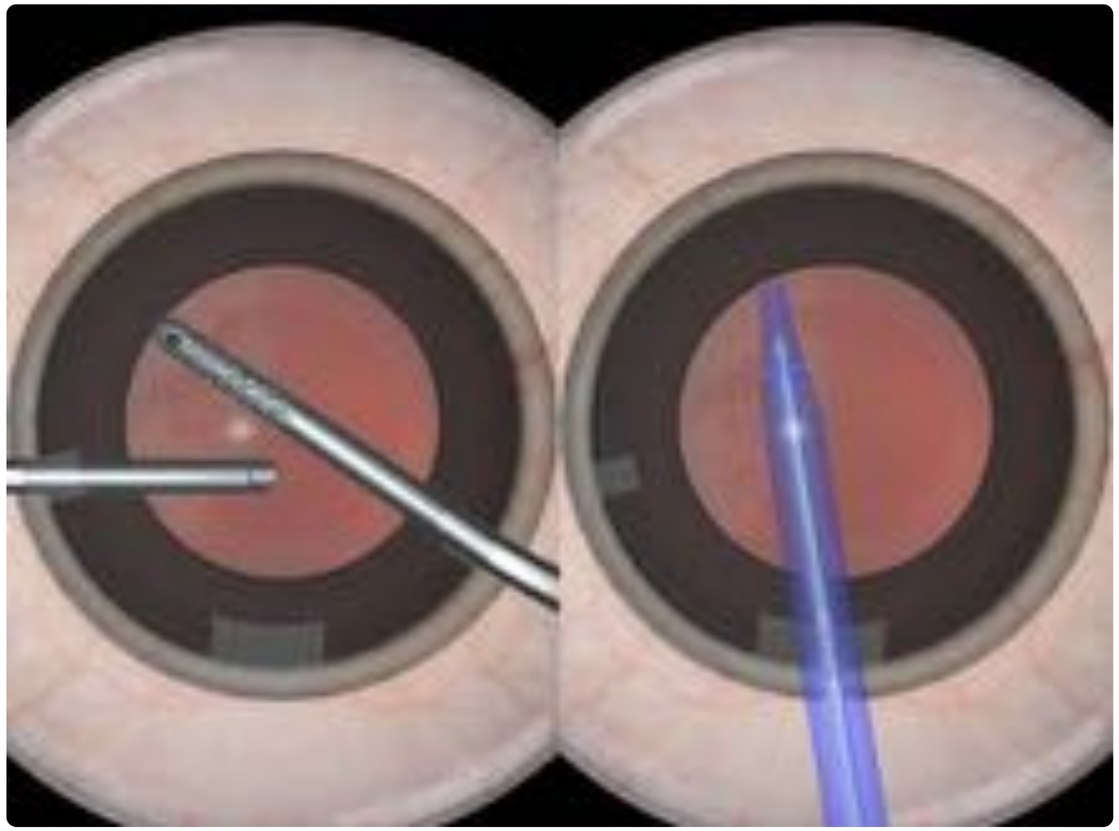

The infusion and aspiration settings vary widely between different systems.

Viscoelastics

Figure 1.7 Viscoelastic use

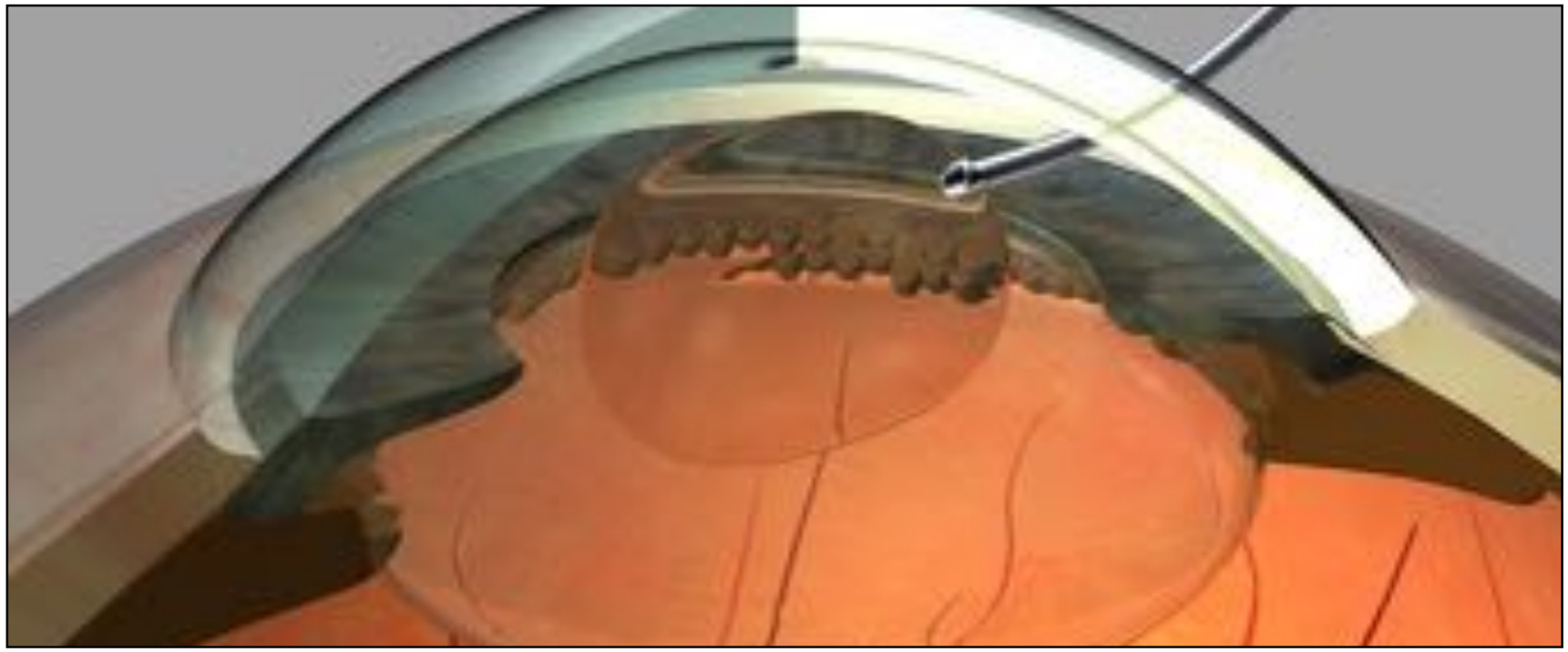

Injection of cohesive viscoelastic into the anterior chamber to prepare for capsulorhexis.

Viscoelastics are used to create and maintain space inside the eye (cohesive agents) and to provide a protective coating of the corneal endothelium (dispersive agents). They are now collectively referred to (rather cumbersomely) as Ophthalmic Viscosurgical Devices or OVD's.

Viscoelastic agents

Sodium hyaluronate is the most commonly used viscoelastic agent. It is the sodium salt of hyaluronic acid.

It is a polymer whose physical properties are determined by its chain length.

It was used originally and unsuccessfully in the 1970's as a permanent vitreous substitute. Only subsequently was it used as a removable agent during cataract and anterior segment surgery where it has been spectacularly successful.

Illustration 1.6 Hyaluronic acid.

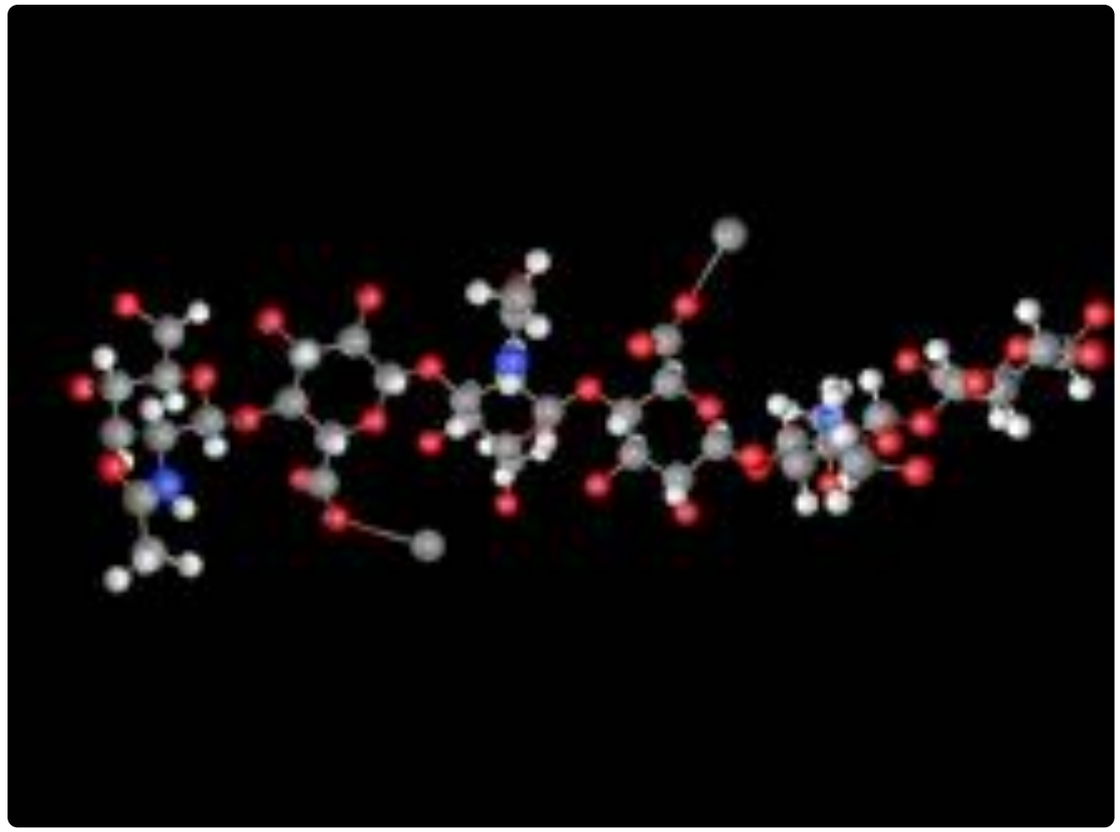

Hyaluronic acid is a polymer consisting of repeated units of the disaccharide shown here. One of its constituent sugars contains a single nitrogen atom (blue). There are three blue atoms here so this is a trimer. The hyaluronate forms used in clinical practice have a much longer chain length than this. These long chains tend to tangle, accounting for the viscosity of viscoelastics.

Viscoelastic agent properties

Shorter chain length molecules are used for coating ocular structures (dispersive OVDs).

Longer chain length molecules are very viscous and therefore tend retain their shape (cohesive OVDs).

Although cohesive viscoelastics are viscous when static they can become fluid when subjected to shear strain and so can be injected through quite narrow cannulas. This is because are **pseudo-plastic**. They become less viscous when they start to move (i.e. the ratio of shear strain to shear stress falls as the shear stress increases). This behavior is also seen when emptying ketchup from a bottle - it is slow to start moving but once it does it can move very quickly.

Both types of viscoelastic may be used together - for example in the **soft shell** phacoemulsification technique.

Movie 1.41 Dispersive viscoelastic

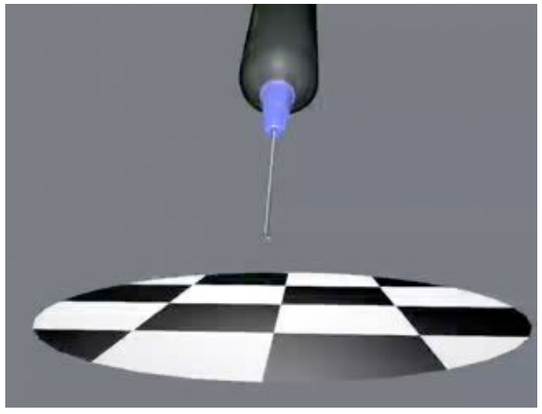

These viscoelastics have relatively short chains. These are less viscous and tend to spread out over a surface, providing a protective coating.

Movie 1.42 Cohesive viscoelastic

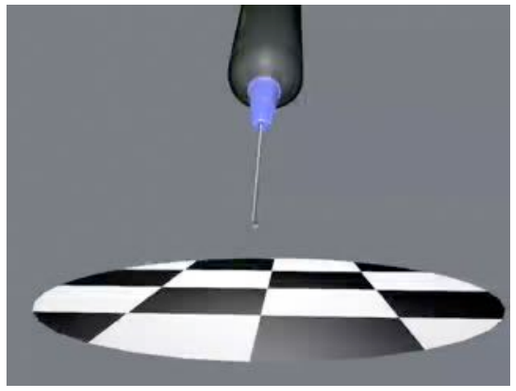

The long chain lengths tend to tangle which increases their viscosity. The viscoelastic agent therefore maintains its' shape. This is useful when trying to fill and maintain a space in the eye, for example to flatten the anterior capsule before capsulorhexis.

Knowledge review - phacofluidics

Review 1.1

Question 1 of 5

Identify the components of this phacoemulsification handpiece:

Horn | Piezoelectric crystal | Infusion sleeve | Aspiration port

Check Answer

CHAPTER 2

Surgical Anatomy



In order to operate safely on the anterior segment of the eye one needs to understand the dimensions, ultrastructure and relationships of the structures within it.

Corneal dimensions

The exact dimensions of the cornea are somewhat variable.

- The cornea is wider horizontally than vertically, so peripheral temporal incisions are further from the visual axis than superior incisions.
- The corneal diameter is more constant than other easily visualized parameters (the pupil diameter, for example, is extremely variable). It is frequently used as a 'yardstick' during surgery. One frequently used axiom is to make the capsulorhexis diameter half the vertical diameter of the cornea.
- The cornea is very thin (≤ 1 mm) so great precision is required when making incisions.

Figure 2.1 Corneal thickness

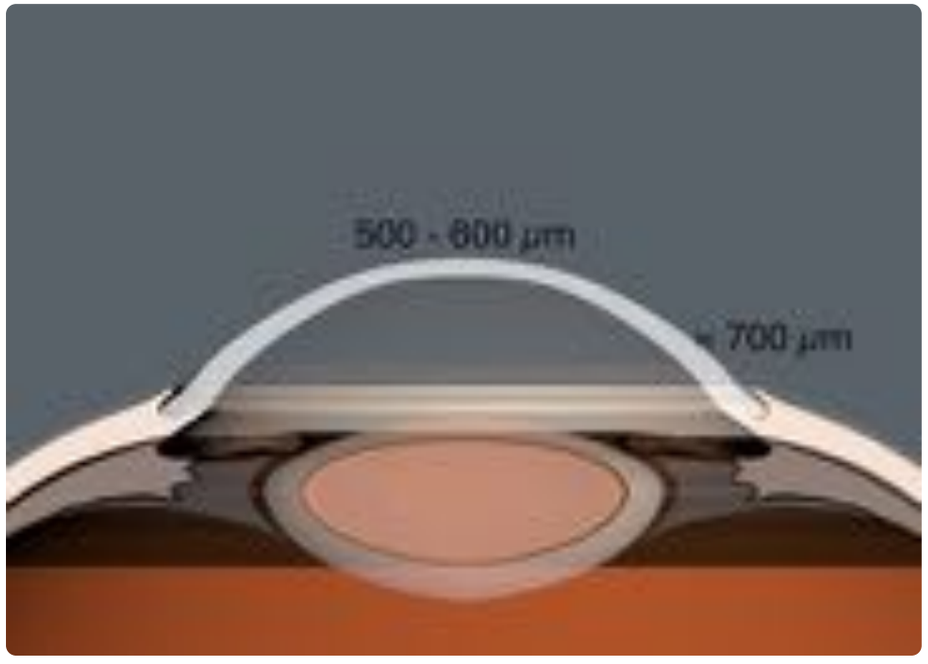

The cornea is thinner centrally.

Figure 2.2 Corneal width

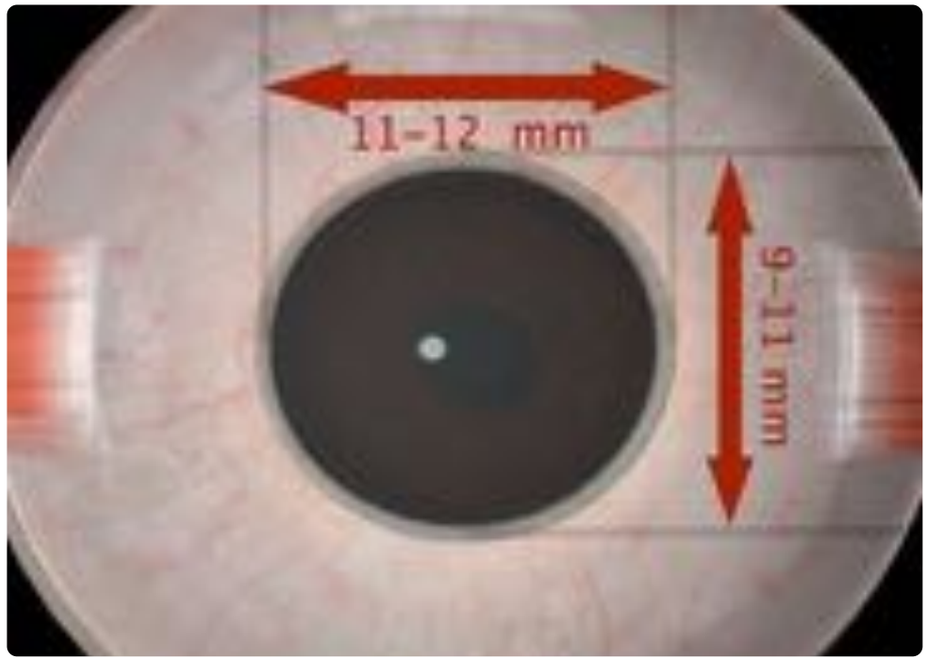

These dimensions are approximate. The corneal diameter is always greater temporally.

Interactive 2.1 Schematic (not to scale) illustration of the cornea.

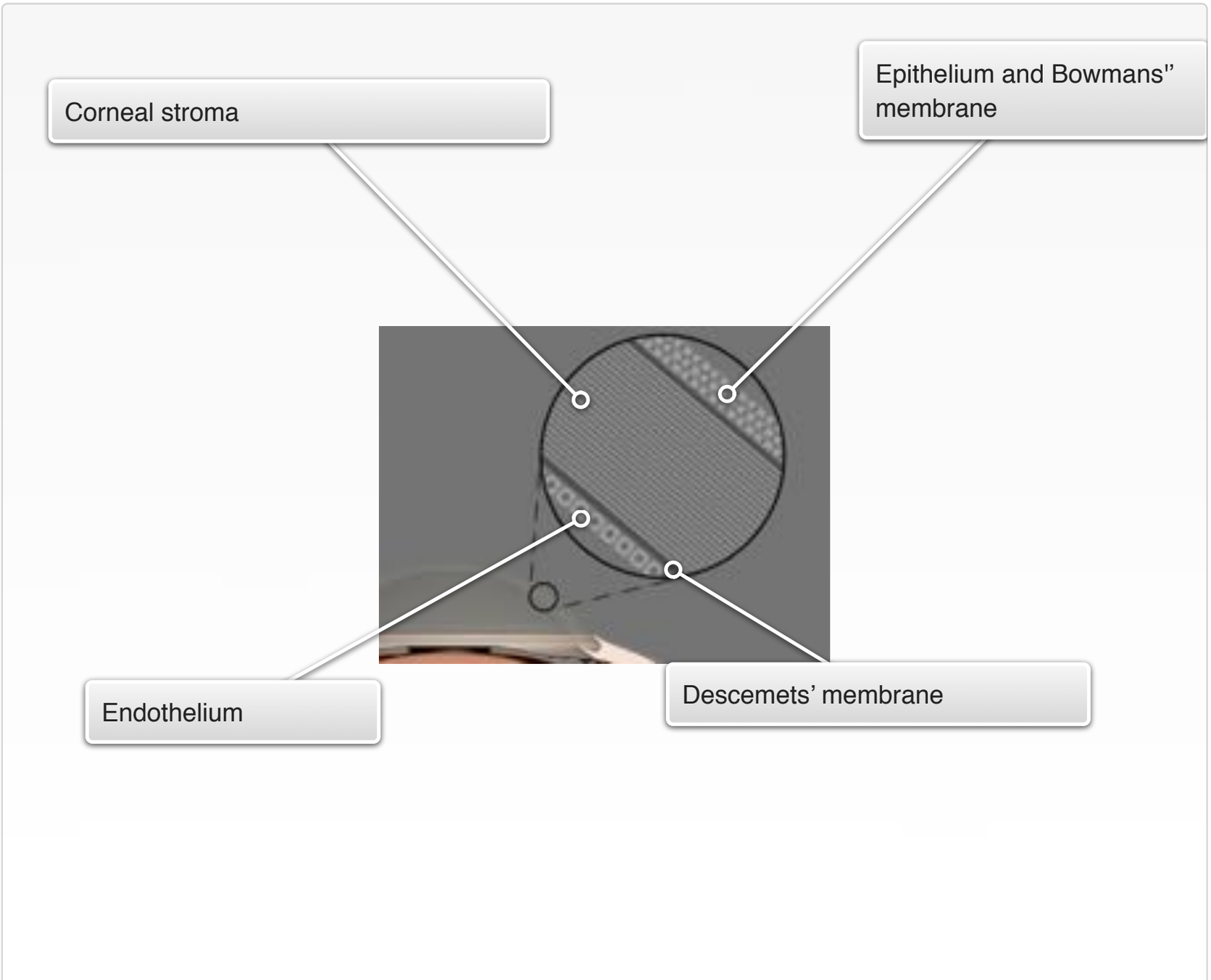

The limbus

The limbus ("edge", latin) is the junction between the cornea (which has regularly oriented lamellae and is therefore transparent) and the sclera (where the layers are less organized, with consequent loss of transparency).

The edge of the conjunctiva does not match the limbus. Small ridges ('Palisades of Vogt') extend anterior to the limbus onto the cornea. Corneal incisions here therefore cause hemorrhage (which may be beneficial for wound healing). Stem cells is this area are the source of new populations of corneal epithelial cells if the corneal epithelium is damaged. There is continuous turnover of corneal epithelium which is replaced approximately once a week.

Figure 2.3 The limbus



Conjunctival vessels extend anterior to the junction between sclera and cornea.

Interactive 2.2 Lens anatomy

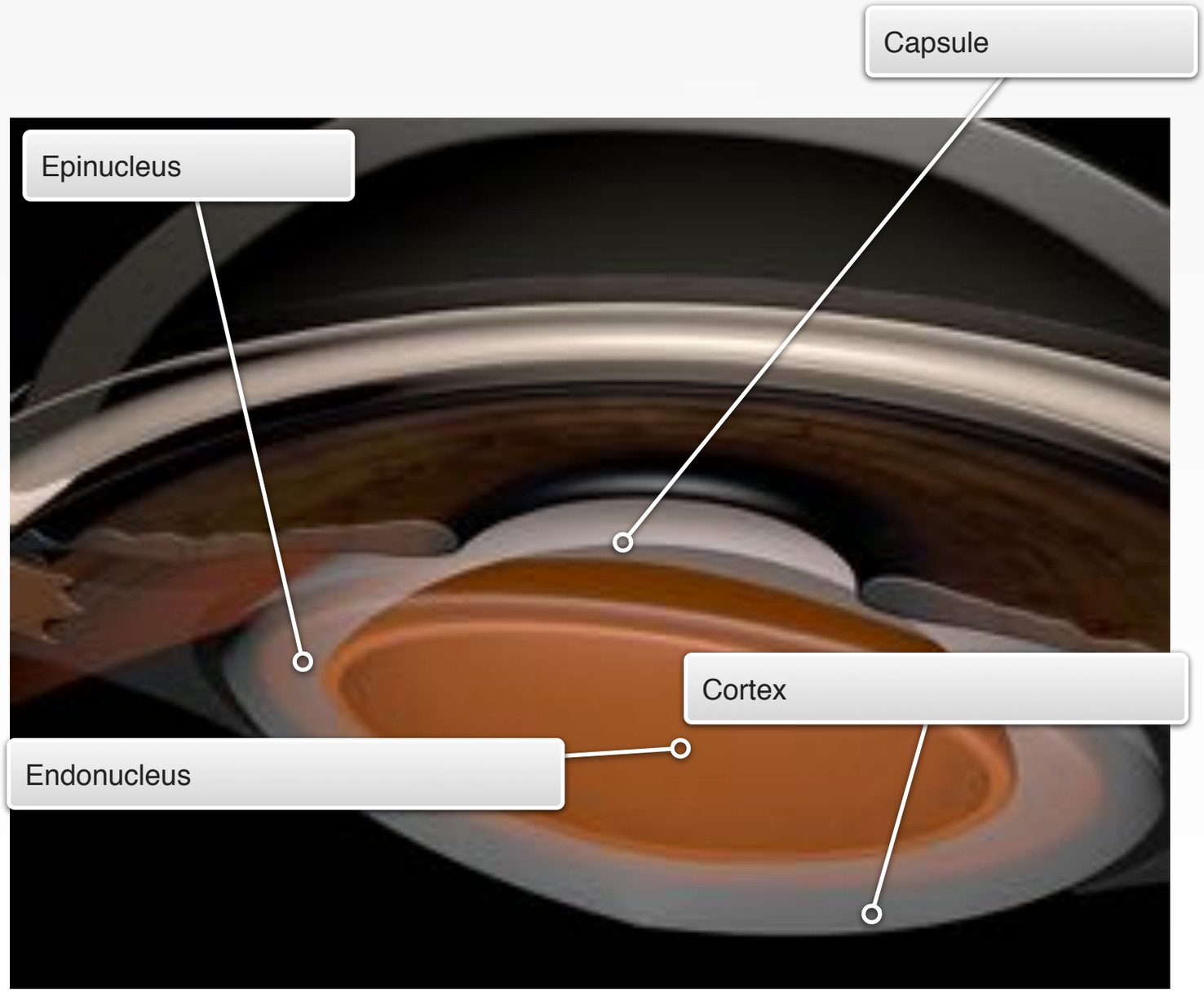

The lens capsule

The lens capsule is a basement membrane with its' epithelial cells on the inner layer. The outer part may therefore be stained with basement membrane dyes such as trypan blue.

Illustration 2.1 The lens capsule

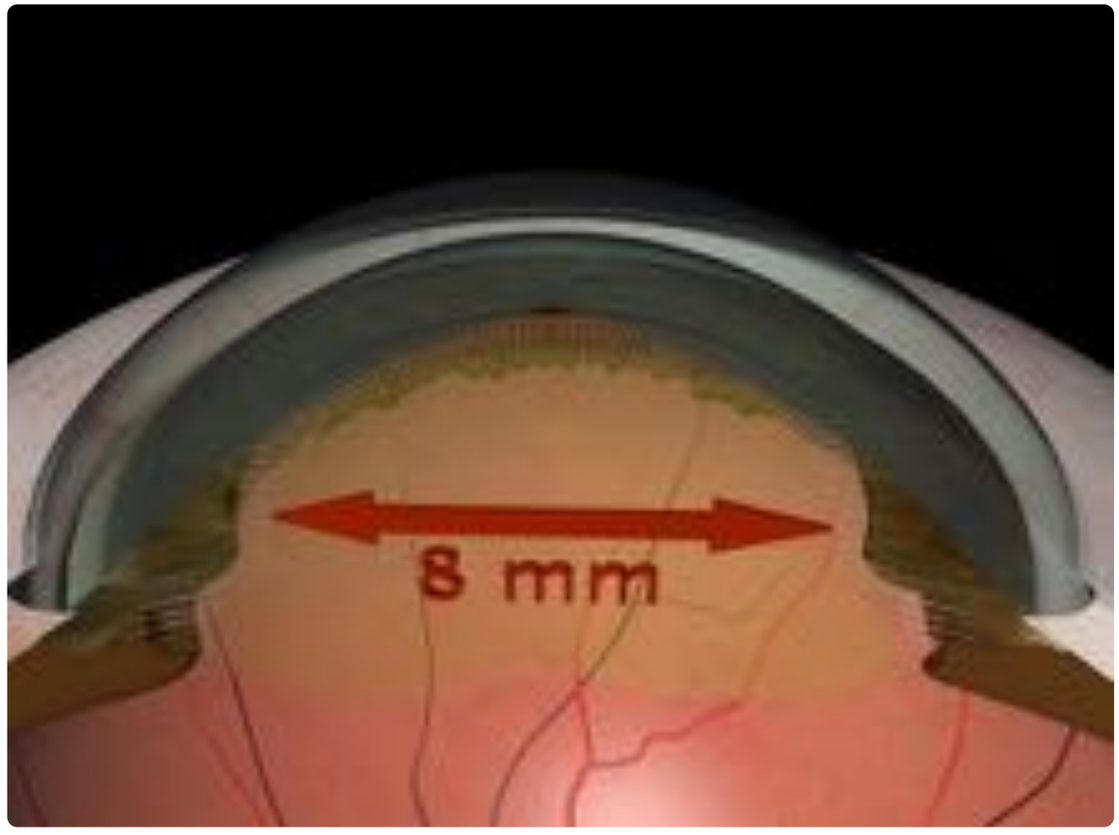

The anterior zonules insert into the peripheral anterior capsule. The inner 7-8mm is (usually) free of zonules. Capsulorhexis should not extend outside this safe zone as engagement with the zonules may precipitate radial tear out.

Lens fibers and layers

The lens fibers loop radially between the anterior and posterior poles of the lens, where they meet at Y shaped junctions or sutures. This creates radial cleavage planes which are opened when cracking, much akin to splitting wood along its grain.

The lens fibers are arranged in layers which become increasingly compact centrally. Hydrodissection and hydrodelineation open up cleavage planes between adjacent concentric layers

Illustration 2.2 The radial orientation of lens fibers

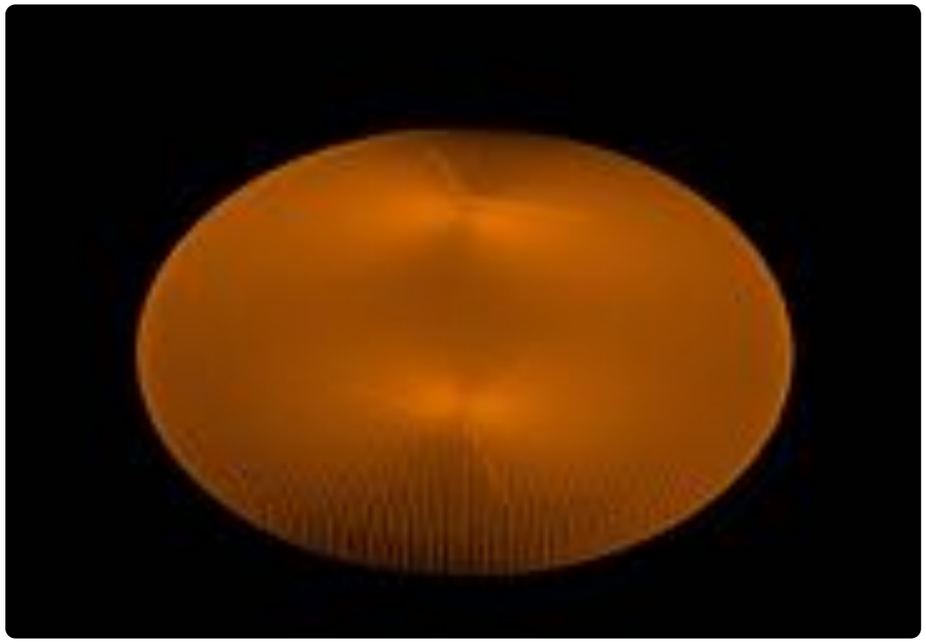

Cracking opens up radial cleavage planes between these fibers.

Illustration 2.3 The lamellar arrangement of lens fibers



These are important when performing hydrodissection and hydrodelineation.

Anterior chamber depth

- The average anterior chamber depth is approximately 3 mm in an emmetropic eye.
- The depth of the anterior chamber varies with the refractive status. Shorter eyes generally have shallower anterior chambers.
- The peripheral anterior chamber is much shallower. Short peripheral wounds are therefore more likely to leak and cause iris prolapse than more centrally placed wounds, which may leak without causing iris prolapse.

Figure 2.4 Anterior chamber depth

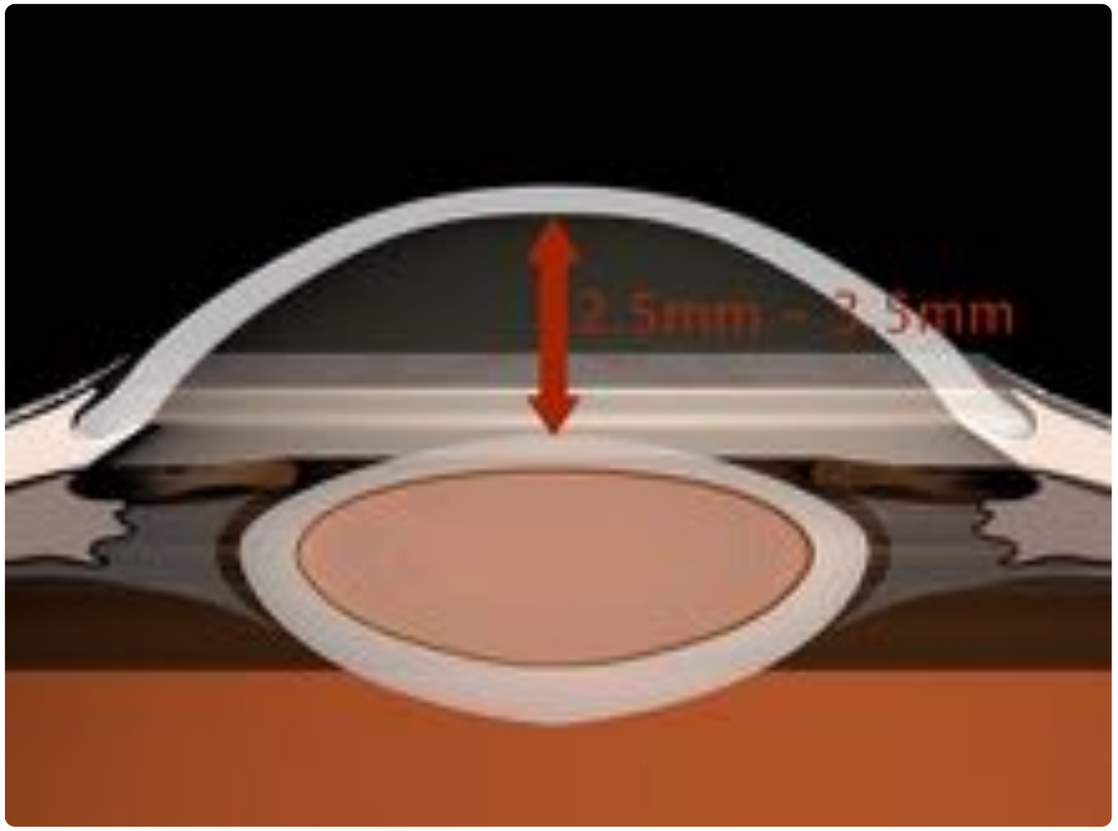

Note the anterior chamber is much shallower peripherally.

Review 2.1 Corneal anatomy

Question 1 of 2

Which statement is INCORRECT.

- **A.** The horizontal corneal diameter is greater than the vertical diameter.
- ✓ **B.** The central thickness of the cornea is approximately 1,000 μm.
- **C.** The horizontal corneal diameter is 11-12 mm

Check Answer

Review 2.2 The capsule

The zonules insert into the peripheral lens capsule. The diameter of the central safe 'zonule free' area is usually approximately:

- **A.** 5mm
- **B.** 6 mm
- ✅ **C.** 8 mm
- **D.** 10 mm

Check Answer

Review 2.3 The anterior chamber.

The anterior chamber depth is typically

- ✅ **A.** 2.5 - 3.5 mm
- **B.** 1.5 - 2.5 mm
- **C.** 3.5 - 4.5 mm
- **D.** 4.5 - 5.5 mm

Check Answer

CHAPTER 3

Preoperative Assessment

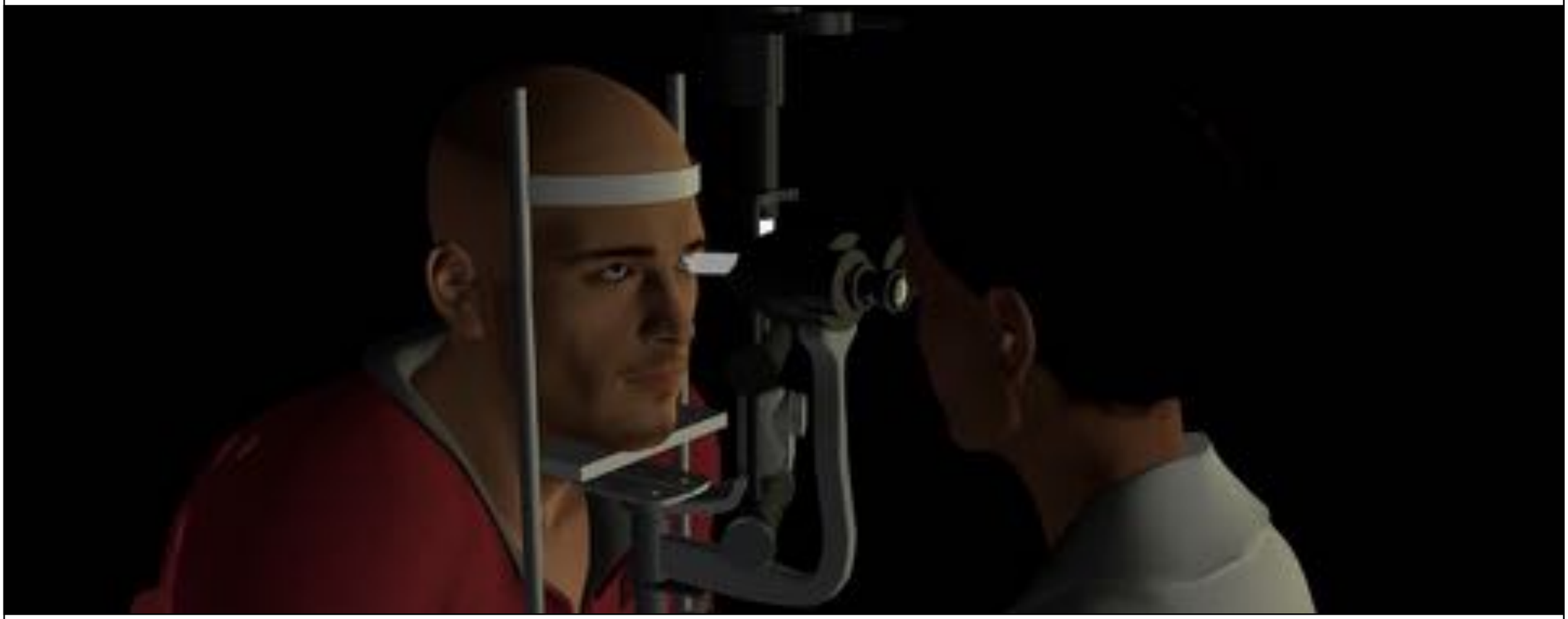

Before considering surgery all patients should undergo a comprehensive assessment of their ocular and systemic health. Many surgical problems can be anticipated and thereby avoided by careful planning.

Facial morphology.

Inspection of the facial morphology allows one to anticipate problems with surgical access, such as a prominent brow, deep-set eye or large nasal bridge.

Patient cooperation

A patient who in intolerant of applanation or unable to look directly into the slit lamp beam is not a good candidate for topical anesthesia. Some form of local block should then be considered.

Postural problems

Inability to lie supine or extend the neck (for example due to kyphosis) should be flagged up prior to surgery to allow the patients position to be optimized. Extreme kyphosis can render safe surgical access impossible.

Figure 3.1 Preoperative assessment - facial morphology



A large nose and nasal bridge - a temporal approach may be best in this case. It may be difficult to get a good seal of the surgical drape between the eye and the nose

THE ANTERIOR SEGMENT

Lens examination may reveal abnormalities that influence surgical planning.

Figure 3.2 Preoperative assessment of the anterior segment

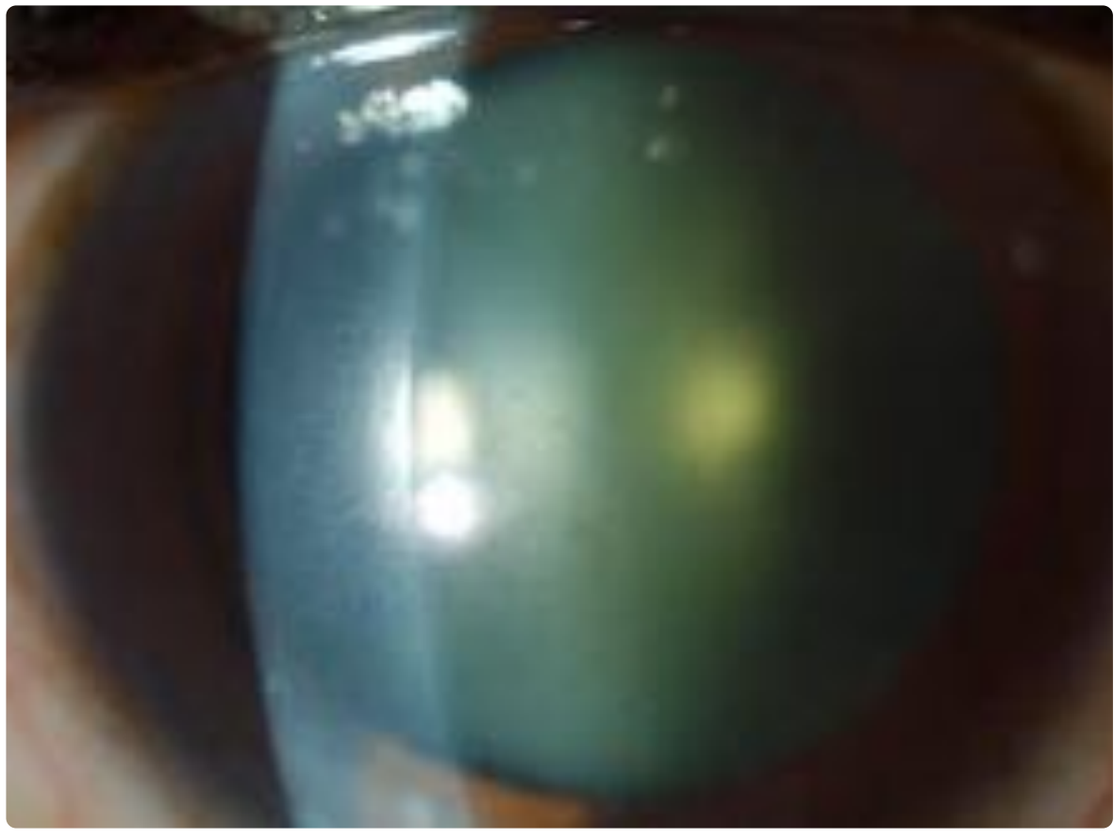

Fuchs endothelial dystrophy (note the dimpled appearance of the specular reflections from the endothelium). Endothelial loss during and after surgery may cause the endothelial pump to fail causing corneal edema and visual loss.



THE REST OF THE EYE

The eye should be examined for other causes of visual loss. For example it is not uncommon for macular holes or early AMD to be discovered only after cataract surgery has been performed.

Ocular features which may make surgery more challenging include:

- High myopia or previous vitrectomy (deep anterior chamber during phacoemulsification - reverse pupil block or 'lens iris diaphragm retropulsion syndrome' (LIDRS).
- Very short axial length (shallow anterior chamber during phacoemulsification).
- Buphthalmos with corneal thinning (the corneal rigidity may be insufficient to create a self sealing valve and corneal sutures may be required).

Illustration 3.1 Cataract and macular pathology

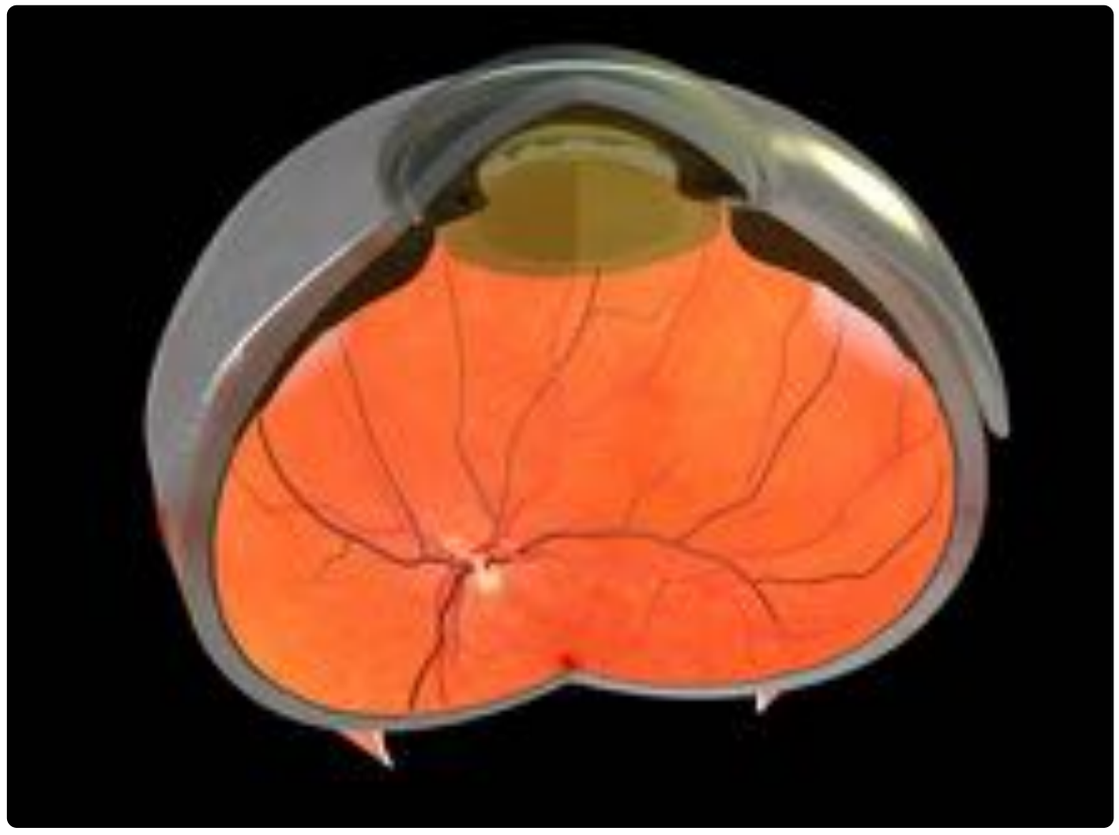

This patient has a cataract and a macular hole. The patient gives a history of distortion which points to a cause of visual loss other than the cataract.

Knowledge review

Review 3.1

A patient has been referred for cataract surgery. Which of these symptoms should alert you to indicate an *alternative* cause of visual loss:

- **A.** Monocular diplopia.
- ✓ **B.** Distortion.
- **C.** Glare.

Check Answer

Review 3.2

This patient has been referred for cataract surgery. He suffers from cervical spondylosis and has great difficulty extending his neck fully. Surgical access is likely to be best if the surgical approach is:

- **A.** Frontal
- ✓ **B.** Temporal

Check Answer

CHAPTER 4

Preparation for surgery

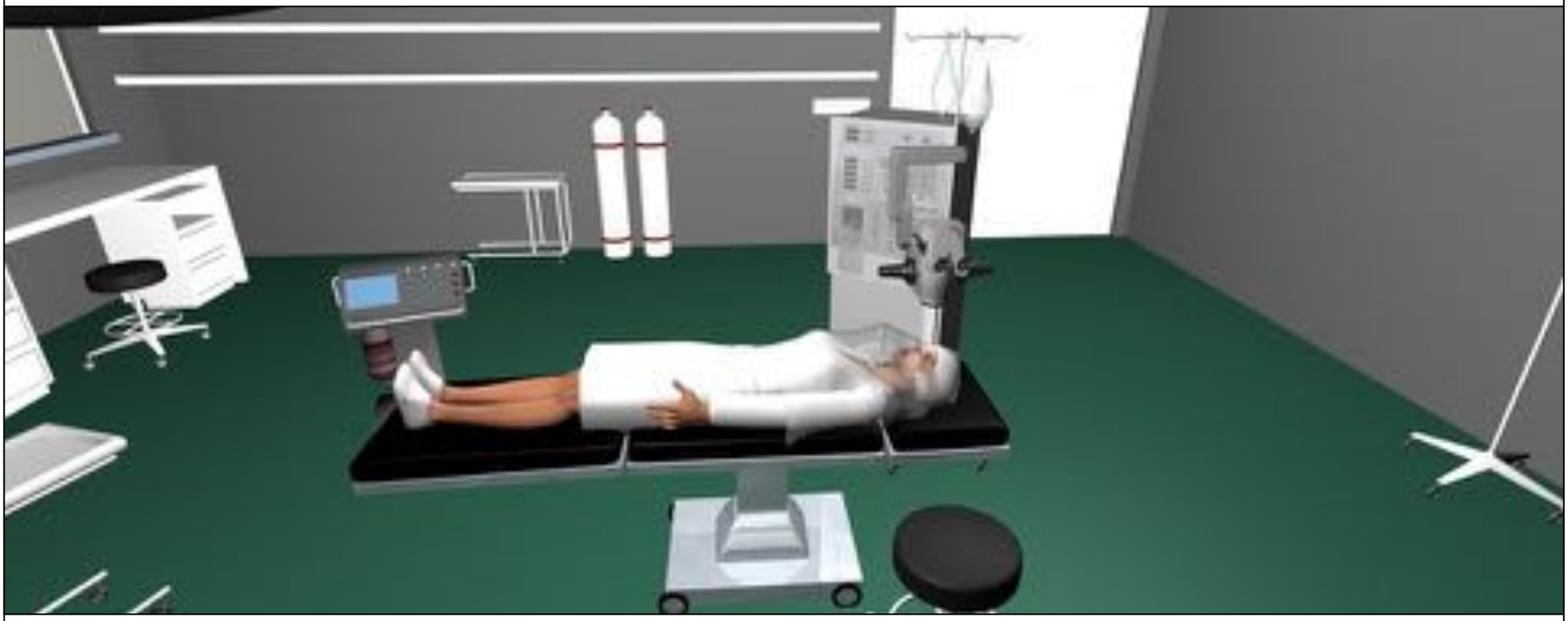

Care and attention to small details when preparing the patient for surgery prevents problems later.

The World Health Organization (WHO) Checklist

Surgery on the incorrect eye and insertion of an incorrect intraocular lens are significant causes of litigation in ophthalmology.

The accompanying diagram illustrates the way the check list is implemented at the authors' hospital.

Interactive 4.1 The use of the preoperative checklist

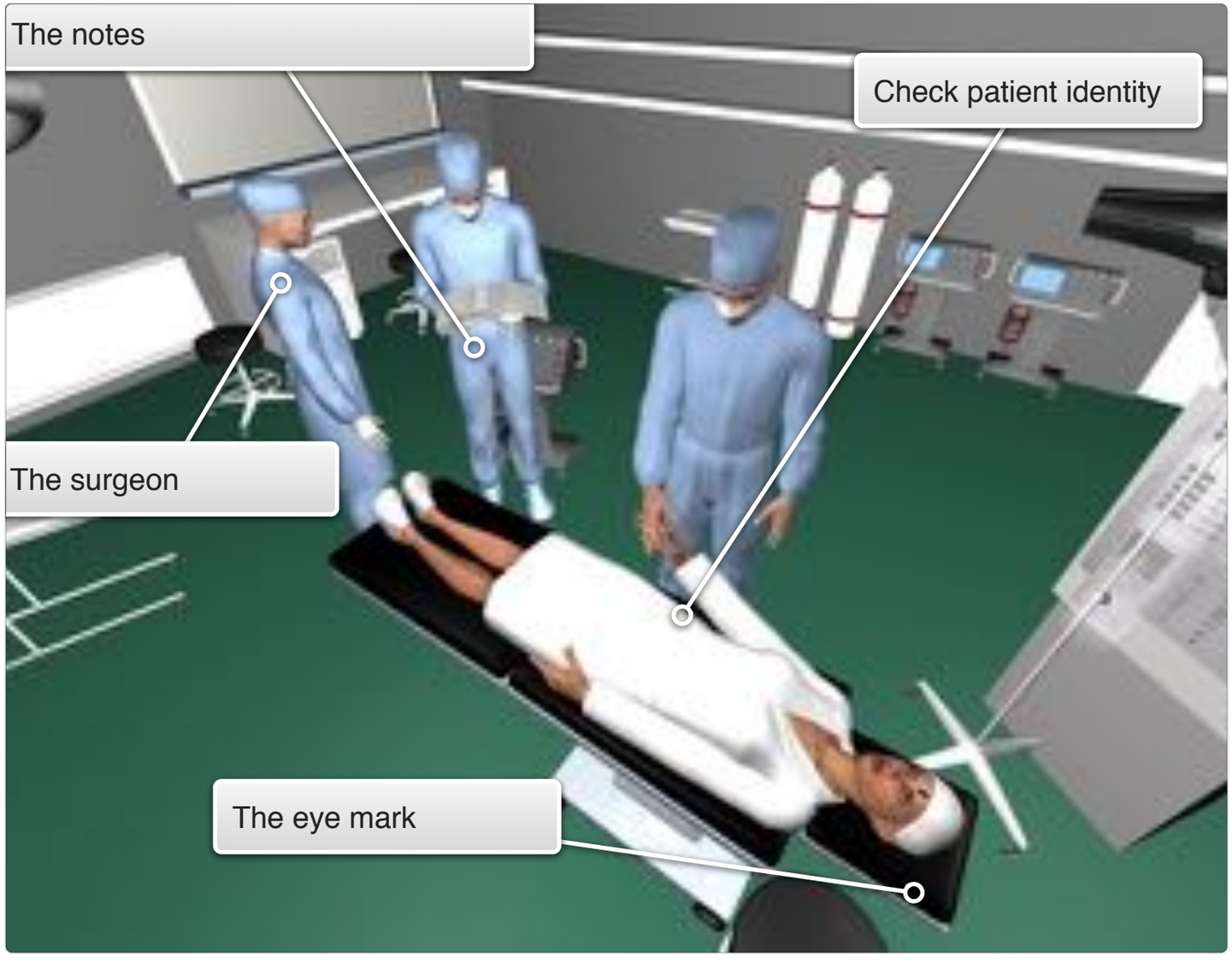

Atul Gawande introduced the concept of a check list to prevent errors such as this. He advocated the use of preoperative check lists, with a tick in each box. He believes that error prevention is most effective when this is a shared, rather than an individual, responsibility. This approach

PATIENT POSITIONING

Assuming the surgery is performed under topical or intracameral anesthesia, correct positioning of the patient is the next step.

Flexion/extension

Ideally the superior and inferior orbital rims should be at the same level. A small degree of neck extension may be required to achieve this. This is not always possible in practice. Operating couches may be adjusted to allow a patient with kyphosis or cervical scoliosis to maintain a flexed neck with a horizontal orbital rim by placing the patient in a Trendelenberg position (tilting the patient head down). This is not always possible (for example due to mild congestive cardiac

Figure 4.1 Flexion and extension

Ideally the orbit should be as flat as possible.

Rotation

The orbital rim slopes horizontally. Surgical access to the globe is greatest when the head is rotated away from the eye undergoing surgery. This is the optimal position for many extraocular procedures such as strabismus or scleral buckling surgery. However during phacoemulsification head rotation in this direction is likely to create pooling of irrigation fluid around the inner canthus. Specular reflections from the flat but mobile fluid surface may seriously degrade the surgi-

Figure 4.2 Neck rotation

The lateral slope of the orbit is usually sufficient to prevent fluid pooling with the neck in a neutral position.

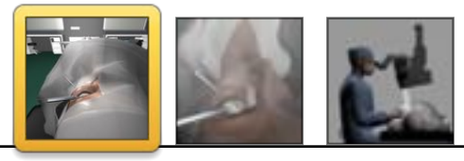

ANESTHESIA

Topical and intracameral anesthesia

A major advantage of topical anesthesia is the ability to ask the patient to look in the desired direction. In particular asking the patient to look directly at the microscope light helps to maintain a good red reflex during capsulorhexis.

Patients are assessed preoperatively for their suitability for topical anesthesia. Patients should be counseled before surgery that they will see a very bright light initially and that they will intermittently feel pressure around the eye (from the speculum and in the eye (as changes in anterior chamber depth occur, due to stretching of uveal tissue).

Supplementation with intracameral 1% lidocaine abolishes the sensation from the iris. This is particularly useful in very myopic or vitrectomized eyes where anterior chamber instability may cause discomfort from stimulation of the iris and ciliary body. The patient should be pre-warned of very transient stinging sensation during injection.

Movie 4.1 The principal advantage of topical anesthesia - the red reflex.

This patient, who was very cooperative during examination, was operated under topical and intracameral anesthesia. She had been instructed to look directly into the light when told to do so. She was given a minute to accommodate to the brightness of the operating light and then asked to look directly into it. While the red reflex is intermittently lost when the surgeon moves the eye (highlighting the importance of wound neutrality) it is, for the most part, very good.

Regional blocks

Uncooperative or nervous patients may require some form of regional block. Subtenons anesthesia is a safe alternative to sharp needle blocks and has the additional advantage that it can be safely delivered per operatively if required.

Interactive 4.2 The anatomy of Tenon's Capsule and the subTenon space

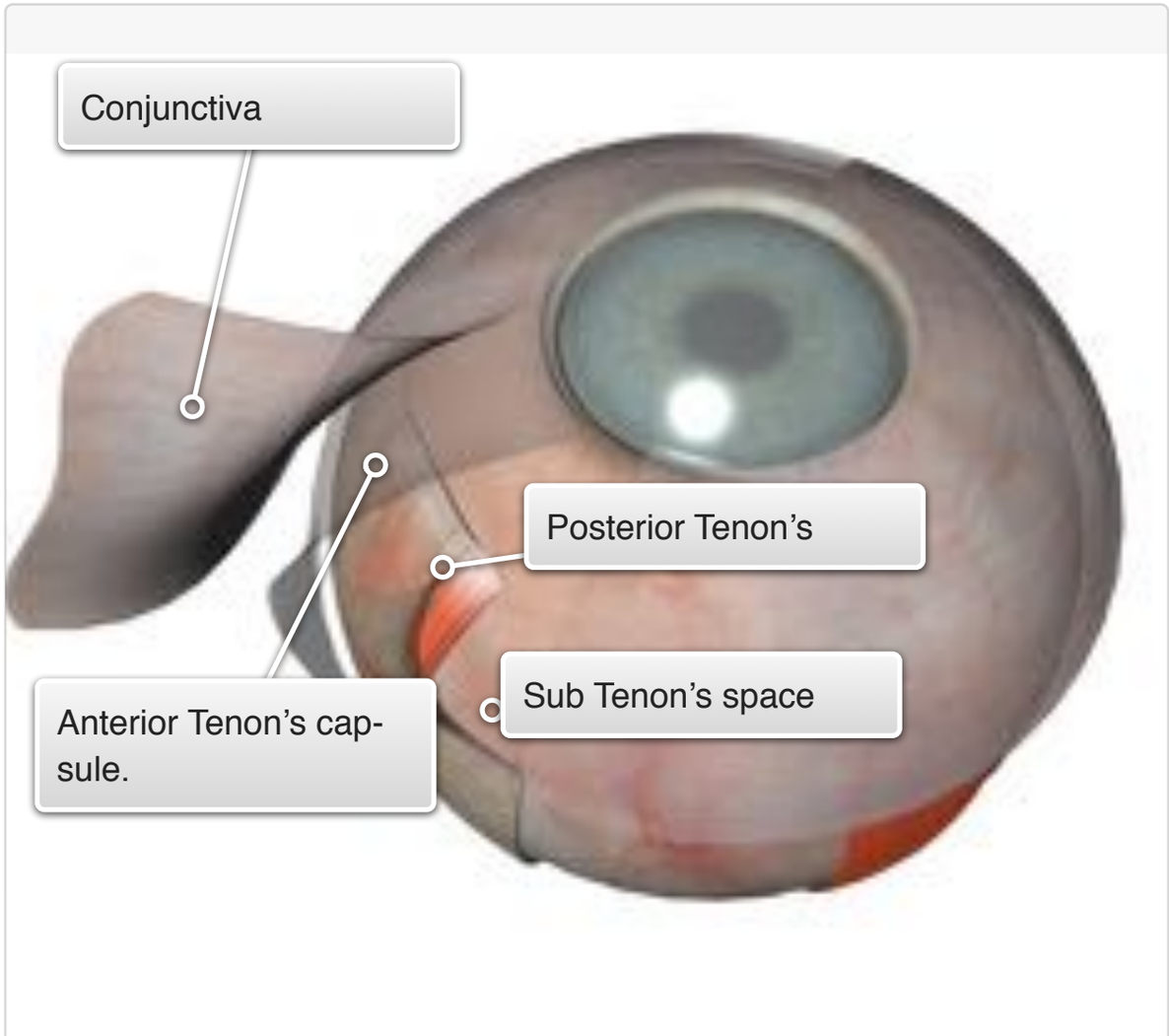

Figure 4.3 Subtenons anesthesia

A drop of anesthetic is placed in the inferior fornix. An additional drop is then placed in the superior fornix so that the whole of the bulbar and tarsal conjunctiva is anesthetized. This prevents the iodine from stinging. A drop of 5% aqueous iodine is then instilled.

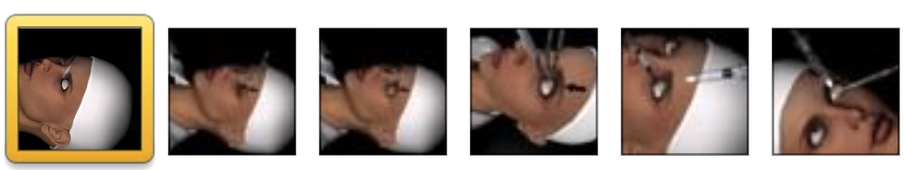

STERILIZATION

Most cases of endophthalmitis are probably caused by contamination with commensal bacteria from the patients' own lids, lashes and conjunctival sac. Good skin and conjunctival antisepsis together with fastidious draping reduce the likelihood of developing postoperative endophthalmitis. Application of povidone-iodine for one minute to the lids and lashes kills 97% of the bacteria present.

Figure 4.4 Operation site cleaning

A drop of aqueous iodine is placed in the inferior fornix. The eye should be anesthetized first.

Movie 4.2 Application of antiseptic agent

An antiseptic agent such as Hibiscrub or Povidone iodine is applied to the lids and lashes and left to work one minute.

Movie 4.3 Drying

After one minute the skin and lashes are thoroughly dried (as the adhesive drape will not stick to damp surfaces)

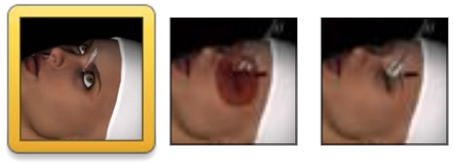

Figure 4.5 The drape

This is an example of poor draping. The drape is not adherent to the lids and lashes, probably because they were damp when the drape was applied. Lashes are in contact with the surgical instruments.



Illustration 4.1 Drape orientation

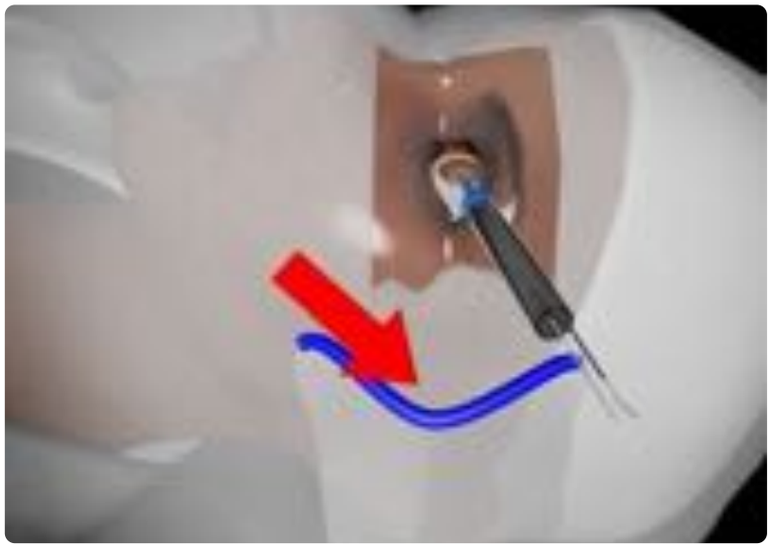

In order to catch fluid leaking from the eye the drainage pouch (arrow) must be located temporally.

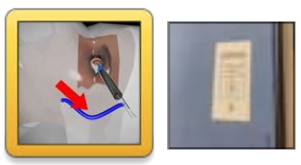

Movie 4.4 Applying the drape

With the lid retracted the folded drape is applied directly onto the open eye. The drape is then unfolded and applied to the surrounding tissues

Movie 4.5 Cutting the drape and inserting the speculum

The drape is carefully cut, avoiding the cornea, with blunt tipped scissors. The speculum is placed under each lid separately. A pleat of drape tucked under each blade of the speculum keeps the lashes covered.

Inattention to posture is a common error among trainee cataract surgeons.

Figure 4.6 Body posture

A hunched posture, with flexion of the spine, may give rise to musculoskeletal problems.



Figure 4.7 Position of the hands

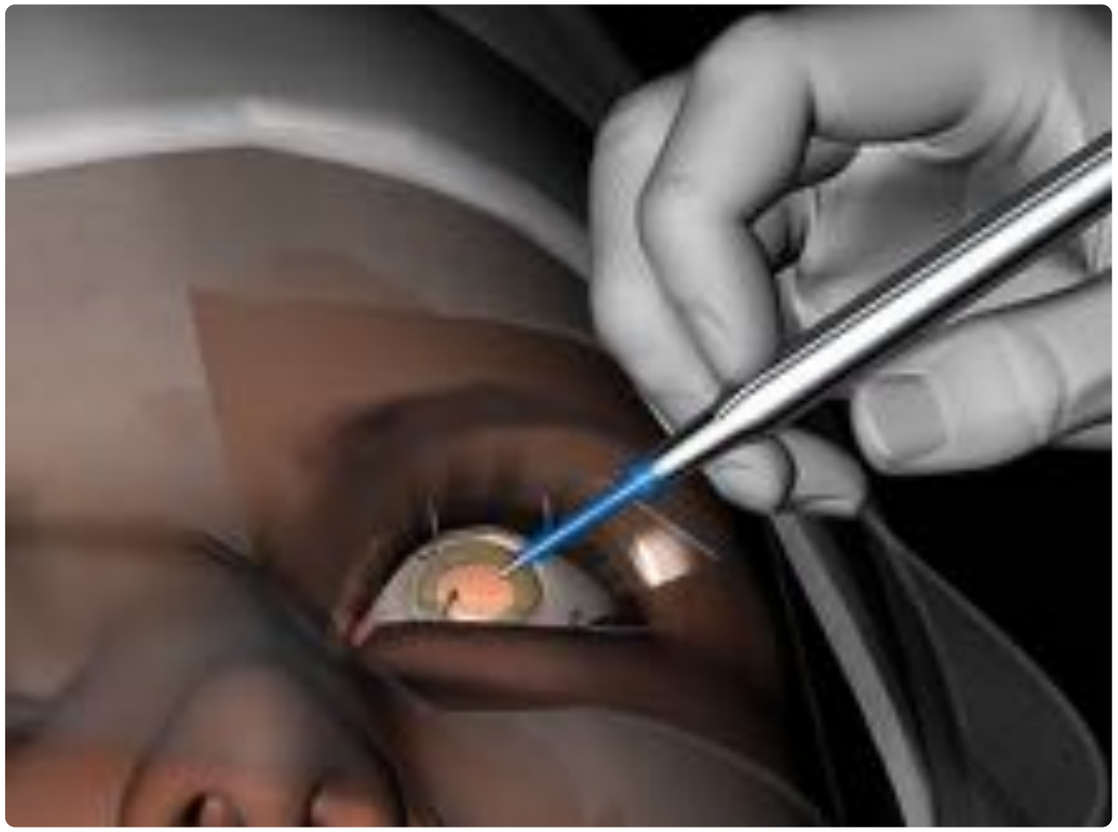

The optimal grip is a precision grip such as this writing tripod. Note also that the knuckles of the fourth and fifth fingers are resting on the patients head and the other fingers are in contact with each other. As well as stabilizing the instruments this ensures that any movement of the patients' head is transmitted to the instruments, reducing their relative movement within the eye.

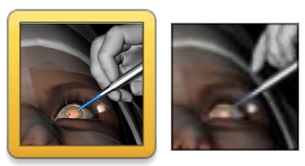

Figure 4.8 Features of the operating microscope

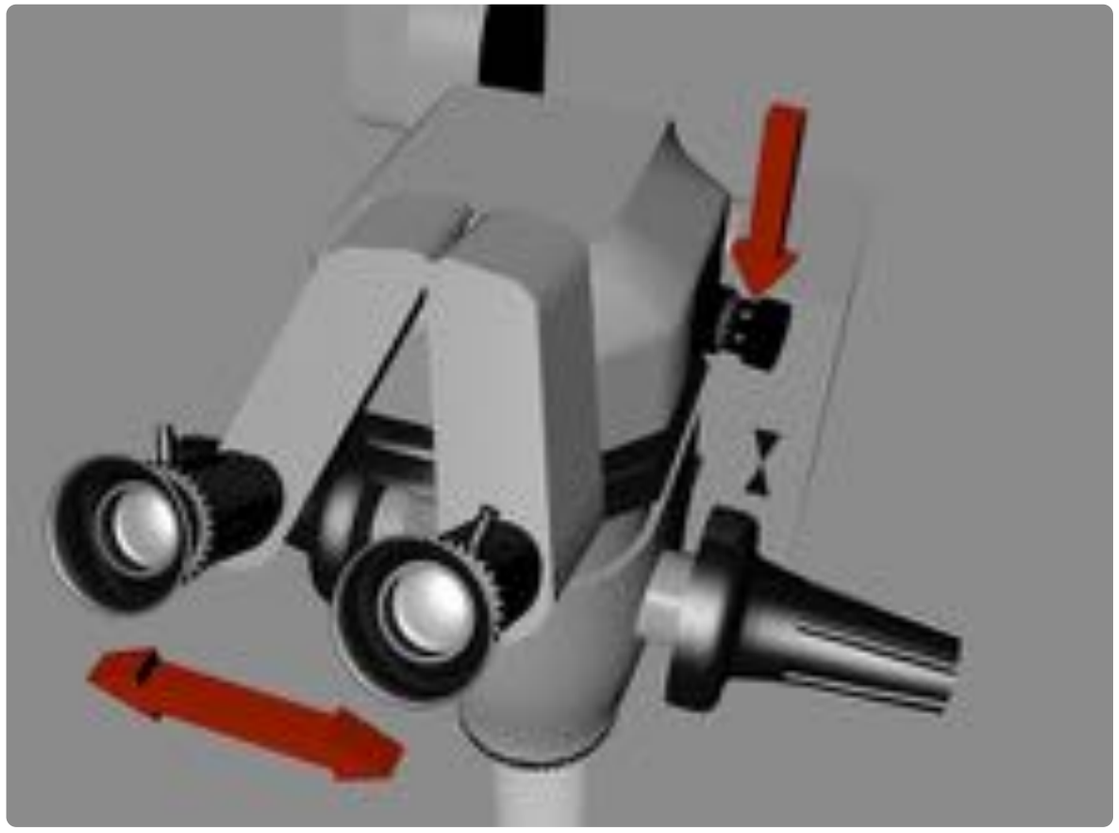

The separation of the eyepieces (inter-pupillary distance) is controlled by an adjustment knob.



Focussing the microscope

A common error among trainee surgeons is to accommodate to focus rather than to focus with the microscope. While this may result in a clear image initially, it becomes blurred as the ciliary muscles relax. This problem may be overcome by relaxing the eyes and focussing the microscope upwards a little until the image starts to blur, then focussing down slightly. The image should then be in focus without accommodation.

Movie 4.6 Focussing the microscope

The working distance (effectively the focal length) of the microscope is fixed. Focussing is altered by vertical movement of the microscope controlled by the foot pedal.

Figure 4.9 Set up focussing

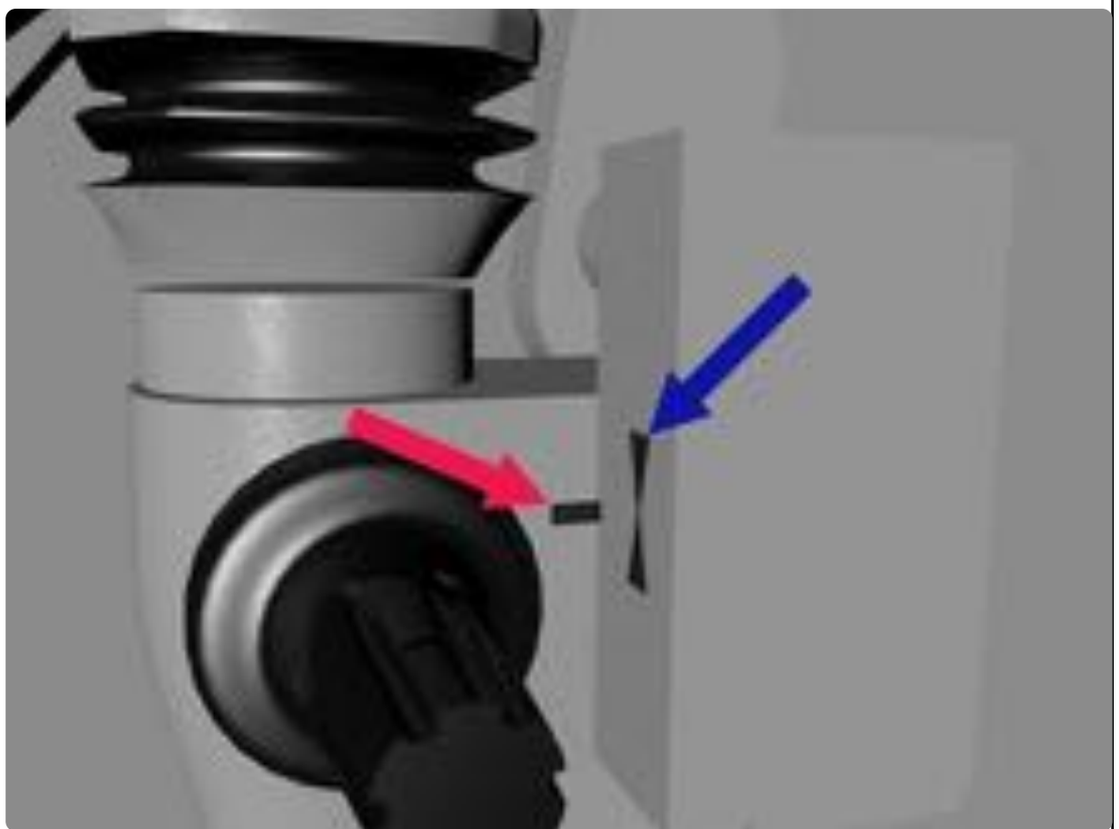

At the start of the case the microscope should be in the middle of its range of focus to avoid 'running out of focus' during the operation. There are alignment marks on the microscope to help with this. Once this has been done the microscope is manually moved, without changing its focus, so that the eye is in focus. Most microscopes have a button to reset this to zero (i.e. the midway focal point).

Types of illumination.

Par-axial illumination is not aligned with the optical path of light into the eye (i.e. the illumination is oblique with respect to the light path from the patients' to the surgeons' eye).

Co-axial illumination is more closely aligned with the path of light into the eyepieces. This produces a very intense red reflex which is useful at several stages of the operation, particularly when performing the capsulorhexis. Its' use increases the light exposure of the retina so should be minimized at

Figure 4.10 Microscope illumination

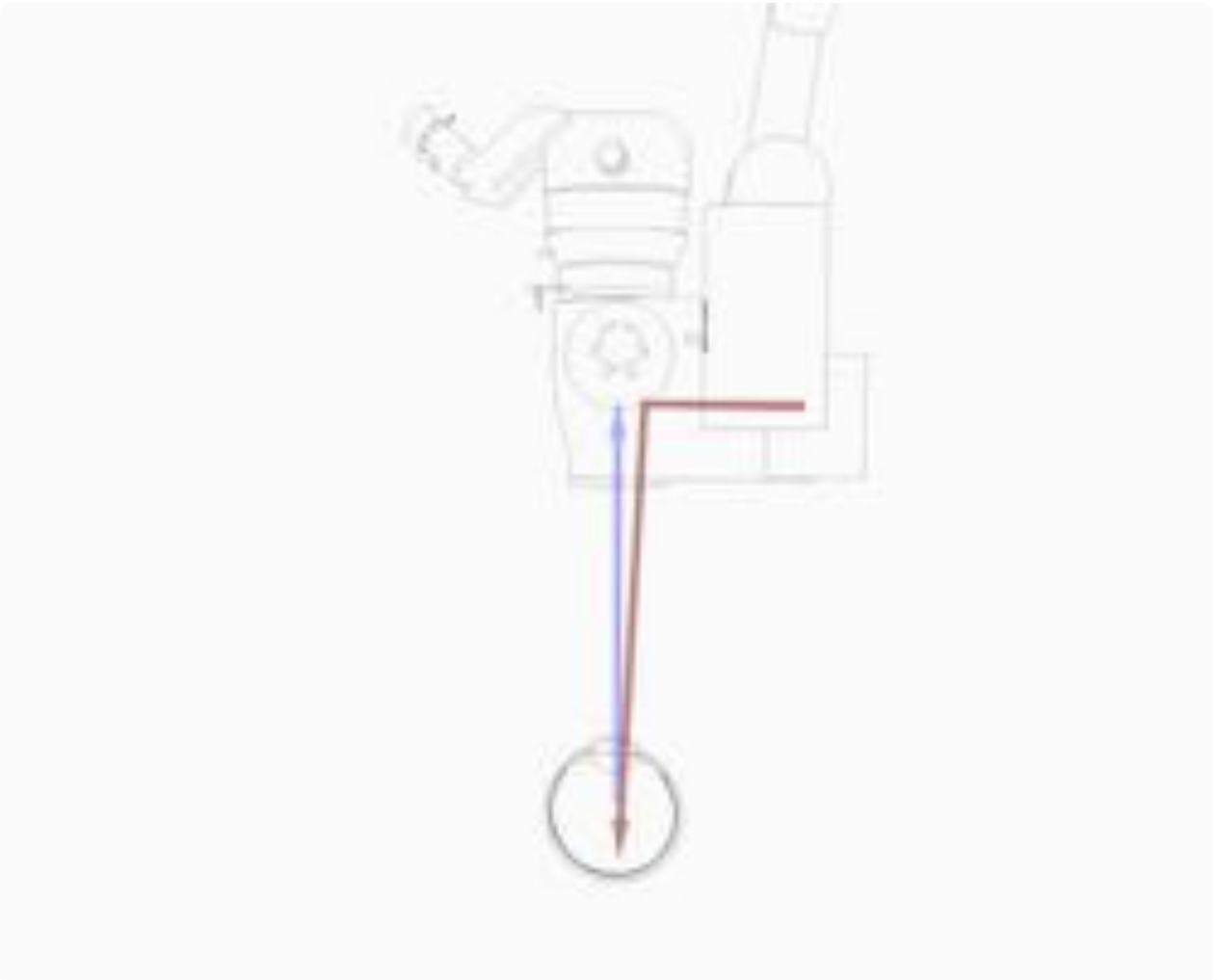

Co-axial illumination. A prism is used so that the illumination path is very close to the pat of light leaving the eye. This gives a good red reflex in the same way as someone looking directly at a camera gives rise to 'red eye' in photos.

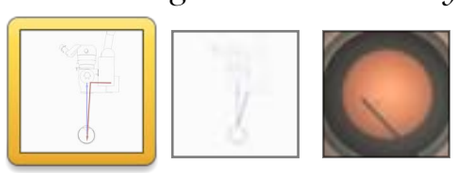

The footpedal

Several functions of the microscope are controlled by the footpedal.

The horizontal (x and y) movements are controlled by a joystick which is conventionally situated distally.

The focus and zoom are controlled by rocker switch pedals

Interactive 4.3 Footpedal controls (details may vary)

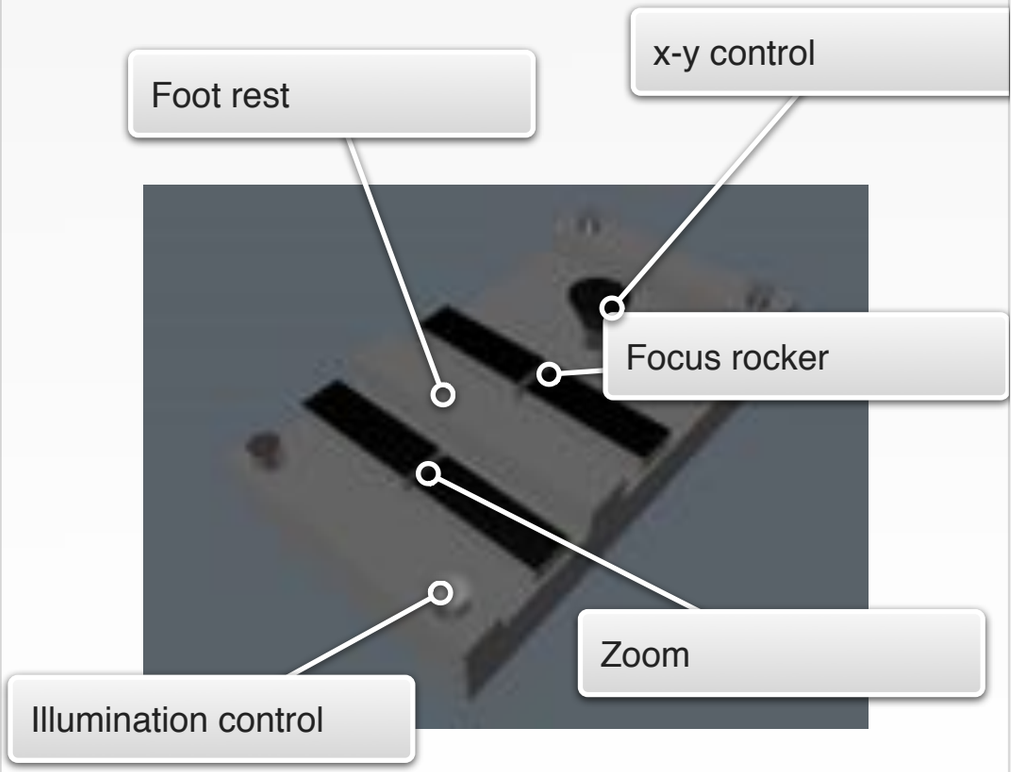

The footpedal should be positioned so that it is easily controlled, in alignment with the surgeons femur so that no significant rotation of the shin is required to operate it comfortably.

Figure 4.11 Footpedal position

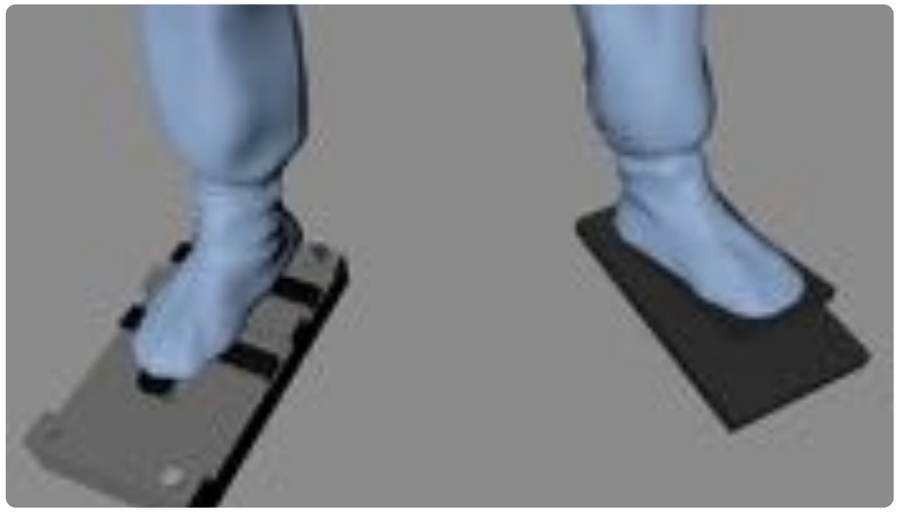

The foot pedals are correctly positioned. The foot pedals are close enough to the hips for the the soles to rest on the pedals. They are aligned with the axis of the femur. In this case it is the right foot which controls the microscope pedal - this is a matter of personal choice. The sole of the right foot rests on the foot rest and the toes can easily manipulate the x-y control. Focus and zoom are easily achieved with minor flexion and extension of the ankle.

Knowledge Review

Review 4.1 The operating microscope

Identify the features of this microscope

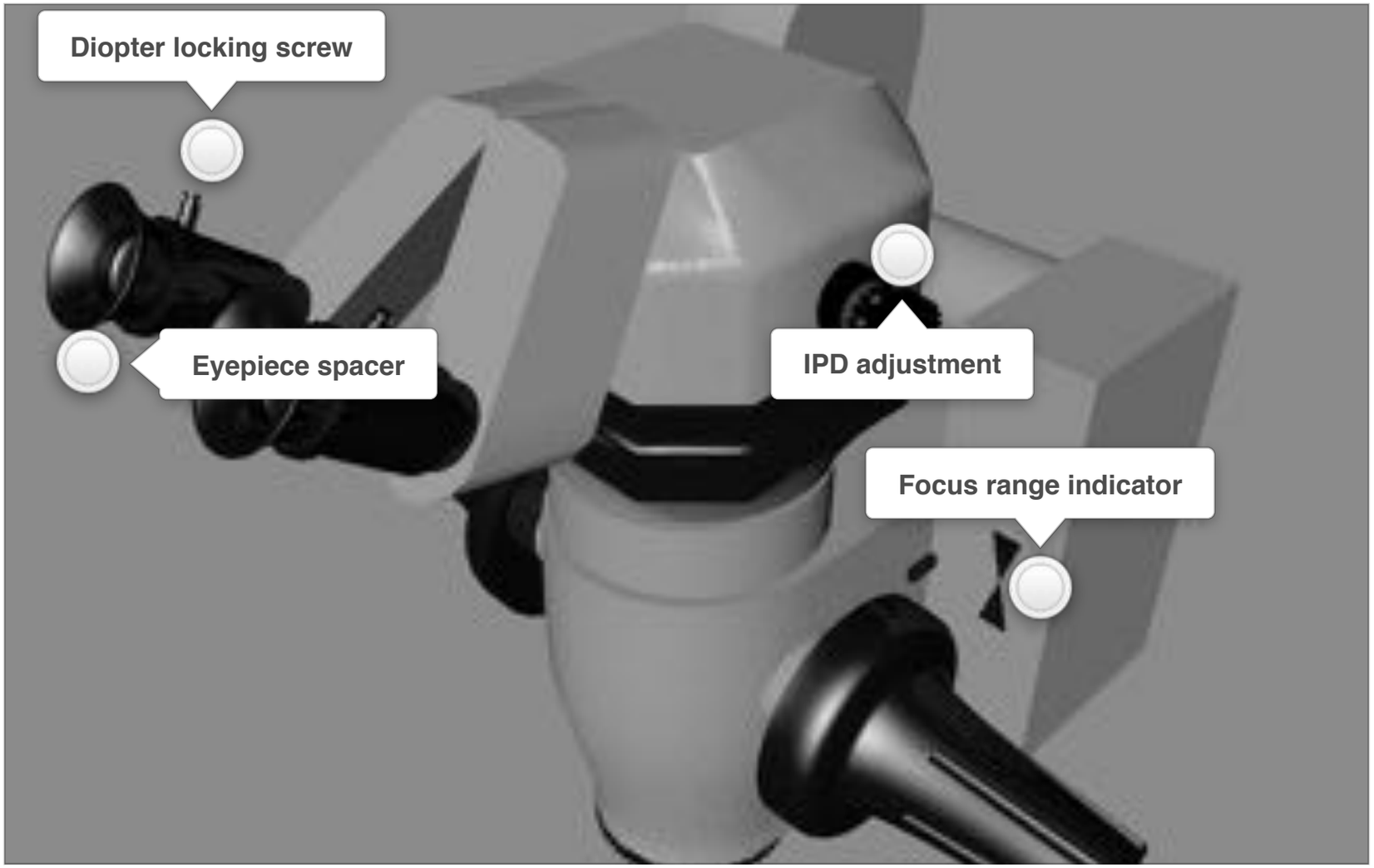

Eyepiece spacer

IPD adjustment

Diopter locking screw

Focus range indicator

Check Answer

Review 4.2 Coaxial and paraxial illumination

Which light system contributes most to the red reflex?

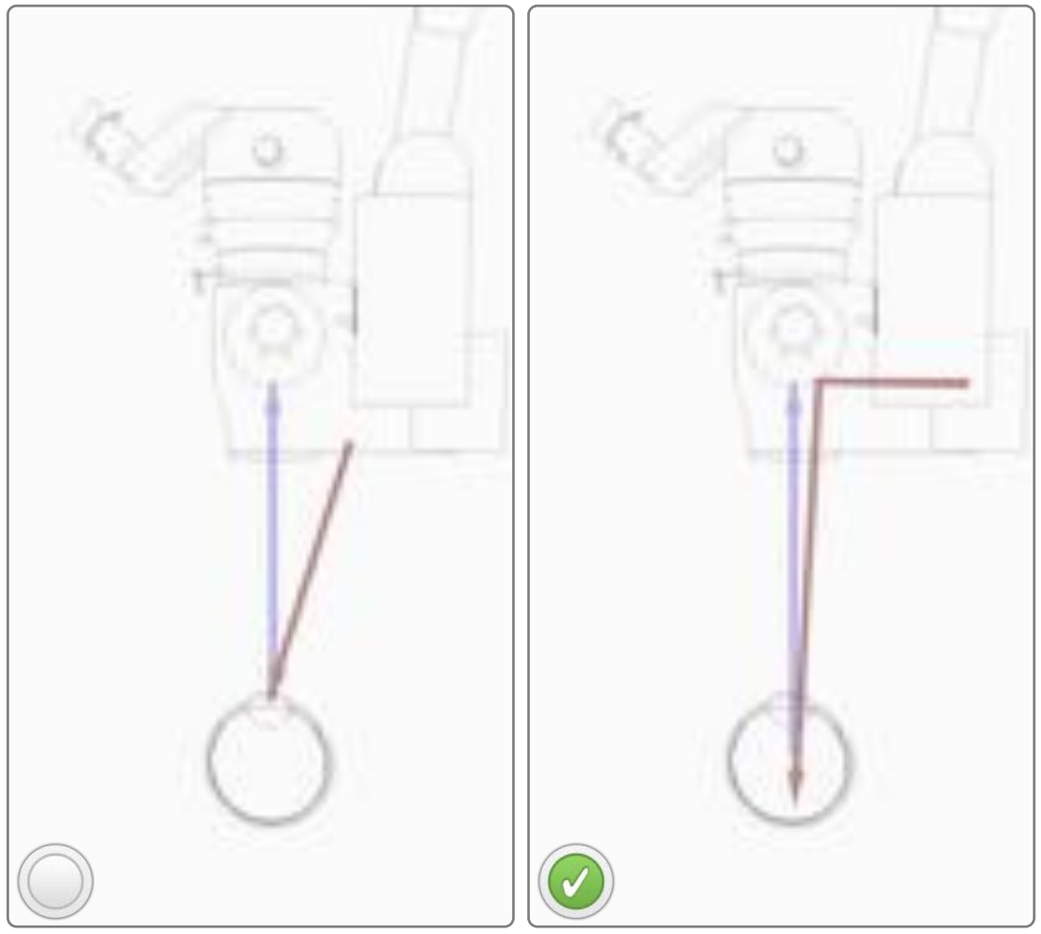

Check Answer

Review 4.3

Which diagram shows the optimum position of the foot pedals with respect to the surgeon?

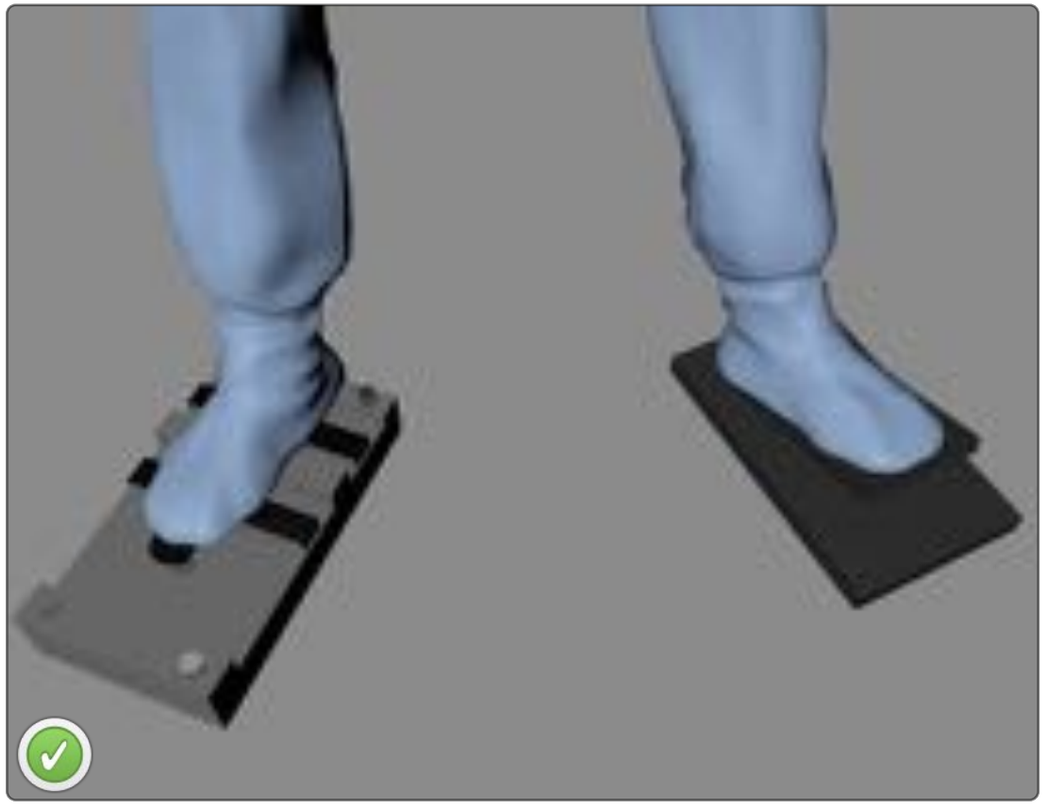

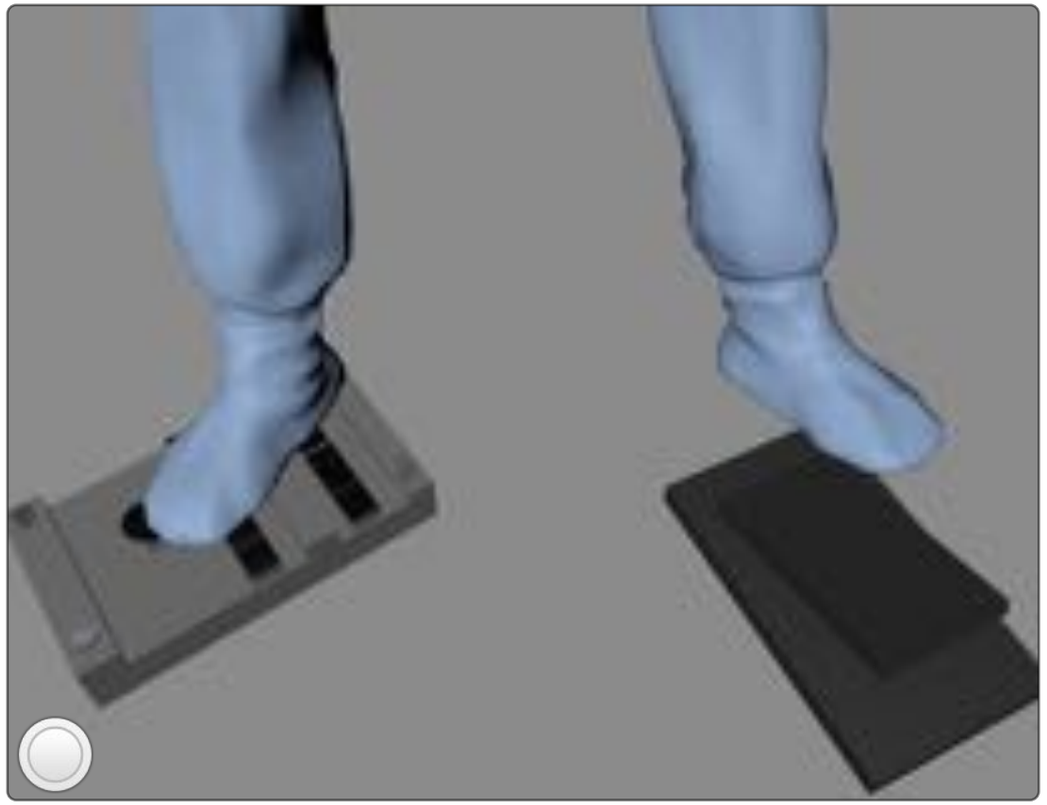

Check Answer

Review 4.4 Surgeon posture

Which diagram demonstrates a good surgical posture?

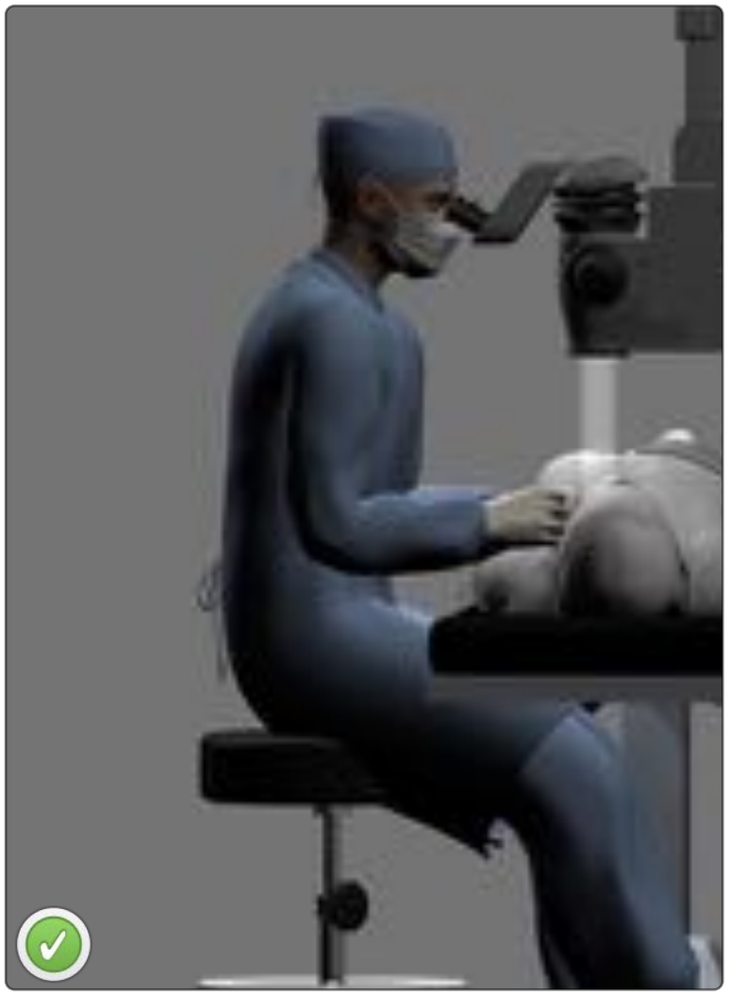

Check Answer

CHAPTER 5

The incision

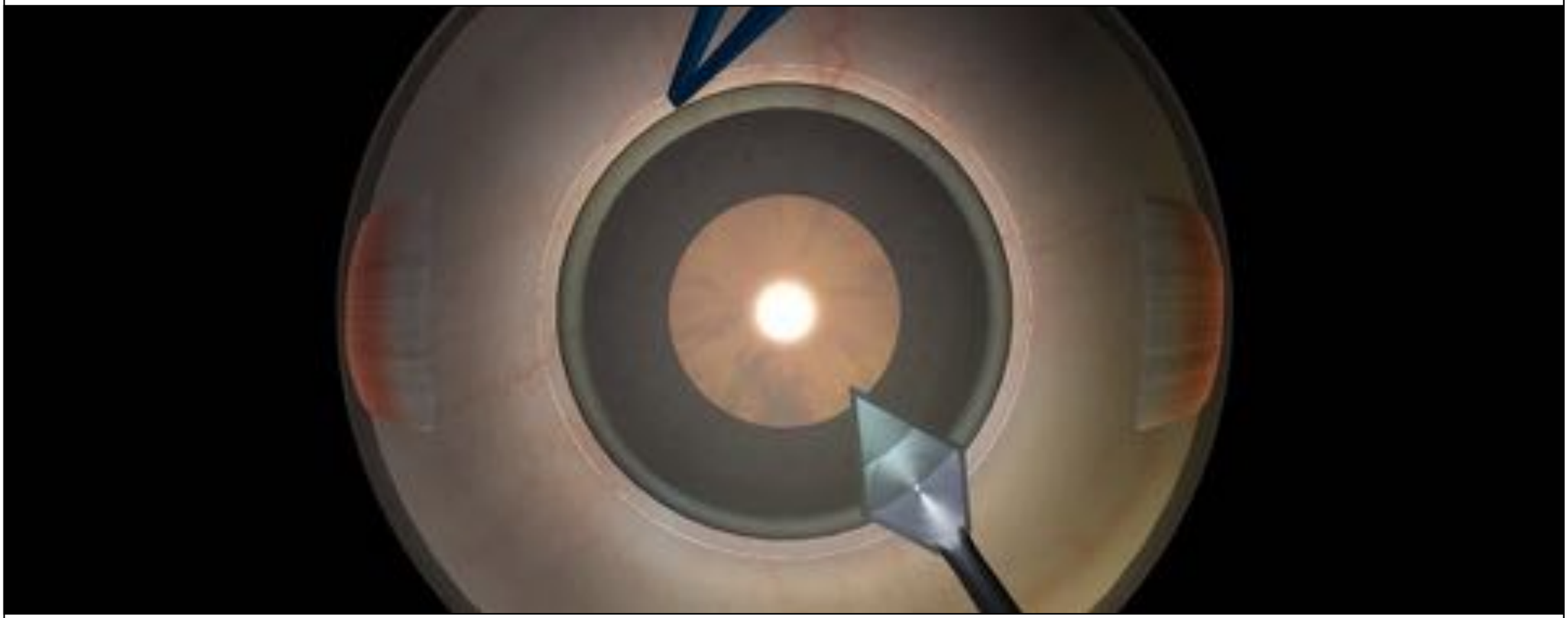

Following the development of narrow gauged instruments most phacoemulsification is performed using clear or near-clear corneal incisions. These are constructed to be watertight, self sealing and they cause minimal surgically induced astigmatism (SIA).

Surgical blades

Figure 5.1 Corneal blades



Many types of blade are available for making corneal incisions. The choice of blade design is determined by the type of incision to be created.

Figure 5.2 Surgical blades

Blades

Blades made of diamond are extremely sharp and keep their edge well. Because of their cost they are reusable and mounted in a secure protective metal handle.

Steel is more malleable than diamond and blades made of steel are noticeably less sharp. They tend to be disposable and mounted in light plastic handles.

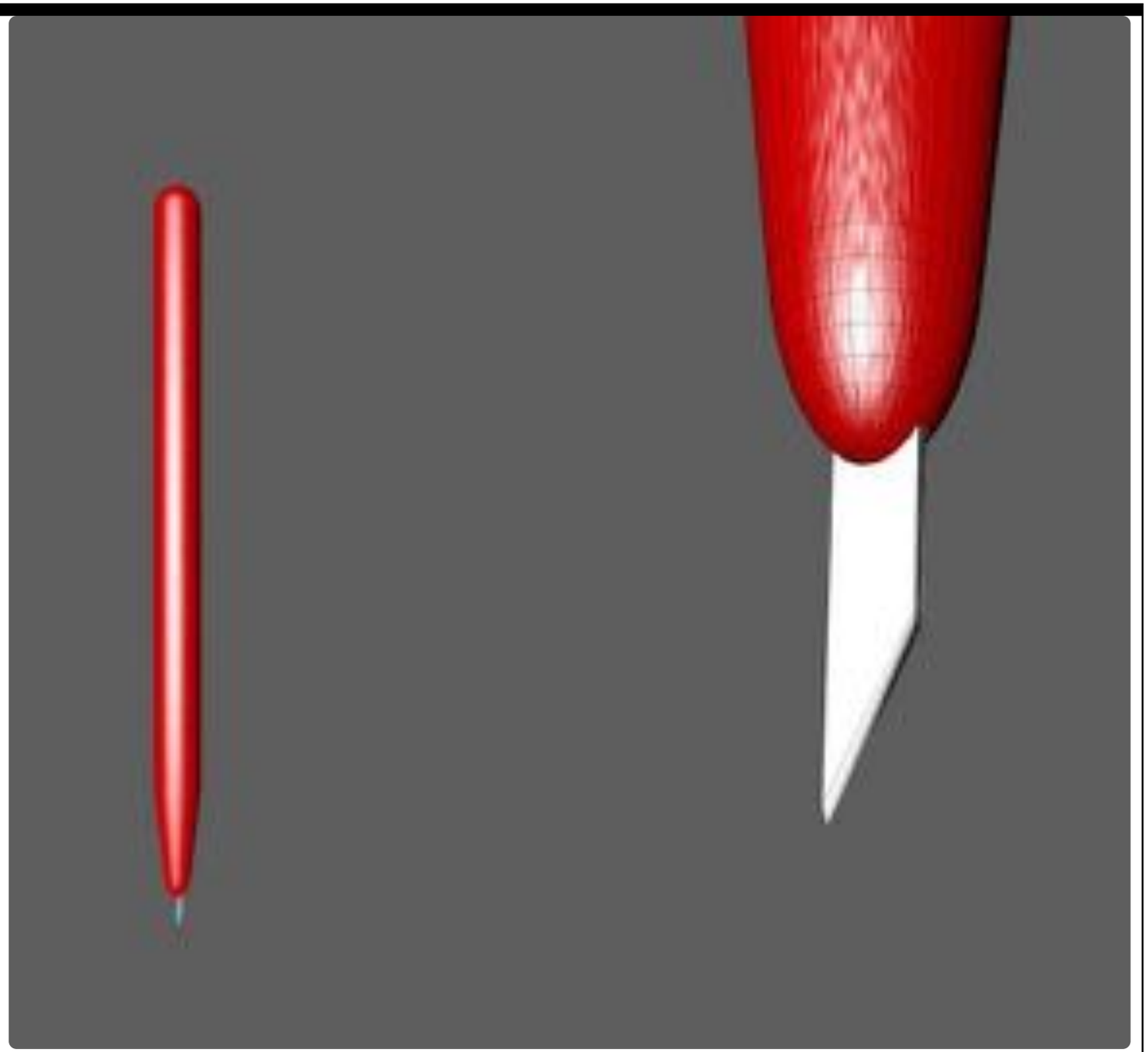

A steel 30^0 disposable blade.

General principles of wound construction

Figure 5.3 Self sealing incisions

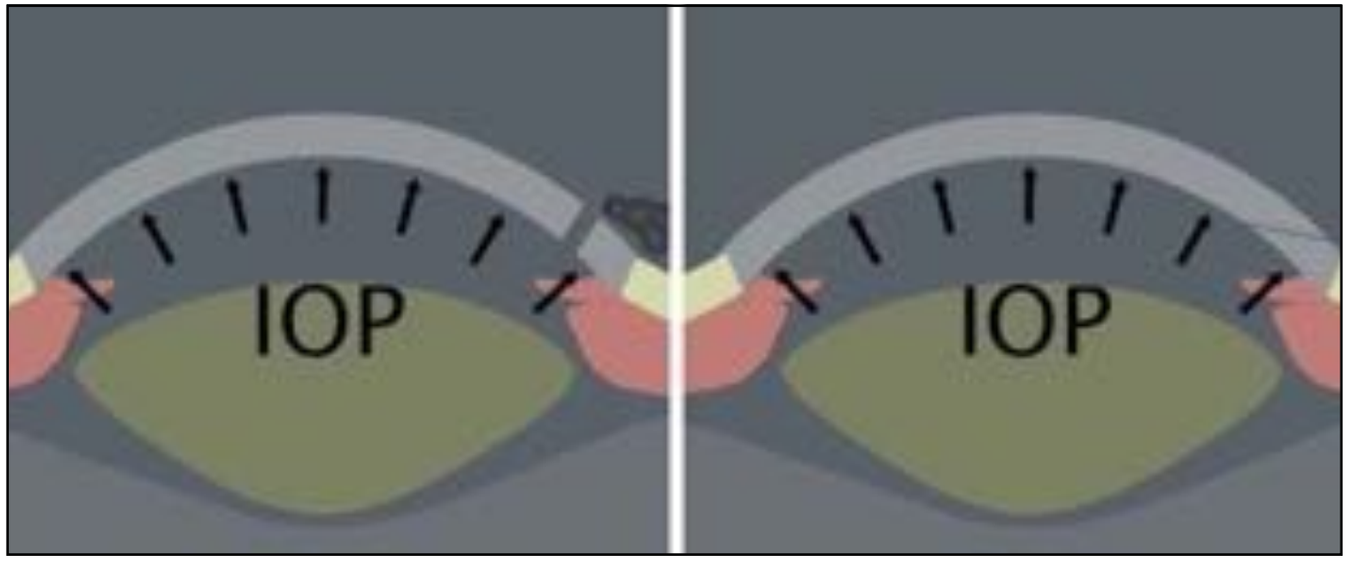

Positive intraocular pressure opens a perpendicular incision (left) to cause leakage. Conversely it closes an oblique incision (right).

A self sealing corneal incision is one which does not require sutures for wound closure.

Corneal incisions become self sealing when made obliquely rather than perpendicularly. The intraocular pressure, which causes perpendicular incisions to leak, presses the inner wall of the incision against its' outer wall.

The degree of obliquity required depends on the incision length.

Fixation of the globe

The globe should be fixated while an incision is being made. Ocular movement is minimized if the angle of the incision is aligned with the fixation point - failure to do this results in torque and a tendency for the eye to rotate.

Movie 5.1 Rotation of the globe during incision

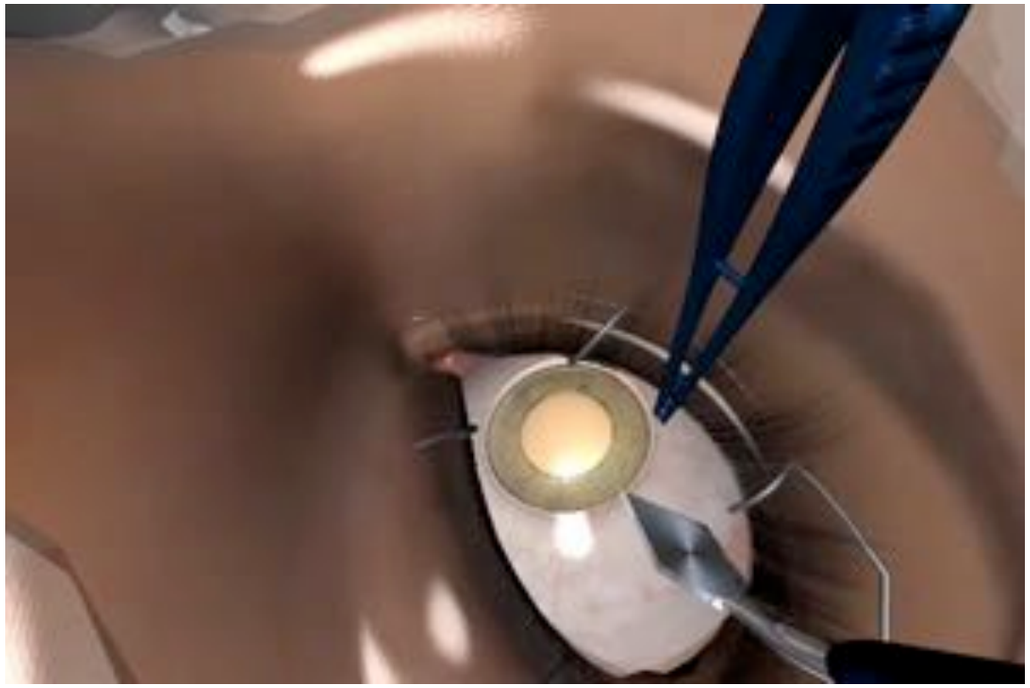

The angle of entry of the keratome is not aligned with the fixation point. The resulting torque rotates the eye.

Fixation of the globe

Firm fixation allows the surgeon to rotate the globe slightly away from the incision. The resulting control over the angle of entry is important in creating a shelved (oblique) incision.

Ways of fixating the globe include:

- Grasping the roof of a side port incision while making the main incision (this creates torque unless the blade is very sharp).
- Grasping the episclera 180^0 away from the incision site with forceps when making radial incisions (as the blade is traveling towards the forceps no torque is generated).
- Grasping the episclera adjacent to the incision site with forceps when making circumferential incisions.
- Using a Thornton fixation ring.

Figure 5.4 Fixation of the eye during incision

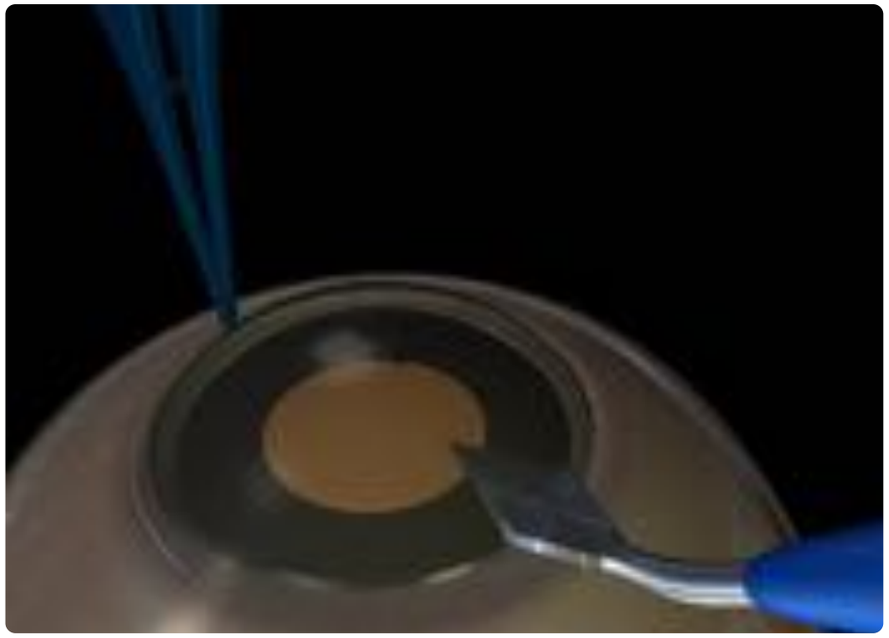

Grasping the eye with forceps while making the main incision. Here the blade is orientated towards the fixation point so no torque is generated.

Creation of corneal incisions

Figure 5.5 Scleral and corneal incisions

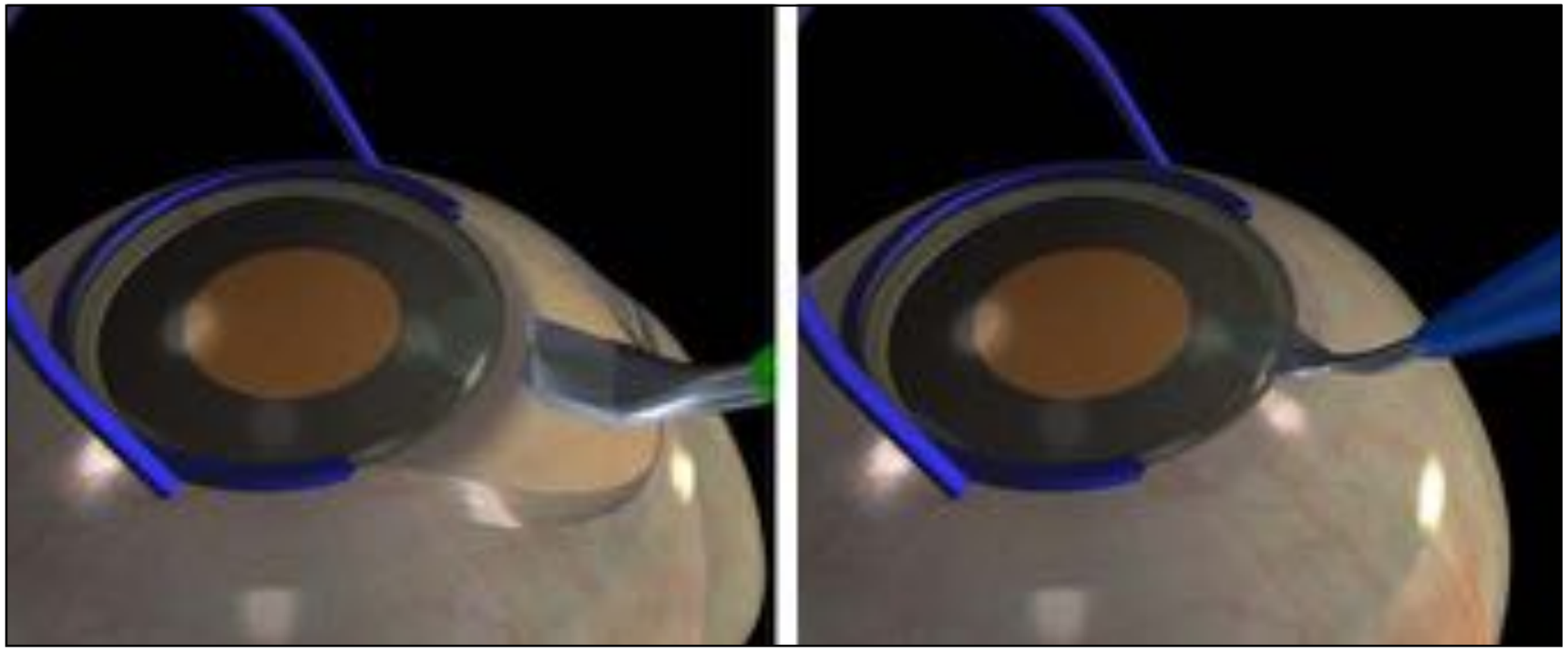

When making a corneal incision its size, location and wound profile need to be carefully considered.

Main incision and side ports

Two types of incision are needed:

- The main incision - for the phacoemulsification probe
- The side-port incision(s) - at least one to allow other instruments to be introduced.

While the exact placement of these incisions depends on the access to the globe and personal preference the meridia closest to the surgeon should be avoided.

Figure 5.6 Location of main incision and side ports

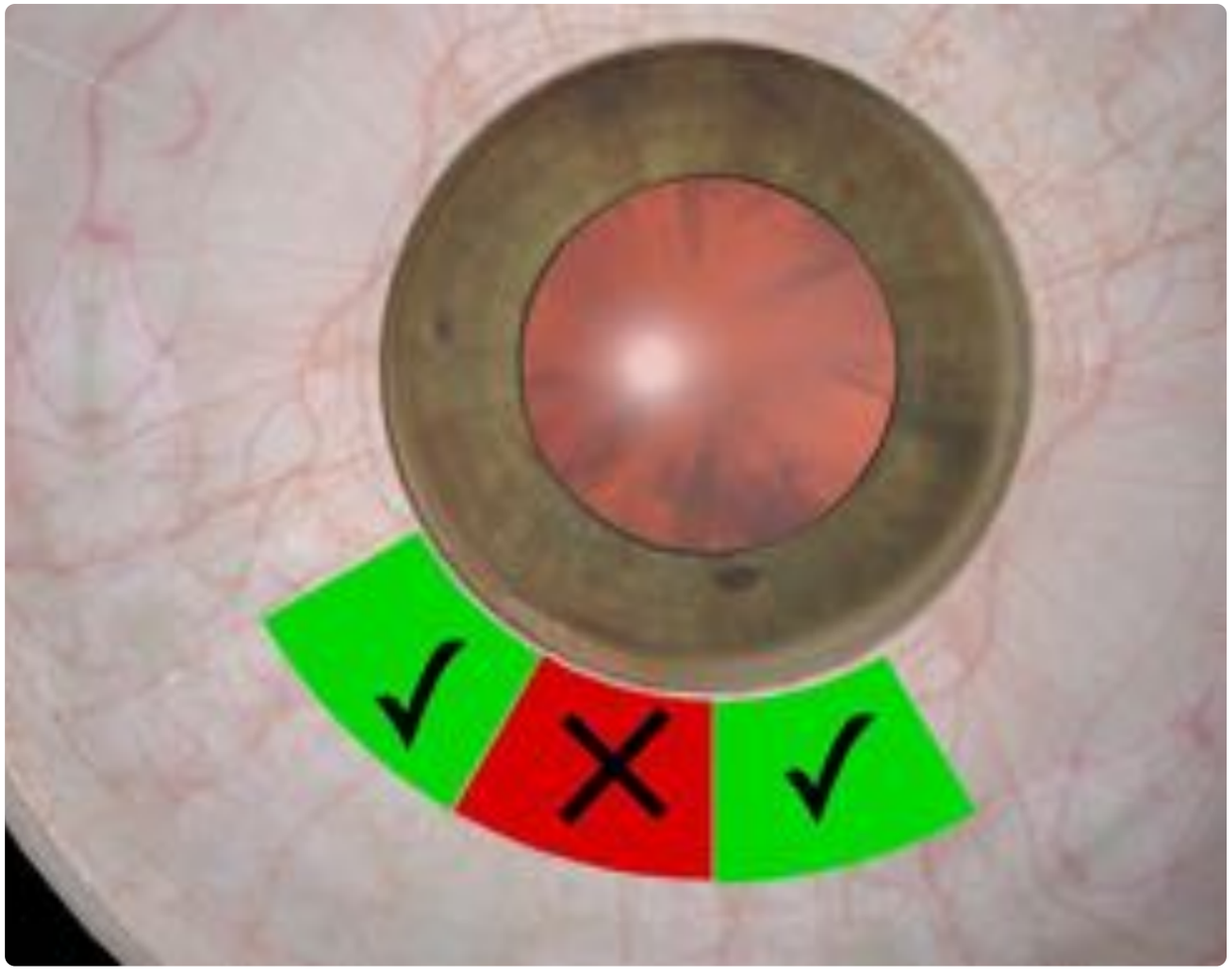

The location of the incisions for a right handed surgeon sitting. The separation of the main incision and side port is approximately 60^0. Many surgeons find the 12 o'clock meridian (with respect to the position of the surgeon) awkward for the main incision because of the angulation of the wrist required to hold the phacoemulsification probe.

Incision meridian

The surgeon may sit at the side of (temporal approach) or above (superior approach) the patients' head.

A superior approach allows the surgeons' hands to rest on the patients' head and may be more comfortable when starting surgery. As the surgeons' legs may be placed at either side of the patient there is more flexibility in determining the height of the operating table.

A temporal approach allows easier access in difficult cases (inability to extend the neck, deep set orbits) as one does not have to operate over the orbital ridge. The corneal diameter is greater horizontally so incisions may be placed further from the visual axis, inducing less astigmatism. There is less support for the hands than when operating superiorly. The operating table also must be elevated to allow the surgeons' legs to fit under it with comfortable access to the foot pedals.

Figure 5.7 Frontal and temporal approach

With a frontal approach the surgeon sits above the patient. This allows the hands to rest on the patients' forehead. Access over the brow may be difficult.

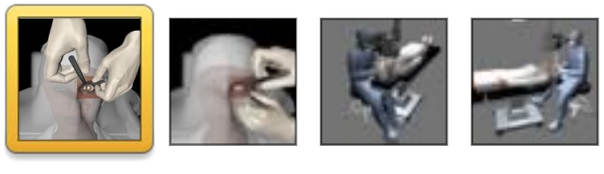

Incision zone (anteroposterior location)

Scleral incisions cause less astigmatism than corneal incisions but have many disadvantages. With the advent of smaller gauge surgery induced astigmatism is less of a concern than it used to be. Scleral incisions are less frequently used for routine phacoemulsifi-

Clear corneal incisions are made as peripheral as possible to minimize induced astigmatism.

Limbal incisions cause a little bleeding:

- Hemorrhage at the side ports is helpful in marking their site.
- Hemorrhage at the main incision may accelerate wound healing as a fibrin plug develops.

Such peripheral incisions run the risk of breaching the conjunctival insertion causing conjunctival 'ballooning' as infusion fluid accumulates in the subconjunctival space. Consequently if the surgeon wishes to perform a scleral incision then the conjunctiva must first be retracted.

Figure 5.8 Corneal and scleral incisions

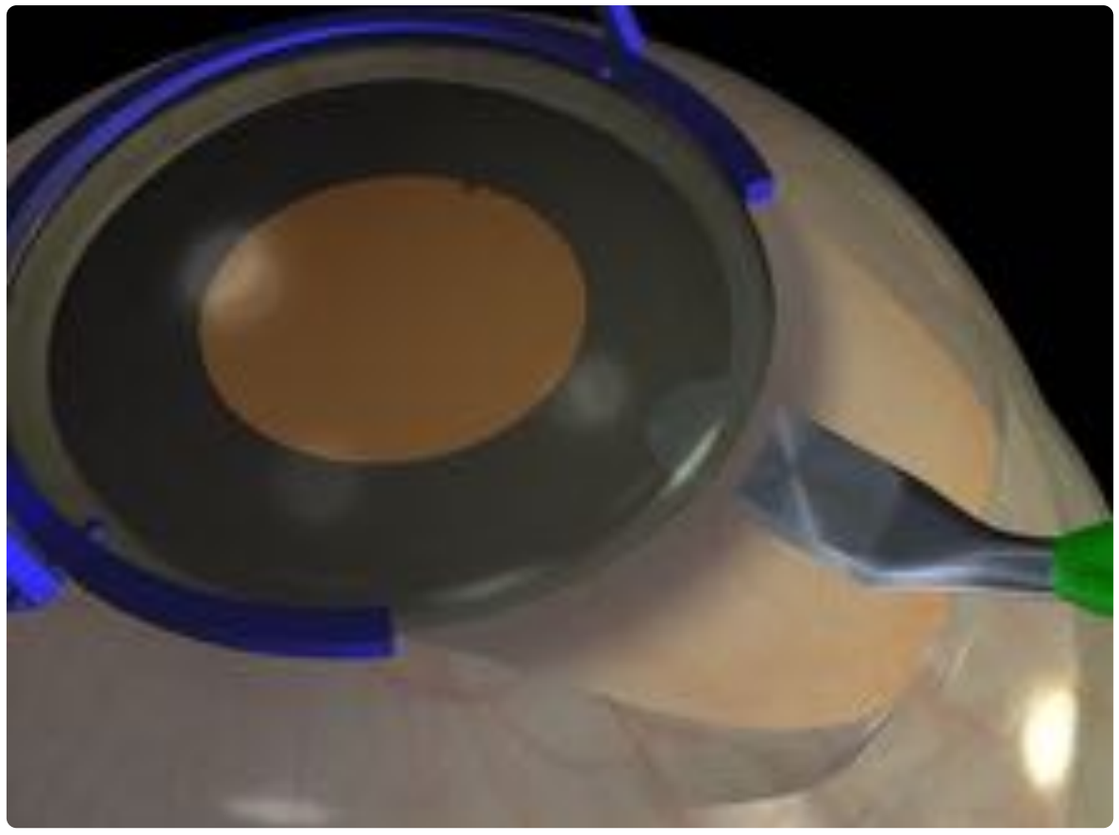

A scleral pocket. A conjunctival peritomy is performed. A triplanar incision is used. First a perpendicular partial thickness scleral incision is made. Lamellar dissection using a crescent blade creates a tunnel into clear cornea. Finally the anterior chamber is entered using a keratome.

Figure 5.9 Incision size



The keratome blade width should correspond to the diameter of the phacoemulsification probe.

Incision width

If the incision is too **narrow** then the soft infusion sleeve will be compressed onto the tip with significant reduction in irrigation flow. This is likely to cause a wound burn as the heat generated locally cannot be dissipated fast enough. If the infusion is *completely* occluded then a wound burn is *less* likely to occur because, before this can happen, the chamber will first have rapidly collapsed causing the surgeon to stop phaco immediately.

If the incision is too **wide** then leakage occurs around the probe, contributing to chamber instability. It is therefore important to use a blade of the recommended width that precisely accommodates the surgeons chosen phaco tip. Any mismatch either way will cause problems.

Incision length

Incision 'length' refers is the radial projection of the incision onto the surface of the cornea i.e. a vertical incision (perpendicular to the corneal surface) has a radial length of zero.

- The longer the incision the more likely it is to be self sealing

Incision orientation

All incisions should be radial (i.e. orientated centrally).

Movie 5.2 Long incision

If the incision is too long corneal stress lines appear with lateral or vertical excursions of the tip

Creating the side ports

The status of the side-port incisions is frequently underestimated. Although small in size their architecture in nonetheless important. In general the authors advise that they should be made at least as long or slightly longer than they are wide in order to make them easy to seal. This is because they inevitably get stretched and leak at the end of surgery more so than the main wound because the instruments that pass

The importance of location and fixation has already been discussed. Using a fixed width blade gives unerring accuracy leaving little to chance. A narrow blade such as a 15° or 20G MVR blade is used. The angle of the incision is flat (parallel to the iris plane). Aim the blade towards the diametrically opposite point.

Viscoelastic-aqueous exchange

Following the creation of the first side port the anterior chamber may be filled with viscoelastic to ensure that it is firm for the next step.

Movie 5.3 Paracentesis with an MVR blade

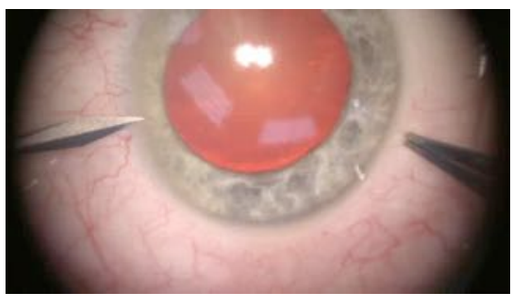

The fixation point is less than 180⁰ from the incision - as the blade is sharp the eye does not rotate.

Movie 5.4 Overlarge paracentesis

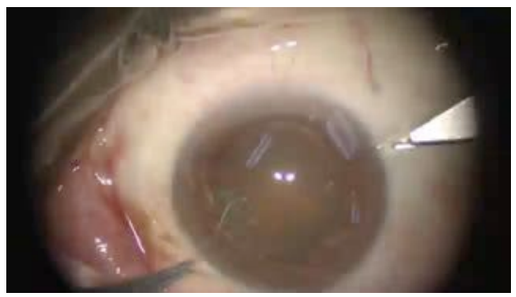

Use of an angled blade creates a funnel wound profile which allows lateral excursions of the chopper. It is important not to advance the blade too far into the anterior chamber (as happened in this case) in order to create a self sealing wound which does not leak during phacoemulsification.

Movie 5.5 Viscoelastic exchange

Note that the cannula is advanced before injecting to enable back-filling of the anterior chamber with viscoelastic which displaces he aqueous out of the eye via the side port. This leaves no trapped lacunae of aqueous.

Main incision profiles

The incision may be uni-, bi- or triplanar.

Whichever incision configuration is used the eye should be firm and fixated.

Figure 5.10 Incision profiles



Uni-planar, bi-planar and triplanar incisions.

Uni-planar incision

A uniplanar incision may be created by :

- With the eye in a neutral position placing the tip of the blade flat against the cornea and then dropping the wrist slightly so that the blade enters the cornea at a slight upward angle.

OR

- Rotating the eye slightly away and then advancing the blade horizontally into the cornea. Due to the position of the eye this creates an angled entry determined by the degree of rotation of the eye.

Although the aim is to create a flat incision profile, in vivo optical coherence tomography studies have shown that the resulting incision profile is often arcuate rather than uniplanar. This may increase the self sealing properties of the incision.

The uniplanar incision is easy to create and, provided it is long enough, usually self sealing. It is difficult to extend (although this is seldom necessary) and the thin posterior edge of the roof is vulnerable to tearing.

Figure 5.11 Uniplanar incisions

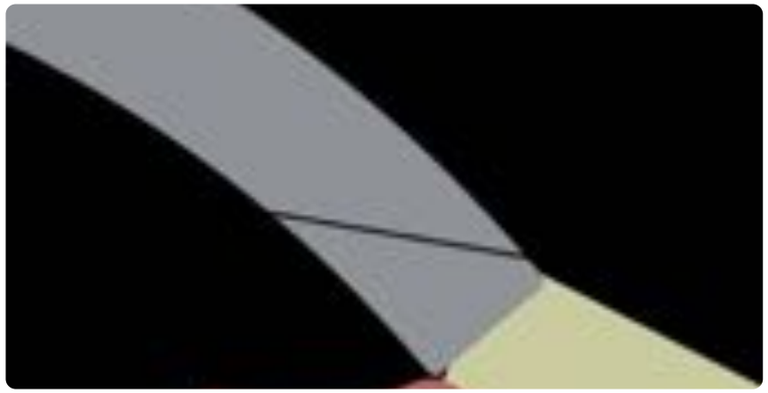

The (theoretical) uniplanar incision profile

Movie 5.6 Uniplanar or triplanar incision?

Frequently when surgeons aim to make a uniplanar incision small deviations in the angle of the keratome alter the incision profile. At first sight this looks like a stab incision. Examined closely the blade enters the incision a little steeply, pivots to a flatter plane and then steepens again to enter the anterior chamber. These movements are quite subtle - look at the part of the blade outside the eye to appreciate them. This is probably the cause of the arcuate profile seen on OCT imaging. Note the mark on the keratome set at 2 mm to help judge incision length.

The angle of entry to the anterior chamber

The angle at which the keratome enters the anterior chamber is important because it influences the shape of the wound and therefore its' self sealing properties.

If the keratome enters the anterior chamber horizontally the incision will have the ideal square profile.

If the angle of entry is too deep or shallow a non square incision with inferior self sealing properties is produced.

Illustration 5.1 The angle of entry to the anterior chamber



The correct angle of entry produces a square incision shape (left). A steep angle of entry (centre) and shallow angle of entry (right) have inferior self sealing properties.

Bi-planar incision

Laboratory and cadaver studies using microspheres have shown that a grooved incision seals better than a non-grooved one. An initial vertical groove is made in the cornea to about 300 μm. A guarded blade may be used to ensure this is at the correct depth. Alternatively a 30^0 blade, an MVR blade or the edge of the keratome (less easy to control) may be used. The keratome is then used in the bed of the vertical incision to make the lamellar incision. This incision should extend for 2 - 2.5 mm before entering the anterior chamber. As this incision is initiated deeper in the cornea than a uni-planar incision the angle must be flatter with respect to the corneal surface or the blade may prematurely enter the anterior chamber.

Many surgeons have abandoned this technique, or use a very shallow vertical incision, as a deep vertical incision may attract mucus and be transiently uncomfortable for the patient. Nonetheless its self-sealing reliability is beyond question.

Figure 5.12 Bi-planar incision profile

Movie 5.7 A bi-planar incision

Triplanar incisions

This is similar to a bi-planar incision. The lamellar incision is flatter (parallel with the corneal lamellae) and is followed by a marked downward angulation of the blade to enter the anterior chamber. A dimple appears as the blade is angled down due to indentation of the corneal surface.

Movie 5.8 A 3-step incision

Note the dimple in the cornea when the blade is angled down to enter the anterior chamber.

Figure 5.13 Triplanar incisions

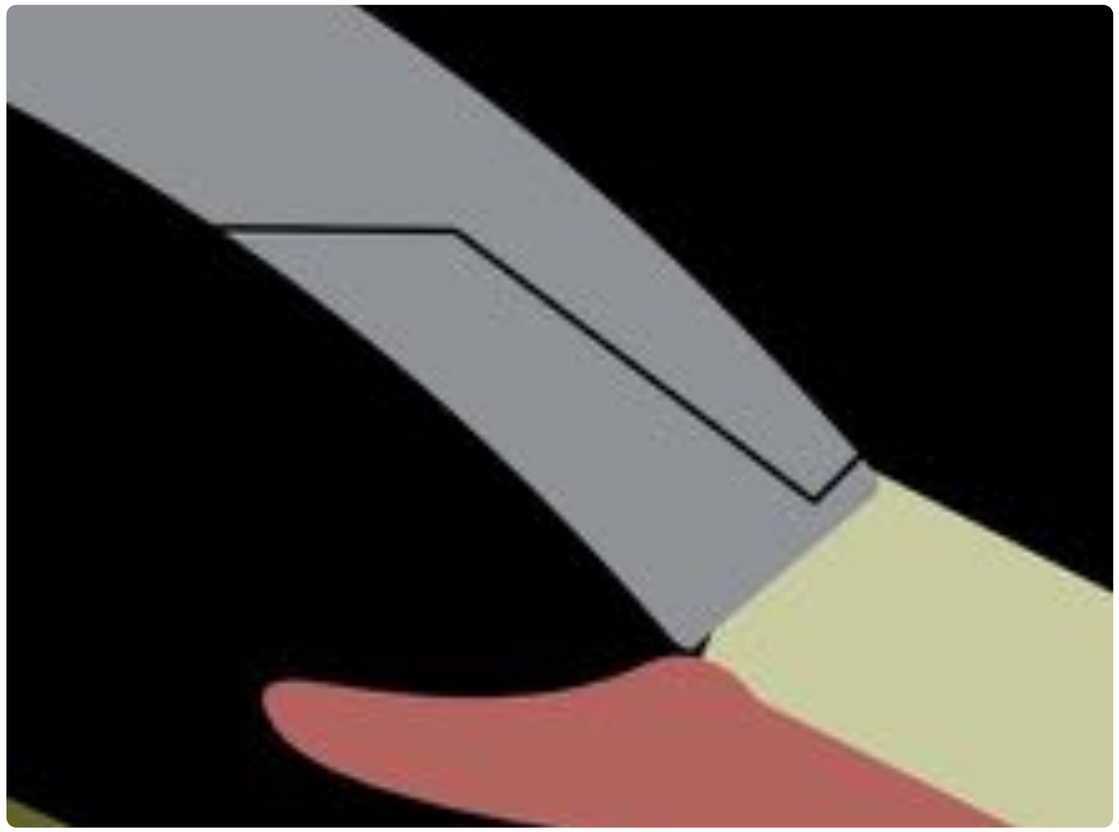

The profile of a triplanar incision.

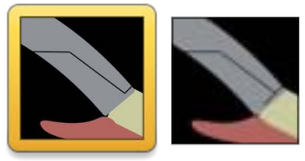

Complications of incisions

Figure 5.14 Errors and complications; "The Rule of Too's"

ERROR	COMPLICATION
Too long	corneal distortion, oar-locking, corneal oedema
Too short	iris prolapse, wound leak & chamber instability, endophthalmitis
Too central	astigmatism, corneal striae, difficult subincisional capsulorhexis
Too peripheral	conjunctival ballooning
Too wide	wound leak & chamber instability
Too narrow	wound burn

Iris prolapse - cause

Iris prolapse from the main incision occurs when it is too short and peripheral because, under these conditions, the inner opening of the incision is approaching the iridocorneal angle and thereby very close to the iris. Iris may similarly also prolapse out of the side ports if they are too short and peripheral. The risk of iris prolapse through any wound is exacerbated if it is too wide, and therefore leaky with a high flow rate of irrigation fluid.

Movie 5.9 Iris prolapse due to a short incision.

The thin arrow shows where the keratome enters the anterior chamber. The thick arrow shows the mark on the keratome which guides the point at which the keratome should enter the anterior chamber. The incision is about 1 mm too short.

Illustration 5.2 Mechanism of iris prolapse

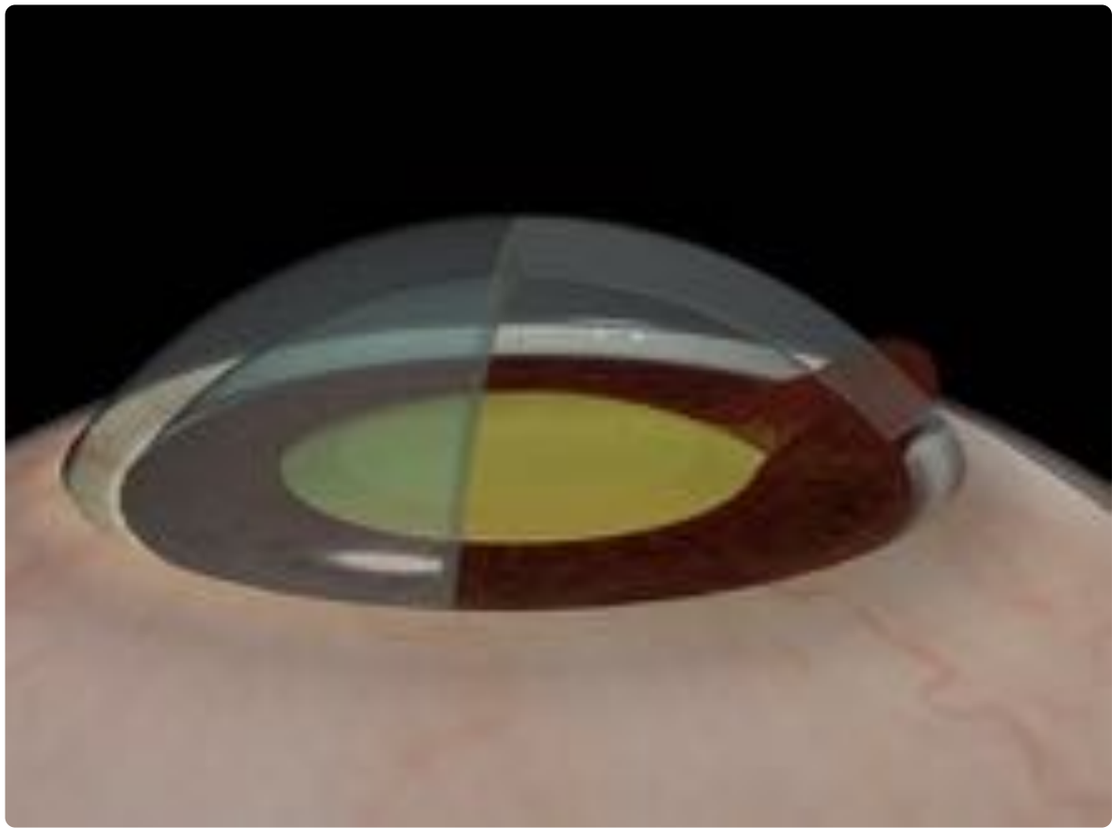

This cutaway shows the mechanism of iris prolapse - a poorly constructed incision (too short) which is also peripheral so that the inner ostium of the incision is adjacent to the iris root.

Iris prolapse - management

Any prolapsed knuckle of iris is best managed by first stopping irrigation to lower the intraocular pressure and then decompressing it with a small radial iridotomy. Now the iris can be gently reposited from within using a blunt spatula. This is often easier to achieve if the instrument is introduced through a separate wound.

Forceful reposition should be avoided as it may lead to tears and sphincter rupture. This mechanical stimulation also leads to pupil shut-down. If the iris does not respond to gentle attempts to reposit it a small linear iridotomy (with micro-scissors) may help, as it releases the bubble of fluid trapped in the prolapsed knuckle of iris.

If prolapse is severe or recurrent it is best to close the wound and create a fresh incision elsewhere, as repeated reposition may lead to pupil constriction.

The wound should be sutured at the end of the case. Miochol may be helpful in restoring some tone to the sphincter pupillae, facilitating final disengagement of any residual iris incarcerated in the wound.

Figure 5.15 Iris prolapse management

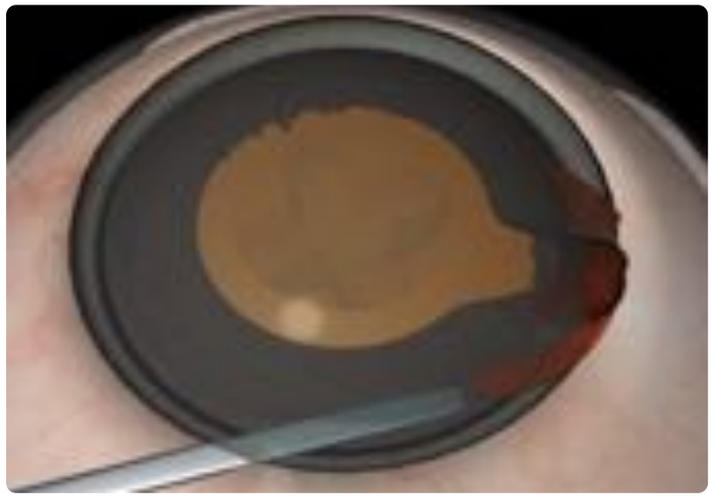

Some fluid having been released from the anterior chamber, the iris is gently reposited using an instrument through a side port.

Movie 5.10 Linear iridotomy and repositing prolapsed iris via a side port.

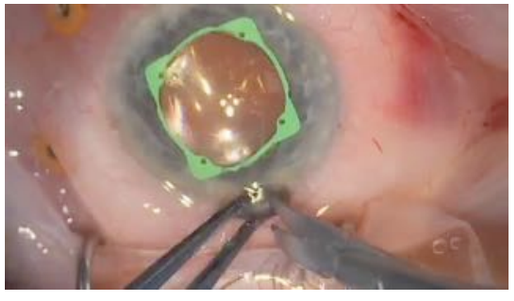

This large prolapse occurred after inserting vitrectomy trochars.

Movie 5.11 Iris repositing through a side port.

Notice how easily this is achieved after releasing fluid from the anterior chamber to soften the eye - overinflation with viscoelastic is counterproductive.

Iris prolapse - Intraocular Floppy Iris Syndrome (IFIS)

Various alpha-receptor antagonists, particularly tamsolusin, may cause the iris to become very flaccid - Intraocular Floppy Iris Syndrome (IFIS).

IFIS limits pupil mydriasis and the toneless iris billows during surgery and is particularly likely to prolapse.

Iris prolapse in the presence of IFIS can occur even through correctly sized and positioned wounds in which case a single iris hook can be placed just posterior to the incision to retract the local sector of offending iris.

Intraocular phenylephrine is highly effective in preventing IFIS. Severe cases may not respond in which case iris hooks may be used.

Movie 5.12 Severe IFIS

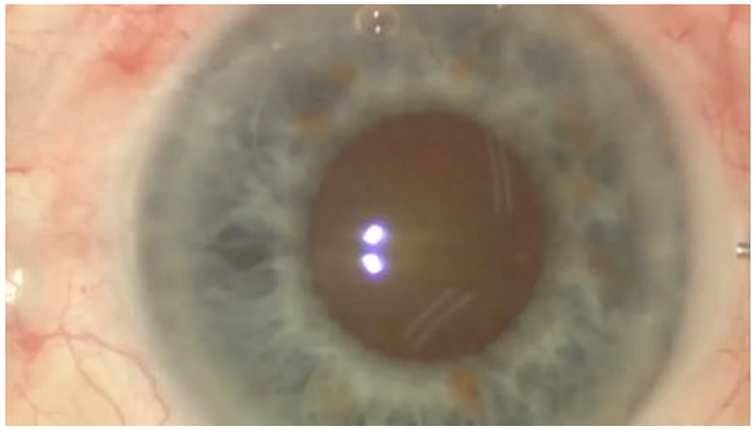

This case did not respond to intraocular phenylephrine so iris hooks were inserted. Note the use of an additional subincisional hook.

Astigmatism

Figure 5.16 The optics of astigmatism

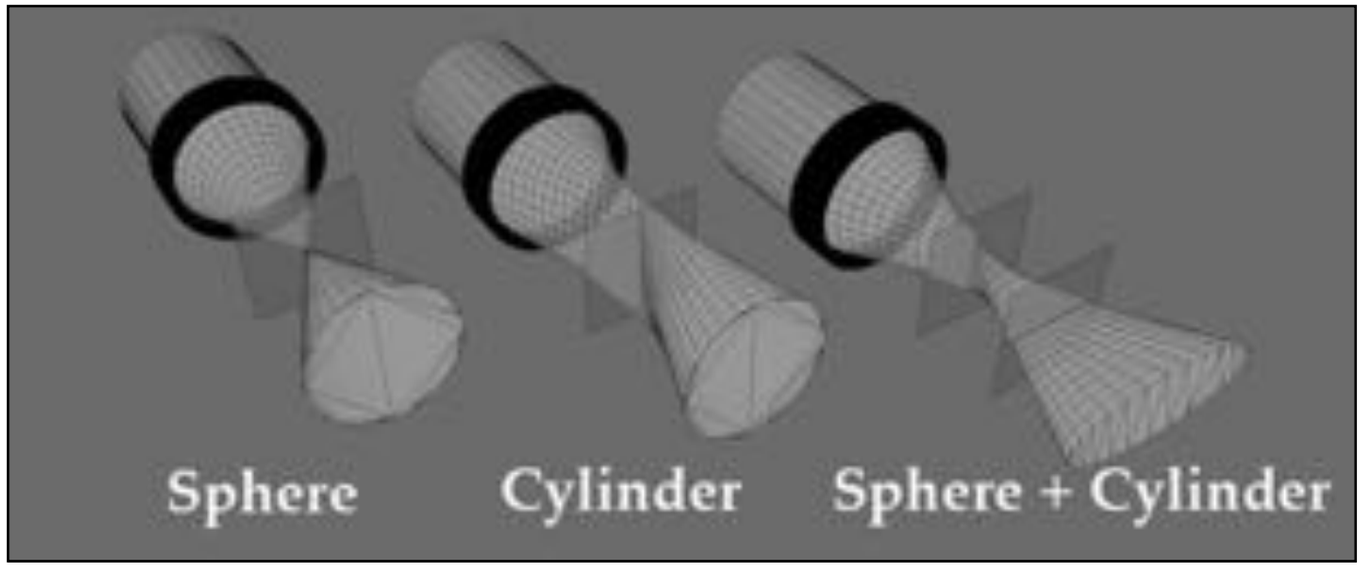

The optics of astigmatism

The greek word a ("not") and stigma ("a spot") refers to the product of refraction through a lens which is not simply spherical.

In the diagram above the image on the left shows the refraction of parallel light rays through a spherical lens. These rays are brought to a sharp focus at a single spot.

In the image on the right the lens has a combined spherical and cylindrical profile. In this case the astigmatism is regular (i.e. the focal power is different in 2 different planes at right angles to each other). The light is brought to a focus in 2 planes (one horizontal and one vertical). In both of these the focus is linear, not a single spot. The area in between is know as Sturms' Conoid.

Corneal astigmatism

A cornea with no astigmatism has a spherical profile (rather like a section of a soccer ball).

A cornea with astigmatism has different curvature in different axes (like a section of an American football or rugby ball). Most physiological astigmatism is regular (i.e. the two meridia are 90^0 apart). The steeper meridian (with the most refractive power) is usually vertical (in fact this is so common it is termed 'with the rule'). The meridian with the smaller radius of curvature is termed the steep meridian while that with the larger radius of curvature is the flat meridian.

Figure 5.17 Sphere vs spherocylinder



A regular spherical cornea is like a section of a soccer ball while a cornea with astigmatism is like a section of an American football.

Interactive 5.1 Steep and flat meridia

Spin this interactive image to see the steep and flat axes.

Meridian and axis

When describing the orientation of a cylindrical lens the terms meridian and axis are sometimes used as though they were interchangeable. This is not the case. The axis of a cylinder is at 90^0 to its' meridian. This is particularly important when describing the use of incisions to neutralize astigmatism. If an incision is made to flatten the cornea it is made 'on meridian' not 'on axis'.

To avoid confusion the term 'meridian' is preferred in this book. This describes the orientation of maximum curvature of the cylindrical lens.

Confusion arises because optometrists usually describe the orientation of a cylinder in terms of its' axis. This is compounded by the fact that in order to optically neutralize a convex cylindrical aberration in the eye one can employ either a concave prism with the same orientation or a convex prism orientated at 90^0 to the aberration of the eye (with an adjustment to the spherical

Figure 5.18 Meridian and axis of a cylindrical lens



The meridian is at 90^0 to the axis.

Assessment of astigmatism

While the astigmatism of the eye as a whole may be assessed by refraction, the degree of corneal astigmatism alone is assessed by studying specular reflections from its surface.

A simple way of doing this is to study the reflection of a ring. A spherical corneal surface produces a circular ring. In the presence of astigmatism this becomes more ovoid. If the reflections from a concentric array of rings is studied their image appears to become closer in the steeper meridian.

Figure 5.19 Assessment of astigmatism



A Placido disc.

Surgically induced astigmatism

Corneal incisions cause flattening of the cornea in the meridian of the incision. There is corresponding steepening in the meridian at 90^0 to this so that the overall refracting power of the cornea is unchanged. This phenomenon is termed 'coupling'.

Conversely tight sutures cause steepening. There is corresponding flattening in the meridian at 90^0 to this.

Movie 5.13 Corneal incision and flattening

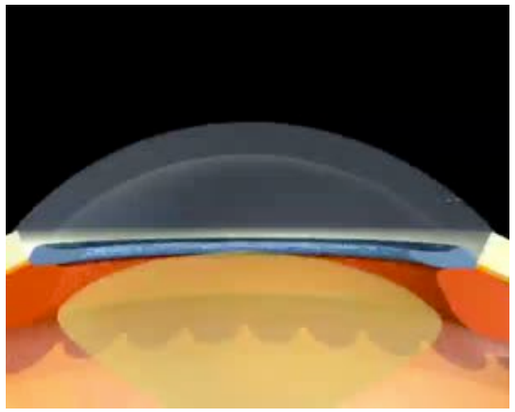

Movie 5.14 Effect of corneal incision on astigmatism - note the coupling

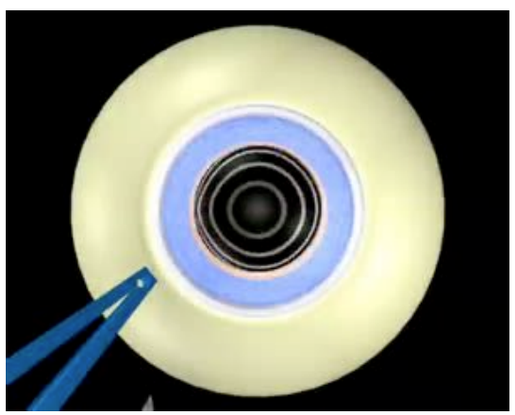

Movie 5.15 Corneal suture and steepening

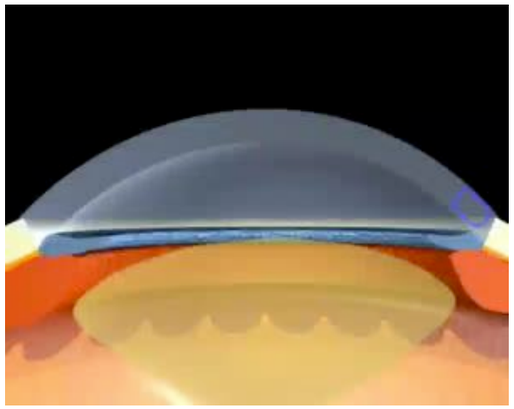

Movie 5.16 Effect of corneal suture on astigmatism - note the coupling

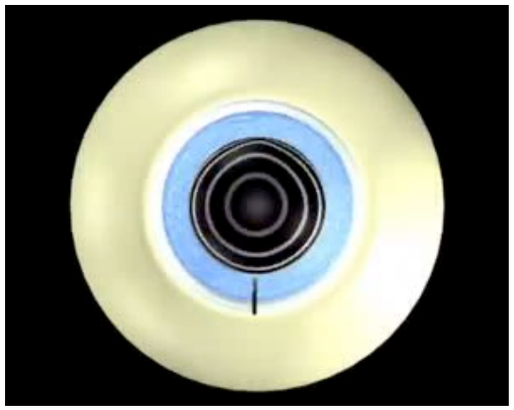

Reducing surgically induced astigmatism

The degree of astigmatism induced by an incision is proportional to the:

- Size of the incision
- Location of the incision (the closer to the visual axis the greater the induced astigmatism)
- Depth of the incision
- Tension in sutures (if present)

Pre-existing astigmatism may be reduced by making an incision in the steep meridian ('on-meridian surgery' although it is often described incorrectly as 'on-axis' surgery).

Knowledge Review

Movie 5.17 Video review 1

Look at this video.

What error has been made during the construction of the incision?

Scroll down for the answer.

Review 5.1 Astigmatism

Where is the tight corneal suture in this eye?

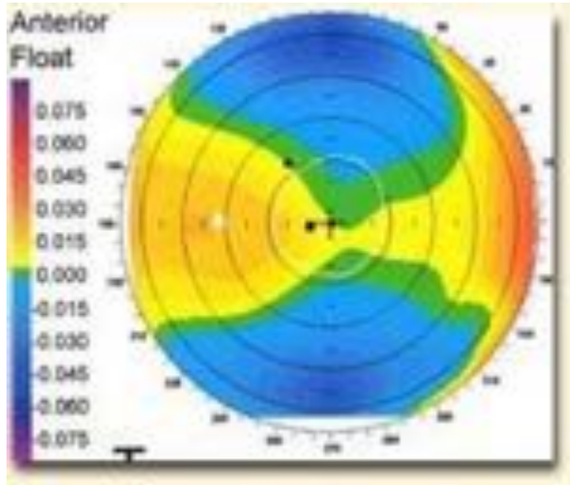

- **A.** 12 o'clock
- **B.** 3 o'clock
- **C.** 4 o'clock
- **D.** 6 o'clock

Check Answer

Movie 5.18 Movie review 2

Look at this video.

What error has been made during the construction of the side port?

Scroll down for the answer.

Movie 5.19 Video review 3

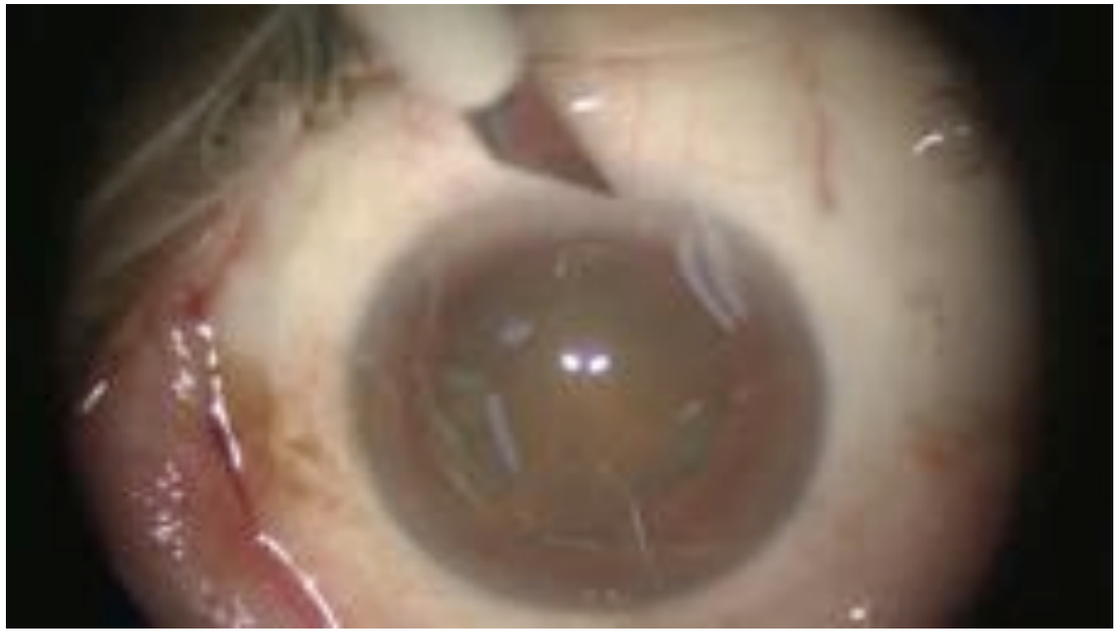

Look at this video.

Why does the eye move when the first step of this triplanar incision is made?

Scroll down for the answer.

Review 5.2 Incision construction

This surgeon has not advanced the full width of the keratome into the anterior chamber (the image shows the maximum point of advance). Which of the following is NOT true?

- ✓ **A.** This is quite acceptable as it gives excellent self sealing.
- **B.** This increases the risk of wound burn as the infusion sleeve on the phacoemulsification probe will be squeezed.
- **C.** This increases the risk of stripping Descemets membrane due to the force required to insert instruments into the eye.

Check Answer

Review 5.3 The angle of entry

Look at this corneal incision. The angle of entry of the keratome into the anterior chamber was:

- **A.** Too shallow
- **B.** About right
- ✓ **C.** Too steep
- **D.** Impossible to comment

Check Answer

CHAPTER 6

Capsulorhexis

Correct capsulorhexis is the most important single step in phacoemulsification. An imperfect incision can be re-made. Unsuccessful hydrodissection may be repeated. If one technique for quadrant removal is unsuccessful another can be employed. An incorrect or damaged intraocular lens may be exchanged. A leaking incision can be sutured. Capsulorhexis affects all subsequent steps of the operation and is essentially irreversible*.

* There are steps that may be taken to correct the rhexis but all require its' enlargement in some way.

Capsulorhexis instruments

Figure 6.1 Capsulorhexis instruments

A surgeon-bent needle, a pre-bent cystotome, coaxial capsulorhexis forceps, a parallel action forceps and a cross action forceps.

Microsurgical instruments have been carefully designed to achieve specific surgical goals

Appreciation of the principles of microsurgical instrument design makes it easier to use these instruments in the way their manufacturer intended.

Before introducing any instrument into an eye the trainee should be familiar with every aspect of their design. This is particularly true of the instruments used in creation of capsulorhexis.

Cystotomes

The most commonly used needles are a pre-bent cystotome and a 27 Gauge needle which is bent by the surgeon.

Use of a pre-bent cystotome ensures constancy of the angles in the needle. The smooth bend in the middle of the needle has the same radius of curvature as the lens. This is usually the safest option for the novice

Bending the needle allows customization of the angles in the needle. At least two bends are required. The first is very close to the tip (making it too far from the tip may cause trauma to the incision when the instrument is inserted. The second is near the needle hub and about 12 mm from the tip (the anterior chamber diameter). Getting this right is largely a matter of judgement and experience. If an error is made the needle may be re-bent or discarded. The degree of bending should to be less than 90^0 to allow both the instrument shaft and tip to be visualized from above.

Illustration 6.1 Capsulorrhexis needles (cystotomes)



A pre-bent cystotome (above) and a customized cystotome created by bending a 27G needle using a forceps.

Movie 6.1 Making a cystotomes

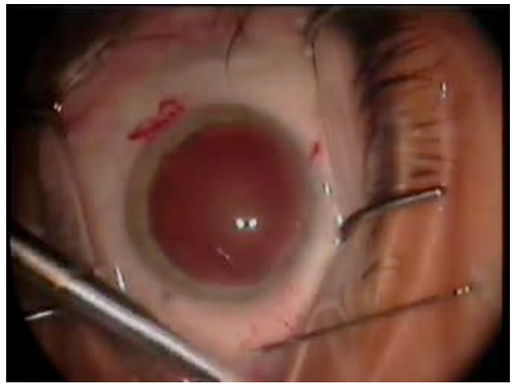

The 27 G needle is bent with a Castroviejo needle holder

Illustration 6.2 Capsulorrhexis forceps

Capsulorrhexis forceps

There are many different types of capsulorrhexis forceps. All have:

- A bend in the jaws (or curved shaft in the case of coaxial capsulorhexis forceps).
- Jaws which meet at the very tips only (to prevent accidental engagement of iris or capsule).

The important differences between them are:

- The jaws may be closed with a direct action, a cross-action or a squeeze action.
- The design of the tips is variable but many have a sharp tip for puncturing the capsule.

Direct action capsulorhexis forceps. Note the stop blocks near the bend which keep the shafts apart & prevent the iris being accidentally grabbed. These tend to cause wound gape and viscoelastic loss.

Principles of capsulorrhexis

Figure 6.2 Force vectors and capsulorhexis

The direction of propagation of the capsular tear depends on the forces acting at the point of tearing.

Successful capsulorhexis is defined by its' shape, size and centration.

These in turn are determined by a few easily understood physical principles relating to the forces applied to the tearing capsule.

Continuity of capsulorhexis

In a continuous curvilinear capsulorhexis any stretching force is distributed equally around the capsular opening. This makes it very resistant to tearing. Its acronym CCC can be used to describe the key features of Central, Circular and Correct size.

If there is an outward facing nick in the smooth capsular edge stretching forces tend to concentrate in this area. Even a small amount of stretching may cause this nick to extend. It may even extend around the equator of the lens to the posterior capsule; a 'wrap around tear'.

Illustration 6.3 Continuous and discontinuous capsulorhexis

The capsulorhexis on the right is at risk of extending.

Tear Propagation: Ripping vs shearing

An initial puncture is made in the centre of the anterior capsule. This puncture is then propagated peripherally and circumferentially by tearing (meaning "to pull apart by force"). If the tearing force is aligned with the direction of the puncture it is concentrated very focally at the leading edge of the tear - shearing. Shearing propagates the tear in the direction of the tearing force and is relatively easy to control.

Generally shearing is preferred when tearing a capsulorhexis. Ripping is useful when a very sudden change in the vector of tearing is required (see capsulorhexis rescue).

Movie 6.2 Shearing



The tearing force is aligned with the axis of the slit. The disruptive force is concentrated in a very small area at the apex of the slit. It is easy to control the rate and angle of propagation. Note how the material is folded over during shearing.

Movie 6.3 Ripping



The tearing force is perpendicular to the axis of the slit. Because the tension increases over a wide area the elastic limit of the material may be exceeded at several point more or less instantaneously. It is more difficult to control the rate and angle of propagation.

Movie 6.4 Shearing and ripping during capsulorhexis

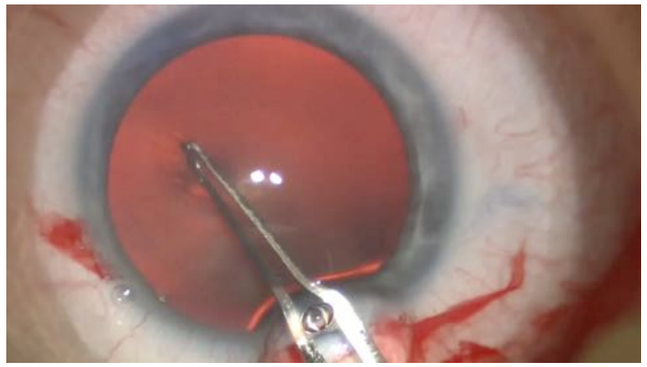

When the flap folds over this capsulorhexis converts from a predictable shear into a rip and runs out (note also the loss of viscoelastic which contributes to this).

Shearing forces during capsulorhexis

In order for shearing rather than ripping to occur the capsule must be folded over on itself and the vector of traction must be perpendicular to the line joining the point of the tear to the centre of the capsulorhexis.

Movie 6.5 Tearing a circle by shearing



Note that the capsule is folded over on itself.

Movie 6.6 Forces during shearing

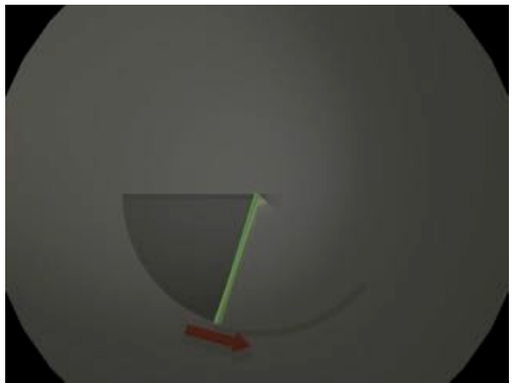

The same tearing seen 'en face'. The green line connects the tearing point to the centre of the circle. The red arrow represents the direction in which force is applied to produce a circular tear. It is always perpendicular to the green line, changing direction as the tear progresses.

Illustration 6.4 Capsulorhexis shearing

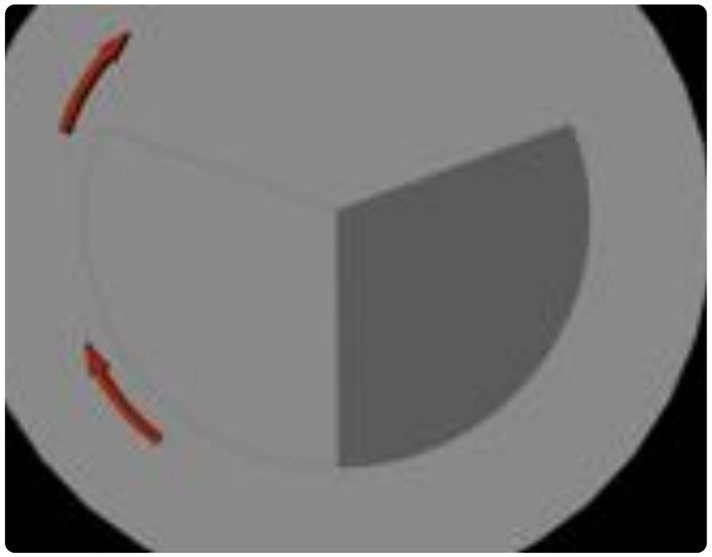

The capsulorhexis has been torn through 110^0. The light sector on the left represents the flap, the dark sector on the right the denuded cortex. The flap is lying flat on the intact anterior capsule. The arc at the outer borders of these 2 sectors have identical radii of curvature if shearing is occurring and the capsulorhexis is circular.

Visualizing shearing

Capsulorhexis often becomes more difficult to control about 2/3 of the way round because of the size of the capsular flap.

For shearing to occur the capsular flap must lie flat. The even symmetry between the capsular flap and the torn edge is then obvious. As the capsulorhexis proceeds the flap tends to fold over and obscure the tearing point. This may be prevented by sweeping the redundant capsule out of the way or flattening it with viscoelastic.

Movie 6.7 Capsular flap obscuring the tearing point

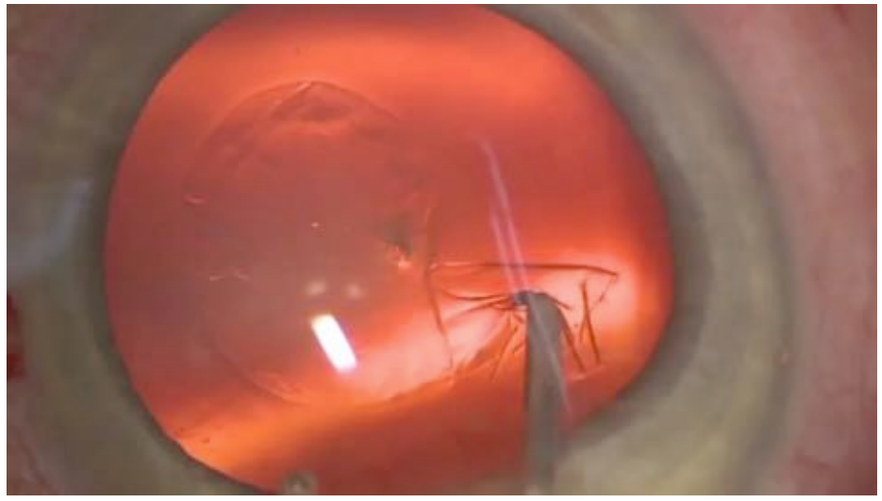

Here the flap folds over and transiently obscures the tearing point, making the symmetry about the tearing point difficult to appreciate

Movie 6.8 Manipulating the capsular flap.

Here the redundant capsular flap is swept out of the way so that the smooth even symmetry between torn edge and flap is easily appreciated.

Movie 6.9 Rhexis redirection

The capsulorhexis starts to run outwards. After viscoelastic refill (not shown) the flap is regrasped and pulled more centrally. Note the folds in the flap and loss of symmetry at the tear point. This only works when a very minor change in the direction of the rhexis is required and may even make things worse if the angle of the run out is more acute. In this situation it is better to perform a capsulorrhexis rescue.

Illustration 6.5 Capsulorhexis shearing

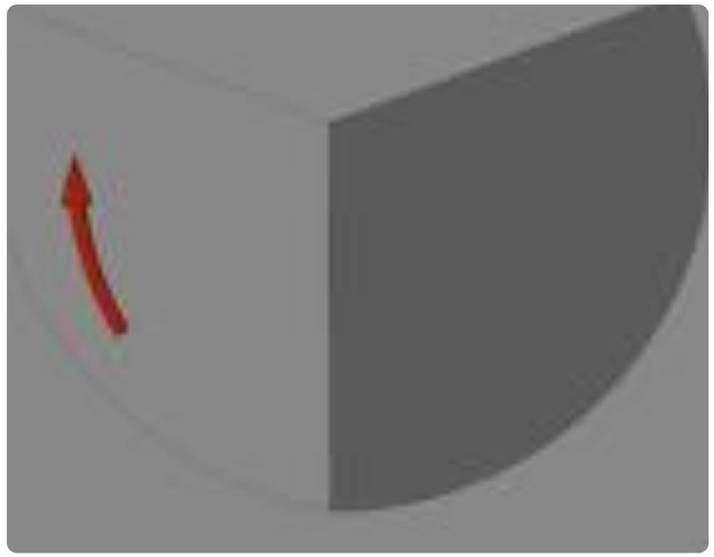

Here the capsule has not been laid flat and the direction of pull is slightly central. Note the very slight loss of symmetry at the point of the tear, which has a more pointed outline. This will tend to make the tear spiral inwards (the capsulorhexis becomes smaller). This may be used to control the size of the capsulorhexis. If the direction of pull becomes too central the flap of the tear may curl which converts the shear to a rip which causes the tear to spiral outwards.

Changing the direction of shearing - summary

If the flap is held close to the point of tearing the direction of the shear aligns with the vector of traction at the fixation point (in plain english, the tear goes where you pull it):

- If the capsular flap is pulled

Capsular tension and flattening

- Tension in the anterior capsule creates a tendency for tears to radialize (i.e. run outward towards the equator of the lens).
- This is counteracted by injecting viscoelastic into the anterior chamber, which flattens the anterior capsule and neutralizes this tension.
- Leakage of viscoelastic from the wound causes the capsule to become convex again and increases the tendency for the rhexis to radialize.

Illustration 6.6 The use of viscoelastic to flatten the anterior capsule

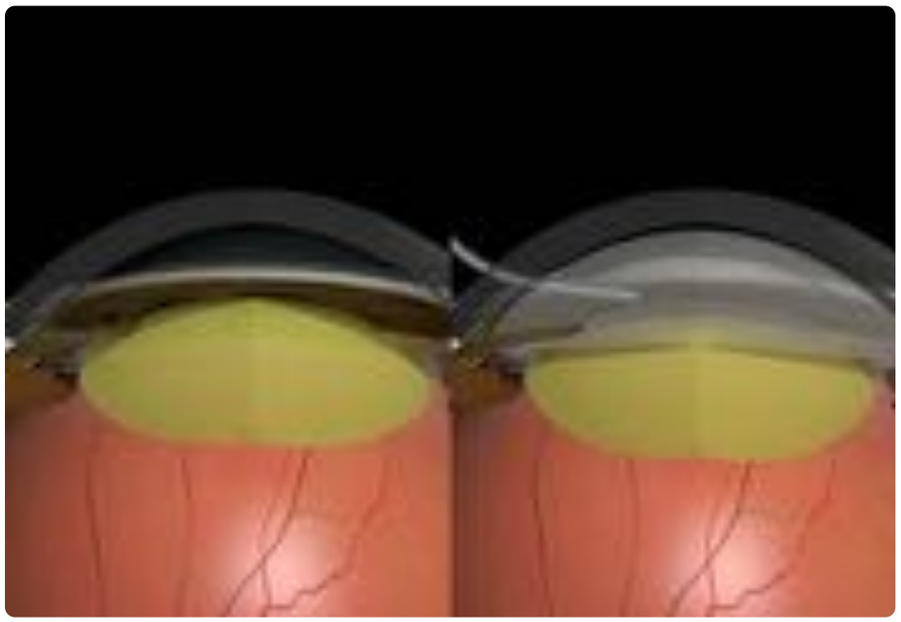

Compare the radius of curvature of the anterior capsule before (left) and after (right) the anterior chamber has been filled with viscoelastic.

Movie 6.10 Loss of viscoelastic and rhexis radialization

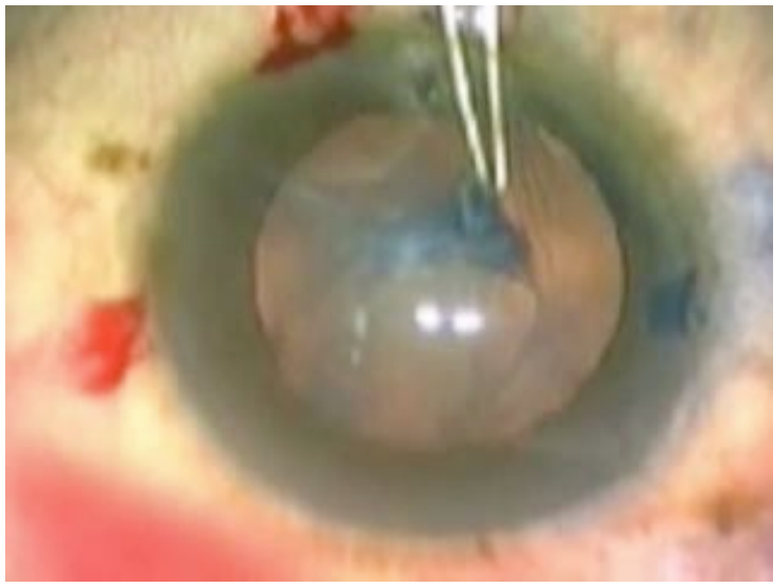

Viscoelastic is leaking out of the incision causing anterior chamber collapse and the rhexis tears outwards.

Wound neutrality

When performing capsulorhexis the instruments should pivot about the incision and (in theory) float within it.

Failure to do this causes:

- ocular rotation as horizontal pressure (in the x- and z-axes) is transmitted to the incision. This results in loss of the red reflex.
- incision gape as vertical pressure (y-axis) is transmitted to the incision. This causes viscoelastic leakage and chamber collapse.

Avoid upward or downward pressure by imagining the instruments floating in the incision. To depress the tip of an instrument within the eye the extraocular portion should be lifted, not depressed.

Movie 6.11 Horizontal wound neutrality

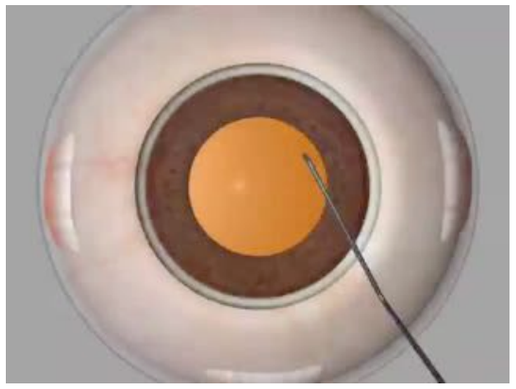

The capsulorhexis needle is pivoting about the wound and the eye remains stationary.

Movie 6.12 Lack of horizontal wound neutrality

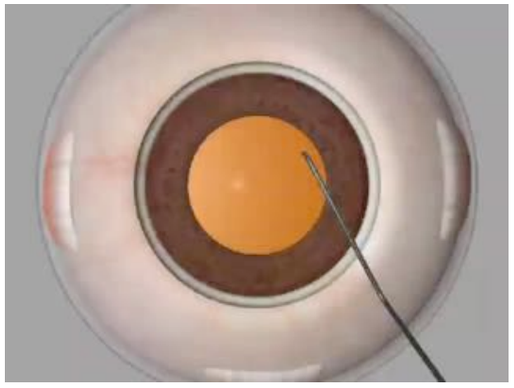

The needle is pivoting around a point outside the eye. Movements of the needle cause the eye to rotate. Note that the red reflex is lost as the optical axis of the eye moves out of alignment with the coaxial illumination system.

Movie 6.13 Lack of wound neutrality and red reflex

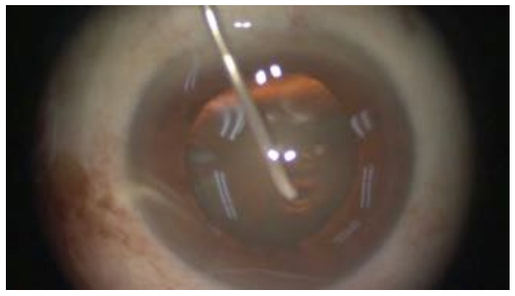

Notice how the induced movements of the eye effects the red reflex and view of the capsulorhexis.

Movie 6.14 Vertical wound neutrality

Downward pressure on the incision is causing it to gape. This causes loss of viscoelastic from the anterior chamber.

Diameter of the capsulorhexis.

This requires the use of two well developed cognitive faculties: the ability to judge constancy and symmetry.

The capsulorhexis should overlap the optic of the intraocular lens, which typically has a diameter of 6 mm. A 5 mm capsulorhexis achieves this with 0.5mm edge overlap of a 6 mm optic. This is approximately half the vertical corneal diameter. A key concept and anatomical reference is that the radial flap should extend almost half the distance from the central puncture point to the limbus.

Once the circumferential tear has started in the correct place the reference point can be shifted to the pupil margin to maintain a constant radius (this is reassessed and adjusted if the pupil diameter changes while the capsulorhexis is being created).

Illustration 6.7 The correct size of a capsulorhexis

The edges of the capsulorhexis should just overlap the edges of a 6 mm optic.

Illustration 6.8 Judging the correct size of a capsulorhexis (1)

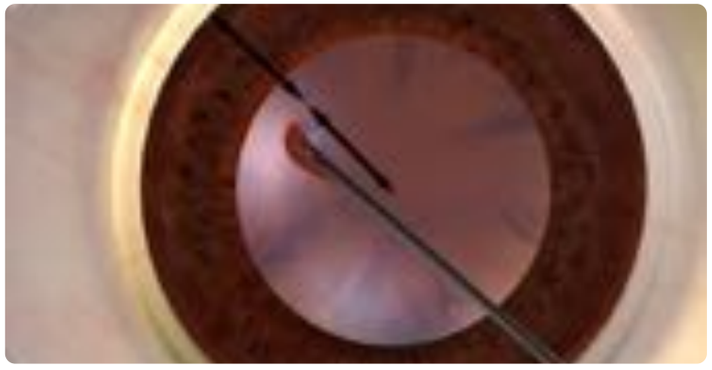

When making the radial slit puncture two reference points are used: the centre of the eye and the limbus. The capsule is punctured centrally and the radial incision extended 1 mm short of half way the the limbus (subsequent conversion to a circumferential flap takes it 1mm further out).

Illustration 6.9 Judging the correct size of a capsulorhexis (2)



The correct radius of the capsulorhexis having now been established all that is necessary is to maintain it. This is easier to do if the reference point is shifted from the limbus to the pupil margin (assuming the pupil diameter remains constant).

Centrality of the capsulorhexis.

If the initial capsular puncture is in the centre of the lens the capsulorhexis will also be central.

If the capsular puncture is eccentric in the *same* direction as the initial radial tear the capsulorhexis will be eccentric as the radial flap constrains the capsulorhexis.

If the capsular puncture is eccentric in the *opposite* direction to the initial radial tear the capsulorhexis can still be central as the flap is not constrained in the same way.

Illustration 6.10 Centric and eccentric capsulorhexis

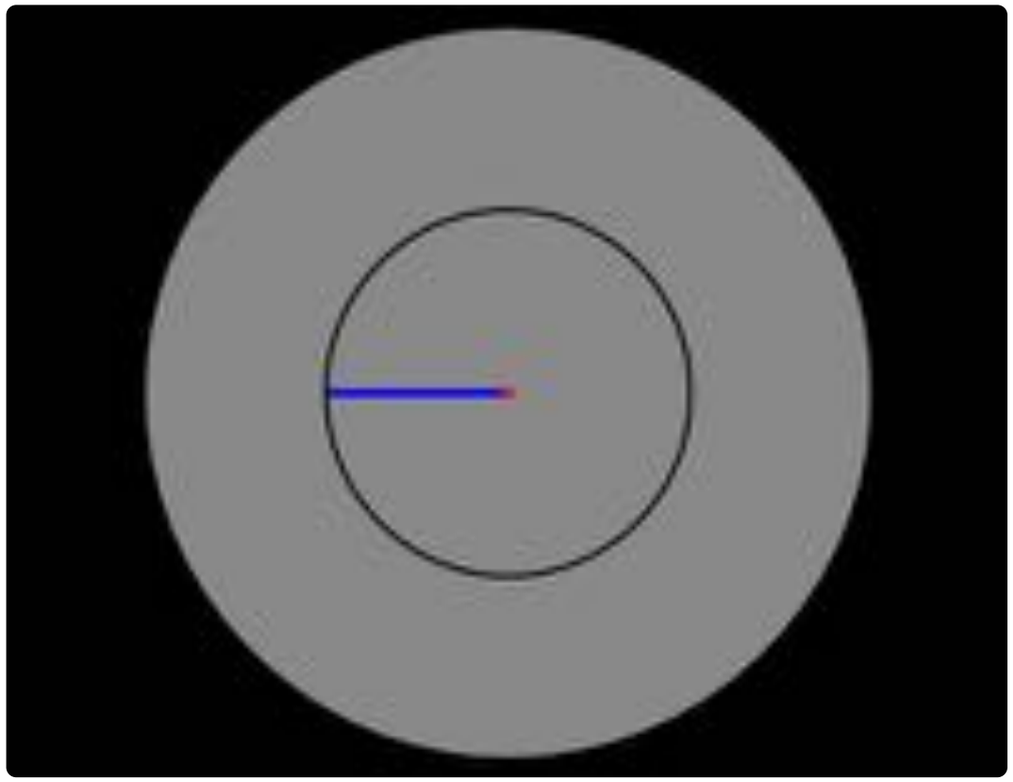

The capsulorhexis (black circle) is created by rotation of the the radial slit (blue line) around the centre of the capsule (red dot). The capsulorhexis is therefore centric.



Capsulorhexis direction.

Capsulorhexis may be performed equally well clockwise or counterclockwise.

Most surgeons have an innate preference for performing capsulorrhexis one way or the other. This seems to correlate with preference in drawing circles (i.e. the direction in which a circle is naturally drawn by a finger in the air with eyes closed).

The directional preference also relates to handedness. Flexion movements are naturally more comfortable, controlled and

Illustration 6.11 Direction of capsulorhexis

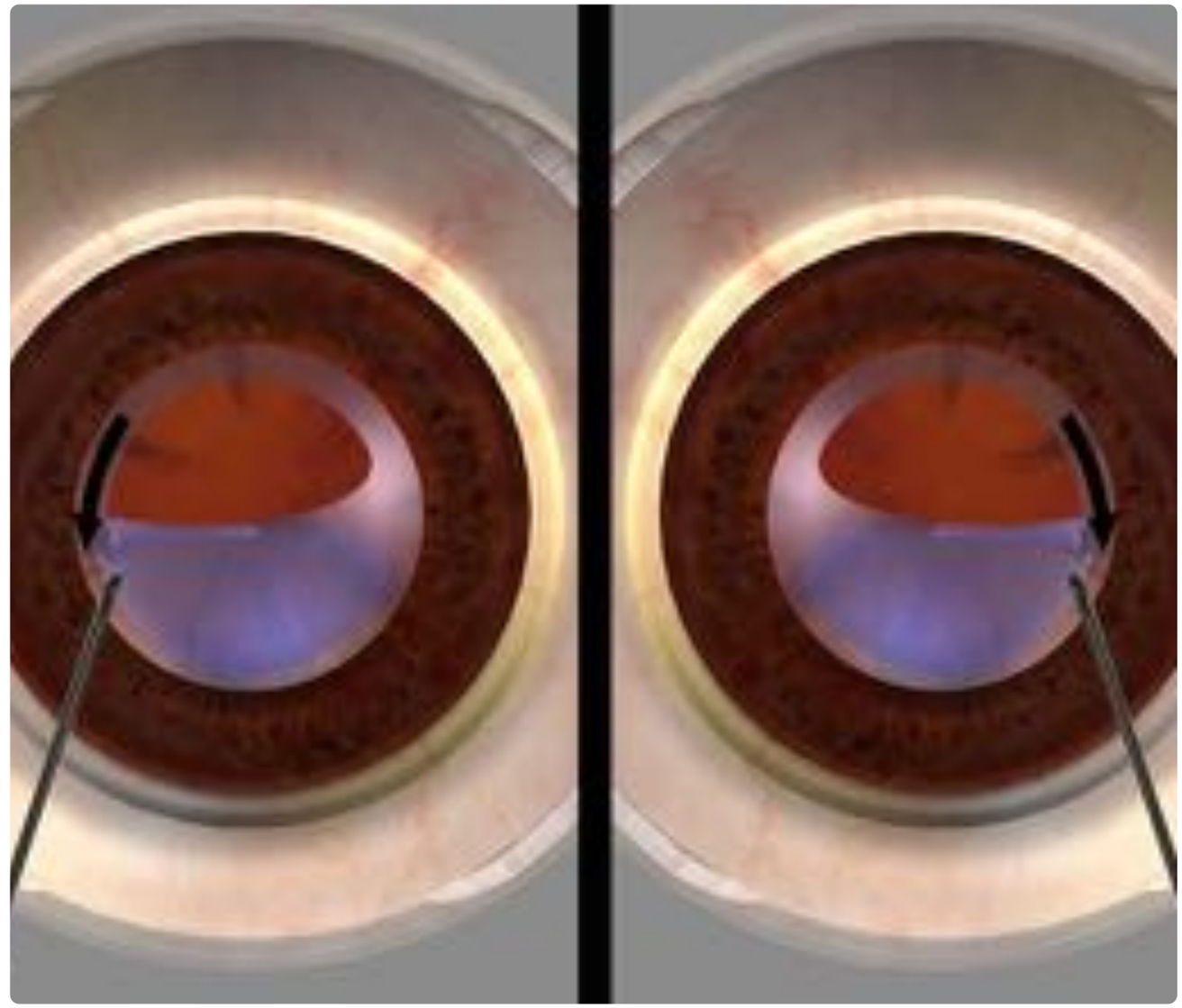

Capsulorhexis can be performed equally effectively in either direction

Capsulorhexis techniques

Figure 6.3 Force vectors and capsulorhexis

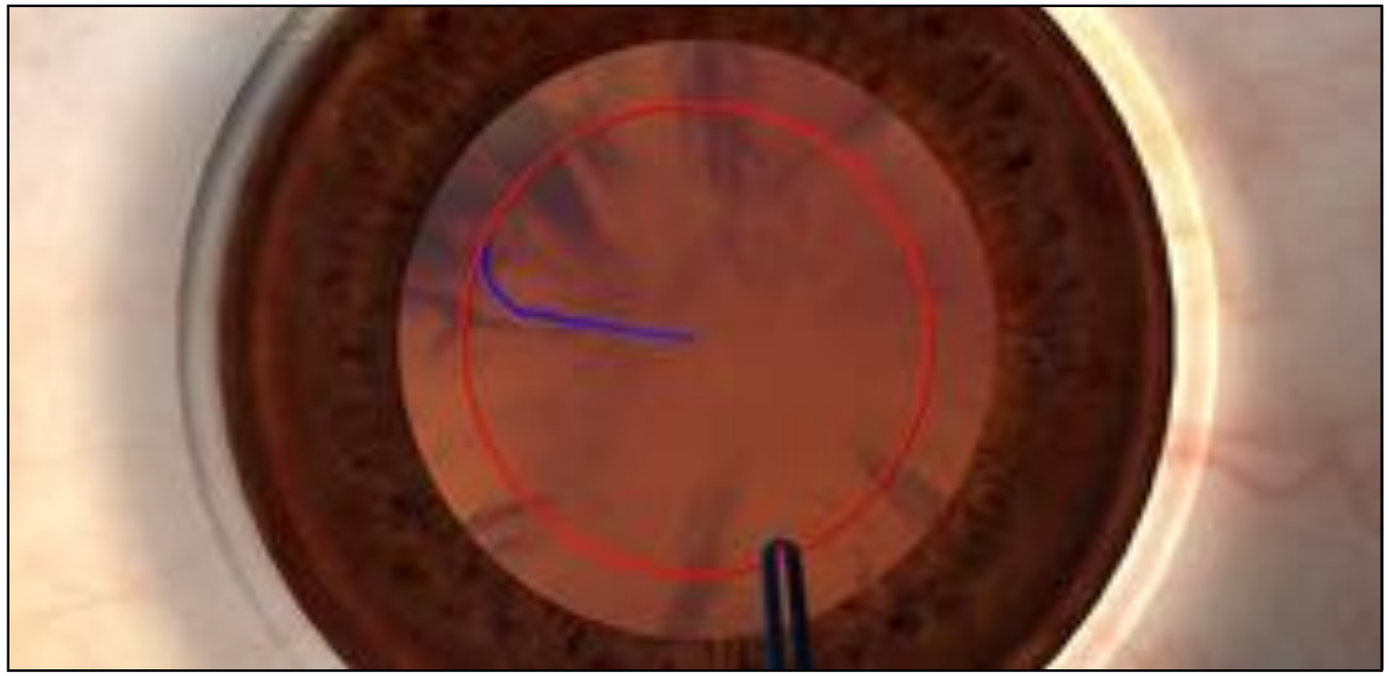

The radial (blue) and circumferential (red) tears

Capsulorrhexis is generally performed by puncturing the capsule centrally then creating a radial tear which is converted into a circular circumferential tear.

This may be performed using a needle, a forceps or both instruments.

Needle versus forceps

The advantages of using a needle for the capsulorhexis are

- low cost
- reduced risk of wound gape and anterior chamber collapse owing to the smaller diameter of the instrument
- ability to perform capsulorhexis through a side port (for example when dealing with a sub-

The advantage of a using capsulorhexis forceps is:

•the ability to control more precisely the direction in which traction is applied to the flap, for example when performing a capsulorhexis rescue. Using a needle one vector of traction is lost as constant slight downward pressure needs to be applied throughout in order to keep hold of the flap.

Both techniques may be liberally combined as required. For example the puncture and radial flap may be created with a needle and a forceps used for the rest of the capsulorhexis.

Preparation for capsulorhexis

1. The eye should be filled with viscoelastic to flatten the anterior capsule.
2. The red reflex is optimized by:
   - Employing coaxial illumination.
   - Aligning the optical axis of the eye with the coaxial light paths. Patients undergoing surgery using topical and/or intracameral anesthesia are instructed to look directly at the light.
   - Minimizing ocular movements induced by the instruments using wound neutrality (pivot and float).
   - Keeping the cornea moist using either saline or preferably a dispersive viscoelastic such as methylcellulose.
   - If the red reflex is suboptimal a capsular dye may be used.

Movie 6.16 Viscoelastic fill error - bubbles

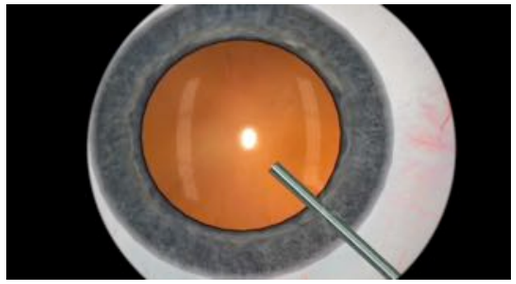

Avoid injecting bubbles into the anterior chamber by first injecting outside the eye.

Movie 6.15 Effect of corneal wetting on the red reflex

This may be achieved by having an assistant irrigate the cornea regularly with saline or coating the cornea with a dispersive viscoelastic.

Capsular puncture - radial slit

Capsulorhexis is initiated by puncturing the anterior capsule. This creates a slit in the anterior capsule. Care is taken not to penetrate the capsule too deeply as the resulting disturbance of the cortex makes the tear difficult to see.

A blade may be used to create a slit in the anterior capsule after the main incision.

Figure 6.4 Anterior capsule slit

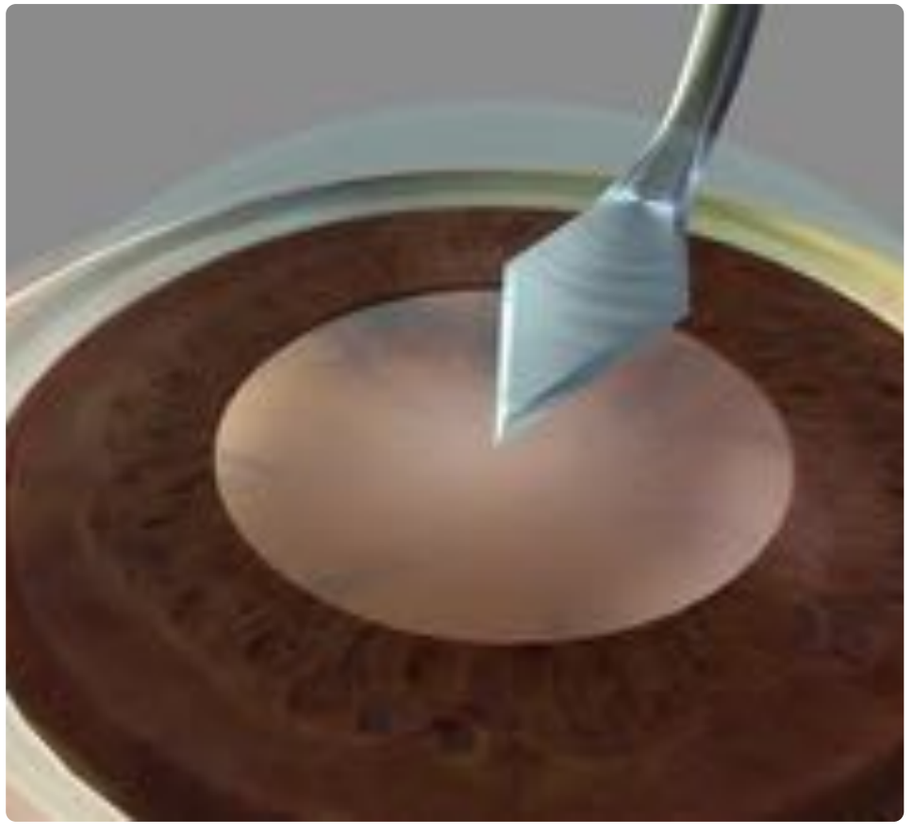

A slit may be created by advancing a keratome into the lens.

Capsular puncture - radial slit (ctd.)

A slit may also be achieved with central puncture followed by lateral movement of a cystotome. The resulting radial slit is converted into a circumferential flap by a circumferential movement of the tip of the needle at the end of the incision. This may be a pulling movement (the flap is brought towards the surgeon) or a pushing movement (the flap lies away from the surgeon).

Instead of a linear slit a curved incision may be made - this may be easier to turn into a circumferential tear.

Movie 6.17 Conversion of linear radial slit to circumferential flap

After a central puncture the needle is moved outward to achieve a radial slit. This is converted to a circumferential arc by changing the axis of travel - note that the change in direction of the tear is not immediate (the tear expands outwards as it changes direction). This has to be allowed for to achieve a capsulorhexis of the correct size.

Movie 6.18 Movie 6.13 Conversion of radial slit to circumferential flap

In this case the needle is brought towards the surgeon to create the flap.

Illustration 6.12 Curvilinear slit

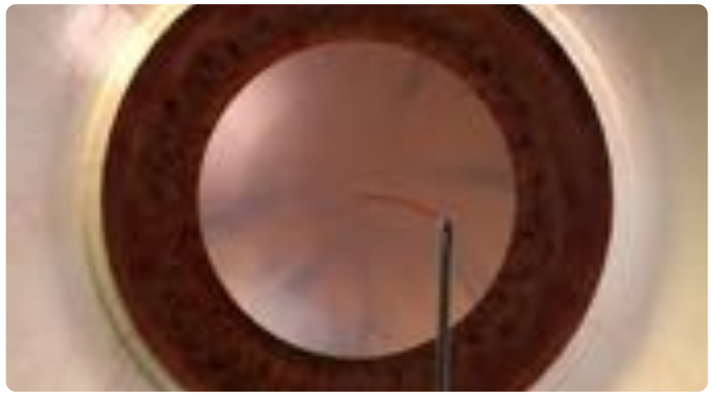

A curvilinear radial incision is an alternative to a linear slit. This may be easier to convert to a circumferential tear.

Sometimes the slit is difficult to identify due to opacification of disrupted cortical lens fibers (especially if a forceps is used as the capsular puncture tends to be deeper). In this case the instrument may be passed through the flap near its' lateral limit and lifted. This causes the tear to extend beyond the area of disrupted lens fibers so that it becomes visible.

Movie 6.19 Capsulorhexis initiation - lifting under the flap

Following the creation of a radial slit the cystotome is passed through the slit and then lifted. This causes the radial slit to run circumferentially. This is a hypermature cataract with high intracapsular tension and a significant risk of tear out so the initial radial tear is limited and the needle is quickly moved to allow a more conventional shearing tear.

Capsular puncture - triangular tear

A triangular tear is created by engaging the central capsule and directing the needle or forceps radially. The resulting triangular flap is converted into a circumferential tear by gradually changing the direction of travel of the needle from its' initial centripetal radial direction to a circumferential arc. The flap then spirals outwards into a radial flap. The rate at which this occurs (which determines the size of the capsulorhexis) depends on the rate of change of the vector of travel of the needle.

Figure 6.5 Capsular tear



A very shallow central puncture is made in the capsule

Movie 6.20 Conversion of a triangular flap to a radial flap

Note the dimple prior to capsular puncture - its' location indicates that the capsular puncture will be central. Once the triangular flap has been initiated movements of the needle change from radial to circumferential. These circumferential movements may be in either direction to convert the triangular flap to a circumferential tear.

Needle capsulorhexis

Following capsular puncture and radial slit the circumferential flap is created by repeatedly engaging the anterior capsular flap:

- A degree of downward pressure on the capsule is required
- The optimum position for the engagement is 1-2 clock hours from the tearing edge.
- The capsular flap is re-engaged frequently.

Movie 6.21 Needle capsulorhexis

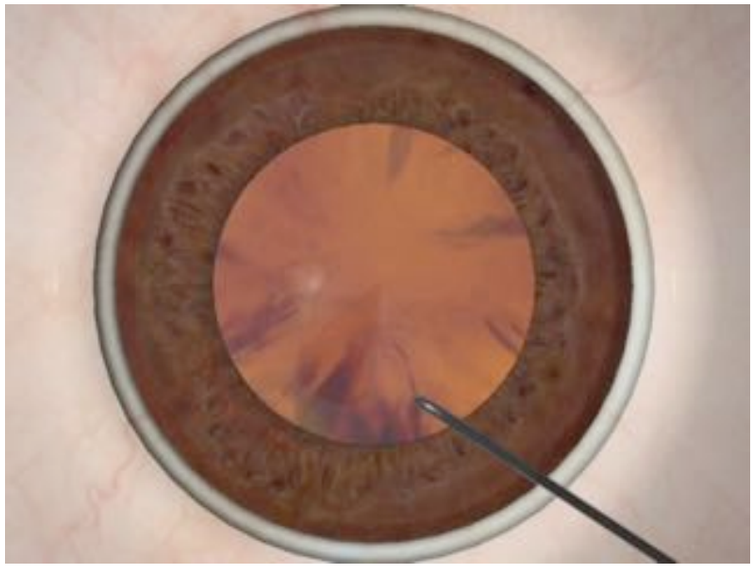

The flap is engaged about 1 clock hour from the tearing edge and re-engaged frequently keeping the flap flat on the underlying capsule. The distance between the edge of the iris and the tear is monitored closely. In this animation the capsular flap is obligingly staying out of the way. This does not happen in practice. As the flap gets larger it may need to be swept centrally or displaced with viscoelastic so that the tearing point remains clearly visible.

Illustration 6.13 Redirecting the tear

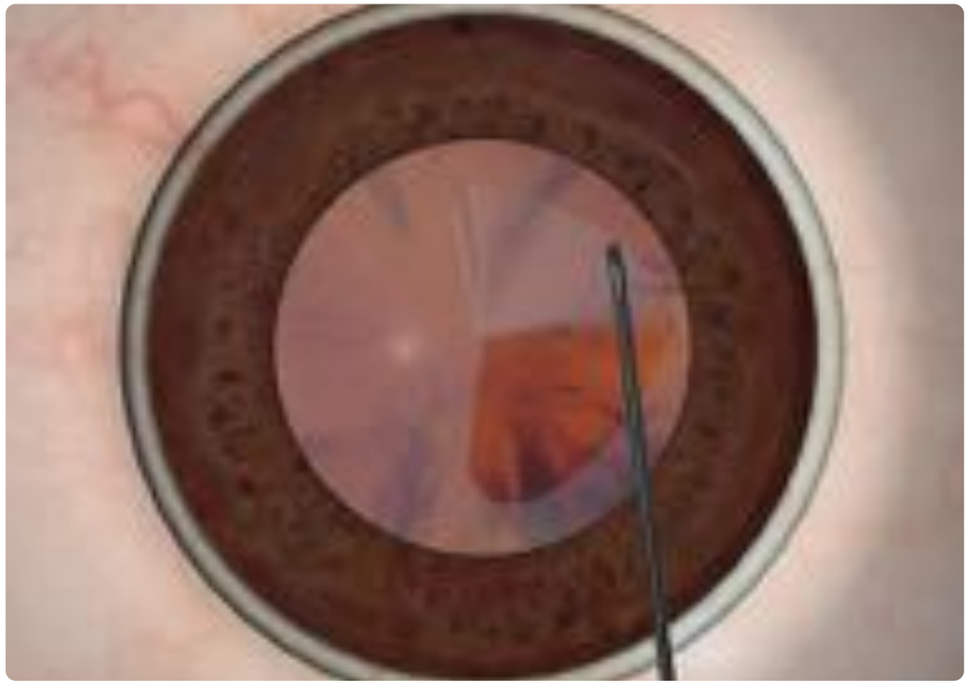

The tear has started to run peripherally (a capsular dye has been used in this case).

Examples of needle capsulorhexis

Below are two unedited examples of needle capsulorhexis performed by trainee ophthalmologists.

Movie 6.22 Needle capsulorhexis (1)

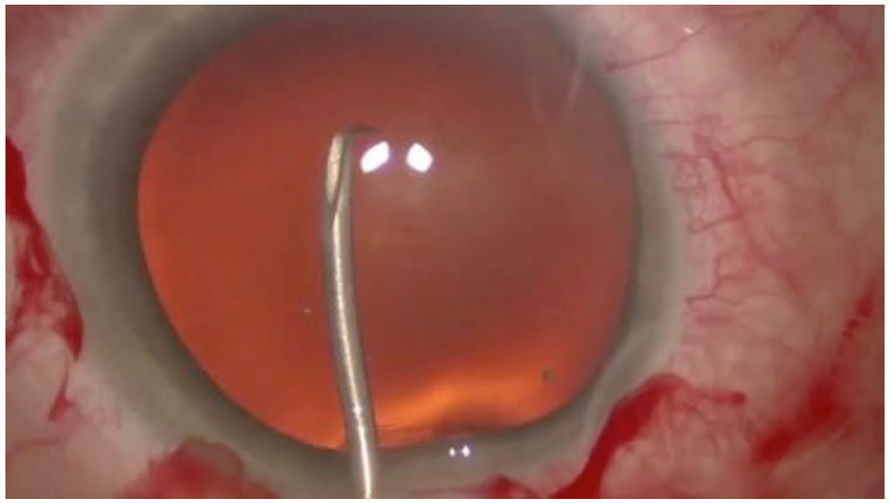

The capsulorhexis is started with a radial slit. Notice the frequent refilling of the anterior chamber with viscoelastic (the needle stops moving briefly and the pupil slightly expands when this is done). Notice also the frequent re-engagement of the capsular flap and the effort made to keep the capsular flap folded over and away from the point of the tear. Consequently the symmetry between the torn capsule and the flap is easy to appreciate in this video.

Movie 6.23 Needle capsulorhexis (2)

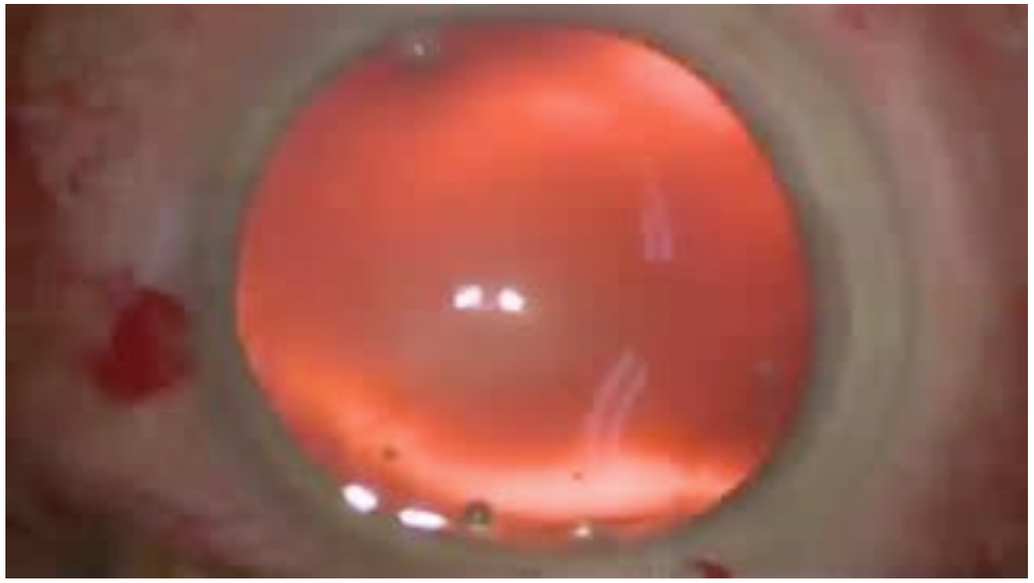

Note that the needle is rotated 90^0 during entry to avoid trauma to the incision from the sharp tip. The capsulorhexis starts with a triangular flap which spirals out. Notice also the the capsulorhexis is terminated 'outside in' to avoid an outward facing notch. Notice that 270^0 through the tear the free capsular flap lies over the tearing point, obscuring it. This could have been avoided by manipulating the free flap out of the way with viscoelastic or the needle tip as was done in Example 1.

Needle capsulorrhexis through a side incision

One advantage of using a needle is that capsulorrhexis can be performed via a side incision:

- There is minimal loss of viscoelastic so the anterior chamber depth remains stable.
- If a capsulorrhexis starts to run out sub-incisionally it is sometimes easier to retrieve using a side port.

Movie 6.24 Needle capsulorhexis via a side incision

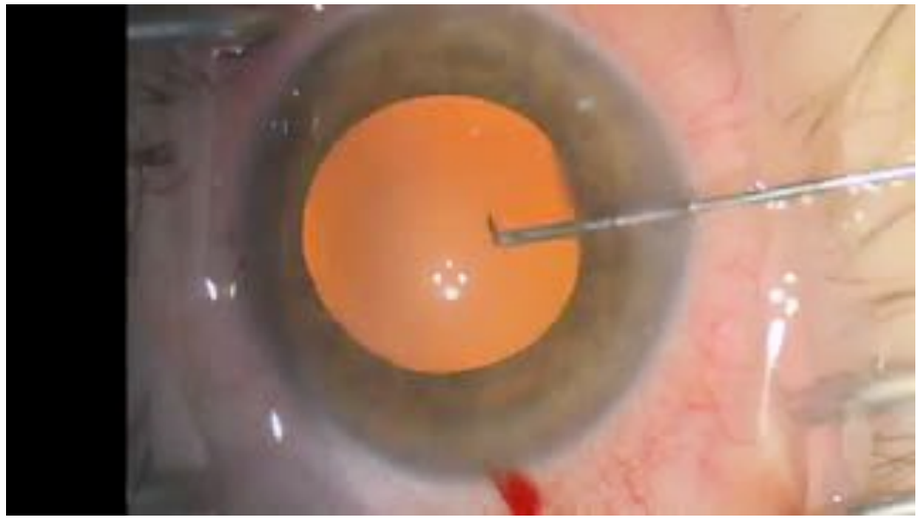

Note the anterior chamber stability and minimal loss of viscoelastic.

Forceps capsulorhexis - capsular puncture and radial tear

Capsular puncture and creation of a radial slit may be performed using the needle as already described.

Alternatively the capsule may be punctured and a radial slit made using the forceps. Many forceps have sharpened tip to facilitate this. The forceps tends to penetrate deeper into the lens than the needle. The resulting disrupted capsular fibers make the tear difficult to visualize. The forceps is passed under the capsule near the lateral end of the radial tear and lifted. This causes the tear to extend beyond the area of disrupted lens fibers so that it becomes visible.

As when using a needle the initial radial slit should be smaller than the desired capsulorhexis size to allow for the radial extension that occurs when the flap is turned over.

It is important that the small lifting motion is carried out at the lateral *end* of the tear, not its' centre, as this would cause the tear to simply rip outwards.

Movie 6.25 Capsular puncture with forceps (frontal view)

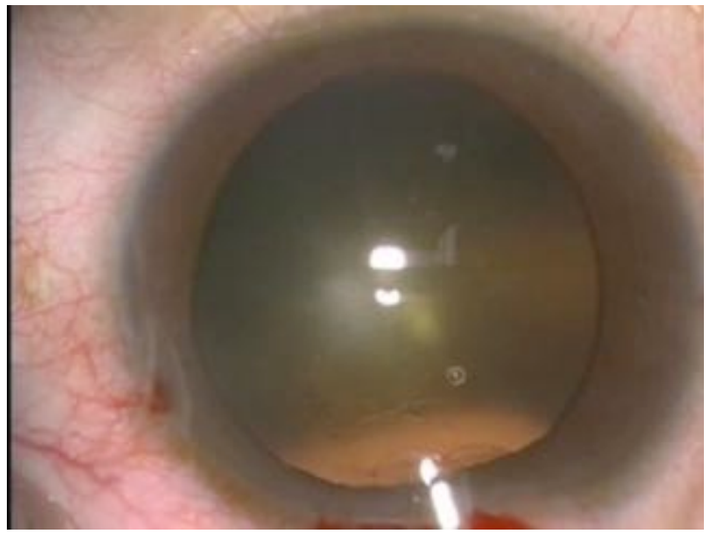

Frontal view of capsular puncture and radial slit with forceps.

Movie 6.26 Capsular puncture with forceps (lateral view)

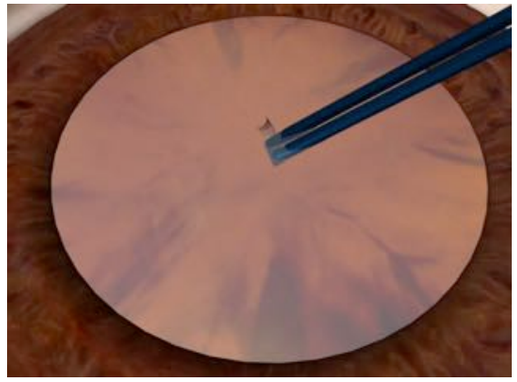

Following central puncture the capsulorhexis forceps is moved laterally to create a radial slit. The disrupted cortex is opaque and the slit is difficult to identify until the forceps is very slightly lifted, causing the capsulorhexis to extend laterally beyond the area of disrupted cortex so that it can be grasped by the forceps.

The forceps are placed, jaws open on the anterior capsule. The tip is pressed down slightly to indent the capsule and then closed. The resulting tear is then enlarged in a spiral motion.

Movie 6.27 The capsular pinch technique

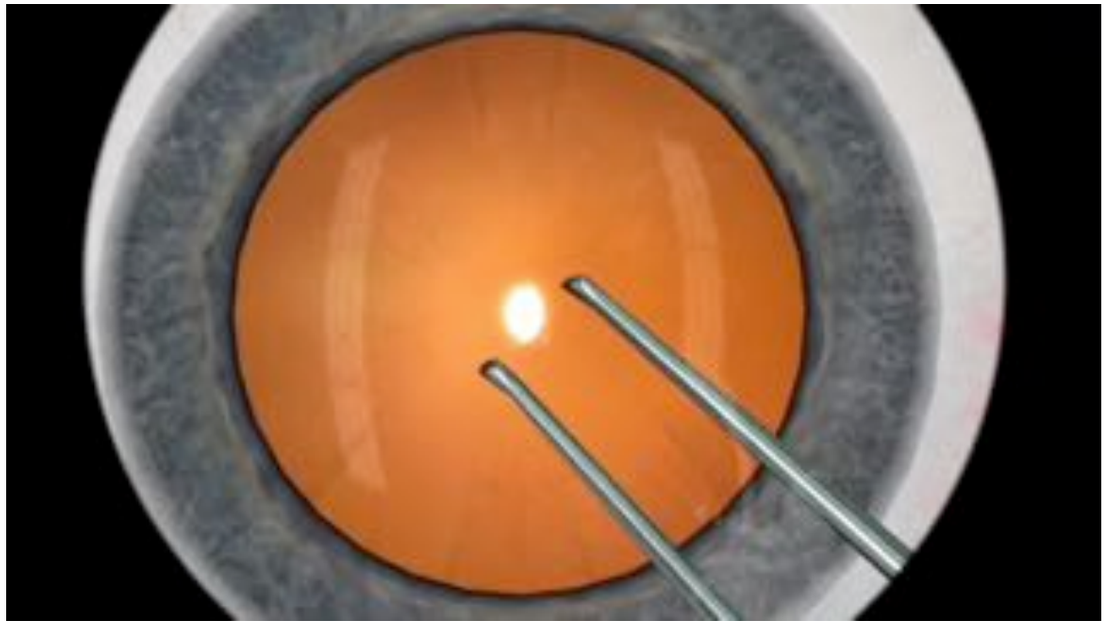

The pinch tears the capsule and engages the flap in the jaws of the forceps. This is then spiraled out to the correct diameter.

Forceps capsulorhexis - circumferential tear

The use of forceps allows very precise control of the direction of the tear. The basic principles are the same as needle capsulorhexis. Because of the greater degree of control the flap does not have to be re-grasped as often as a needle capsulorhexis. It therefore tends to be quicker to execute. As the length of the flap approaches 90^0 this control is lost as the flap tends to roll over. The shear then turns into a rip. This is a cue to regrasp the flap closer the point of tearing.

It is possible when using forceps to pull upwards but this tends to cause a rip which extends the tear outwards. As when performing a needle capsulorhexis the flap should be flat on the underlying capsule.

Illustration 6.14 Inclination of traction

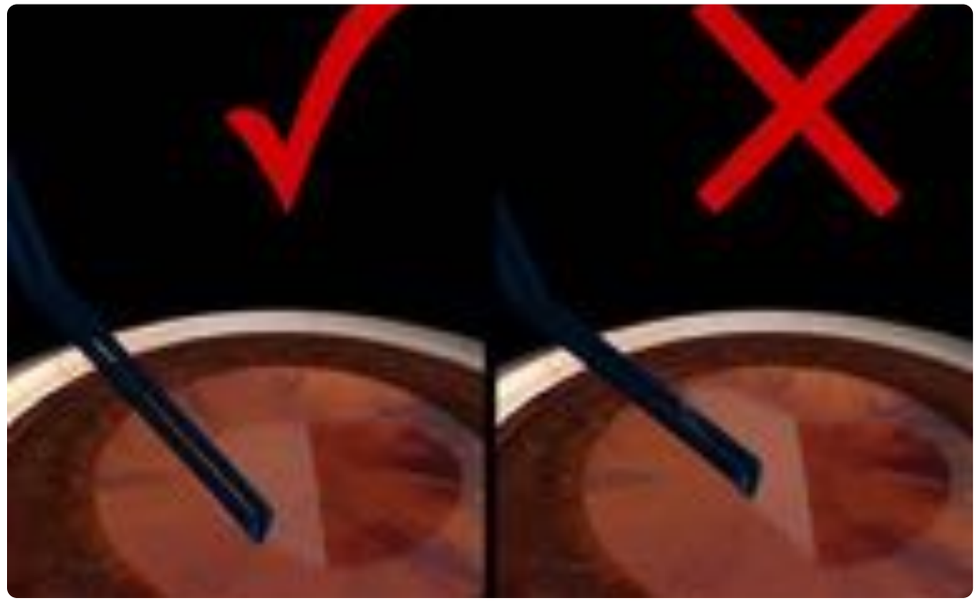

The flap should be kept flat on the capsule (left), not pulled upwards (right)

Movie 6.28 Circumferential tear with forceps

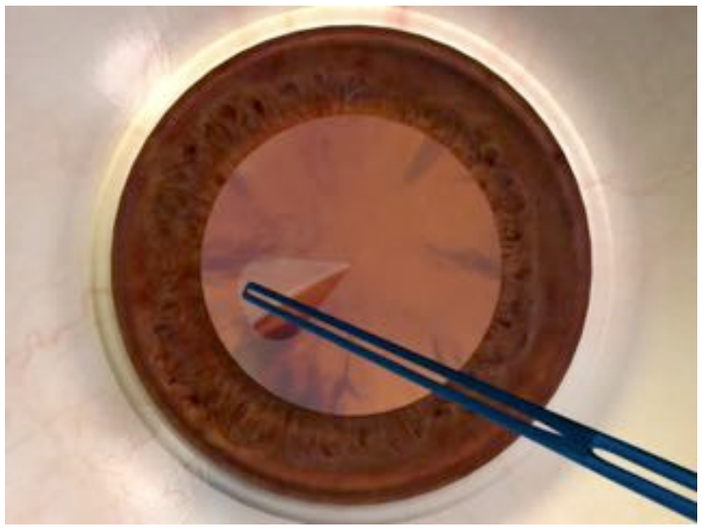

The capsulorhexis is grasped near the tear and propagated circumferentially - note that the flap does not need to be regrasped as often as when using a needle.

Forceps capsulorhexis - regrasping the flap

It is important that the flap is engaged in the correct place. This is the edge of the flap close to, but not at the origin of the tear. Grasping the radial portion of the flap should be avoided as it may causes ripping rather than shearing.

Grasping the edge of the flap is difficult if it lies flat. It is easier to re-grasp the edge of the flap if, before being released, it is pulled centrally and lifted slightly.

Illustration 6.15 Grasping the flap

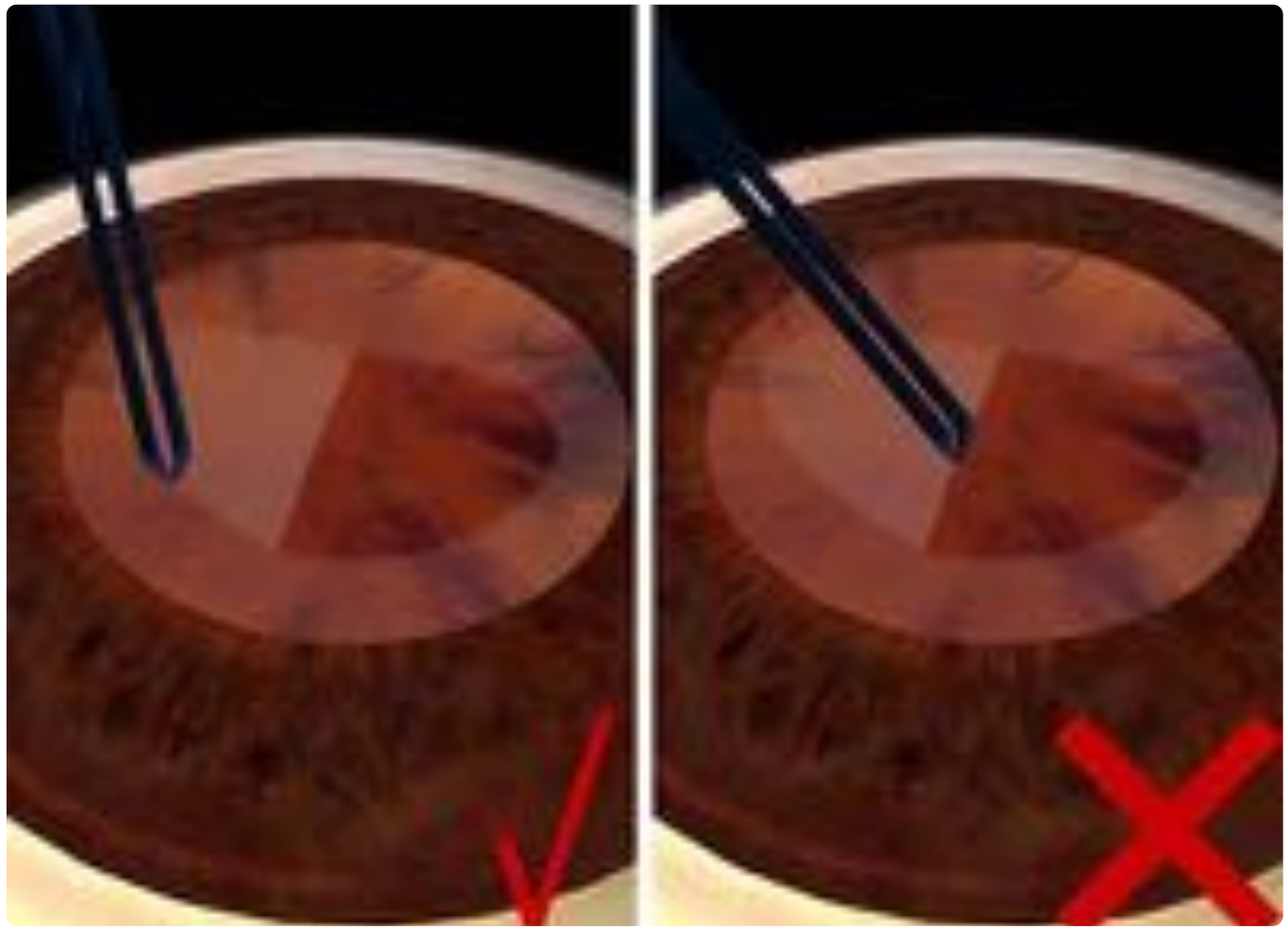

The circumferential edge of the flap is grasped, not the radial edge.

Forceps capsulorhexis - circumferential tear

The most challenging part of a forceps capsulorrhexis is the subincisional region. Distortion of the wound may impede the view of the tear, which also travels under the forceps in this area. It is best to complete this as a single maneuver, having refilled the chamber with viscoelastic, to avoid the need to re-grasp in this area. Since wherever it is located it is the first sector of the rhexis that is always the easiest to perform, it makes makes senses to undertake the subincisional sector of the rhexis as the first part. This seems anti-intuitive to begin with but many surgeons adopt this approach once familiar with it.

Movie 6.29 Subincisional forceps capsulorrhexis

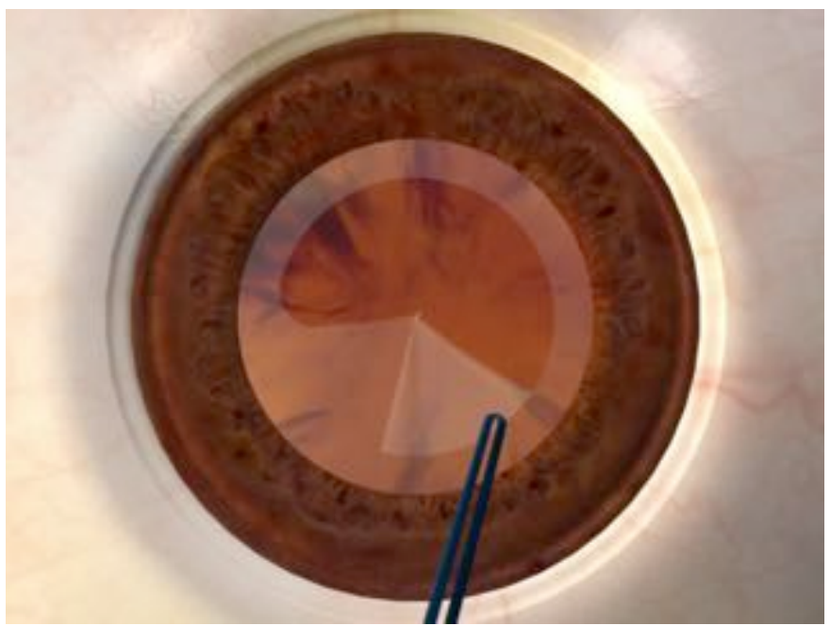

The flap is released immediately before the incision and the anterior chamber refilled with viscoelastic. A combination of pivoting and then advancing the forceps brings the tear through the subincisional area and under the forceps.

Losing the tearing edge with an uneven red reflex

The uneven red reflex caused by cortical or posterior subcapsular lens opacity can be almost as problematic as an absent red reflex.

Capsular dyes are very effective in addressing this problem and can be safely introduced under viscoelastic during the rhexis to enhance the torn edge when visualization has become difficult.

The magnocellular ganglion cells in our retinas are very good at detecting movement. When a capsulorrhexis is moving the tearing point is easier to see than when it stops moving. If for any reason tearing is paused (for example to refill with viscoelastic) it may be difficult, if the red reflex is un

Movie 6.30 Losing the flap.

In this case with an uneven red reflex due to posterior subcapsular opacity the tear is easy to see while it is moving. Once is stops moving (for viscoelastic refill) it is lost. This video has been heavily edited, and the tearing point only became apparent after some time when the edge of the flap was fortuitously grabbed with forceps. Note that at the end of this video the tear remains visible even though it is moving through an area with no red reflex. It is not advisable to release the flap under the incision (as was done in this case).

Capsulorhexis rescue

Figure 6.6 Errant capsulorrhexis

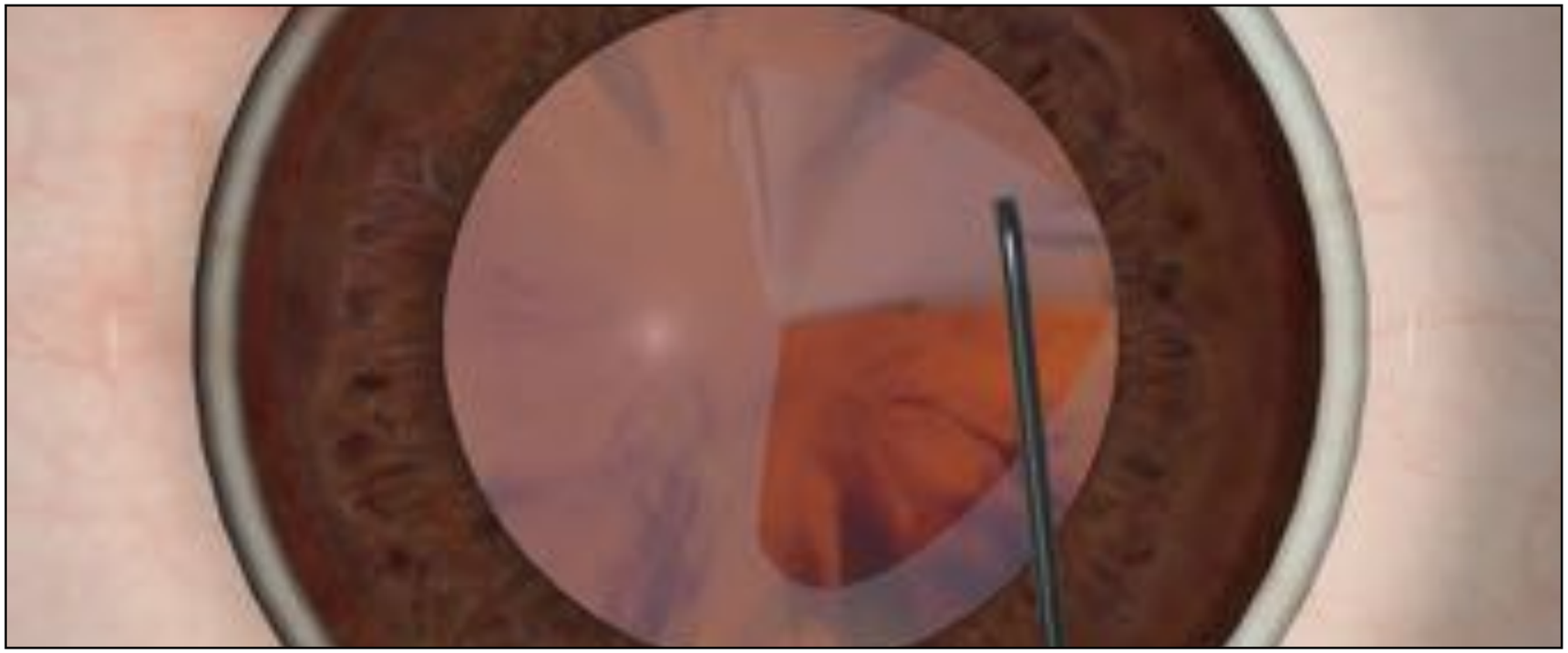

This tear has run outwards. Continuing to pull as shown is likely to cause the tear to extend radially.

Radial tear out of a capsulorrhexis may lead to significant complications if not managed properly.

Fortunately there is a very reliable rescue technique that involves creating an inward rip.

Why does the capsulorhexis run out?

Capsulorhexes tend to run out for 2 reasons:

- Unrecognized loss of viscoelastic. Some degree of viscoelastic loss is inevitable when instruments are in the eye. Failure to respect wound neutrality causes the wound to gape and accelerates the flow of viscoelastic out of the eye. The anterior chamber shallows and the tension in the anterior capsule rises. This causes radial tear out. In fact, once the tear has reached a critical point, capsular tension may cause the tear to continue to extend peripherally spontaneously even if it not manipulated and no instruments are in the eye.
- The capsulorhexis strays into the peripheral zone where the zonules attach to the capsule. The radial orientation of the zonules makes the tear run radially.

What are the consequences of radial tear out?

The tear may extend around the equator to involve the posterior capsule, leading to vitreous prolapse into the anterior chamber and dislocation of lens matter into the vitreous.

Illustration 6.16 A wrap around capsular tear

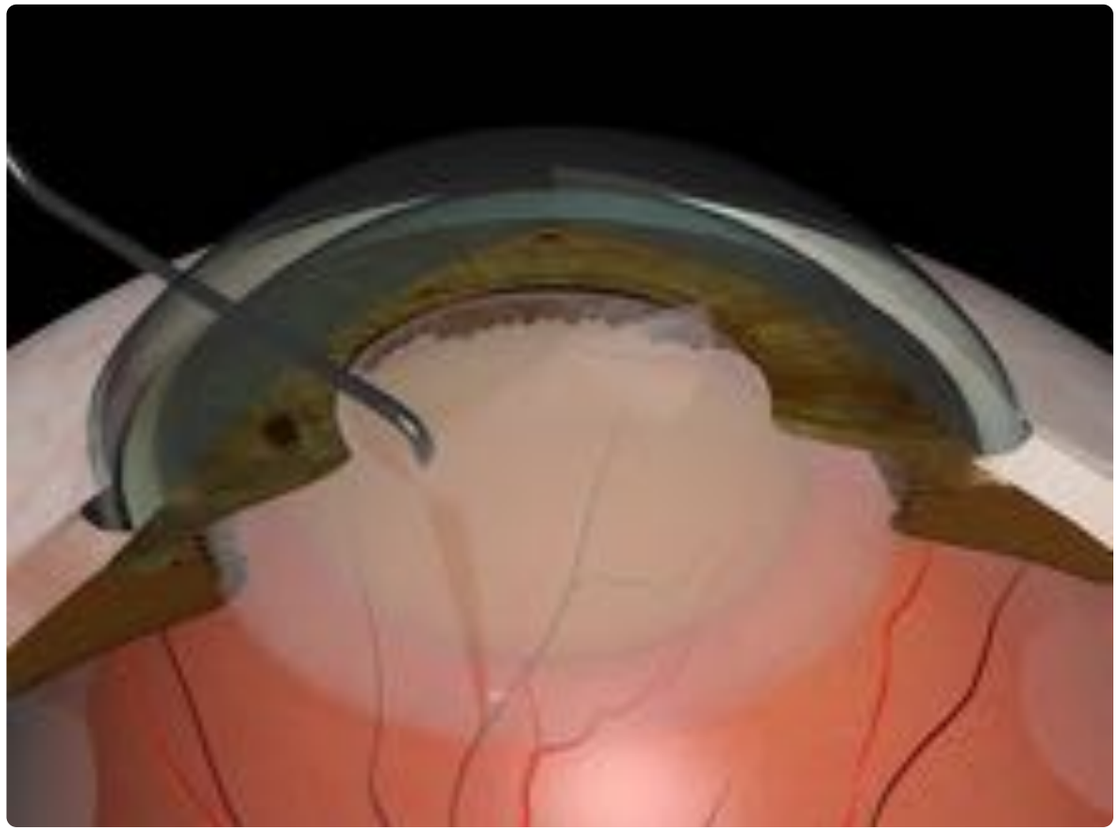

The tear extends around the equator to involve the posterior capsule.

Why does the errant tear not respond to simple shearing redirection of the flap?

Shearing only occurs when the capsule is folded over on itself and the edge of the flap is aligned with the edge of the tear. Because the tear is running radially it is impossible to lie the anterior flap down on the untorn capsule without the shear running radially. Thus the tear inevitably turns into an outward rip.

Illustration 6.17 Shearing and ripping forces in an errant capsulorhexis

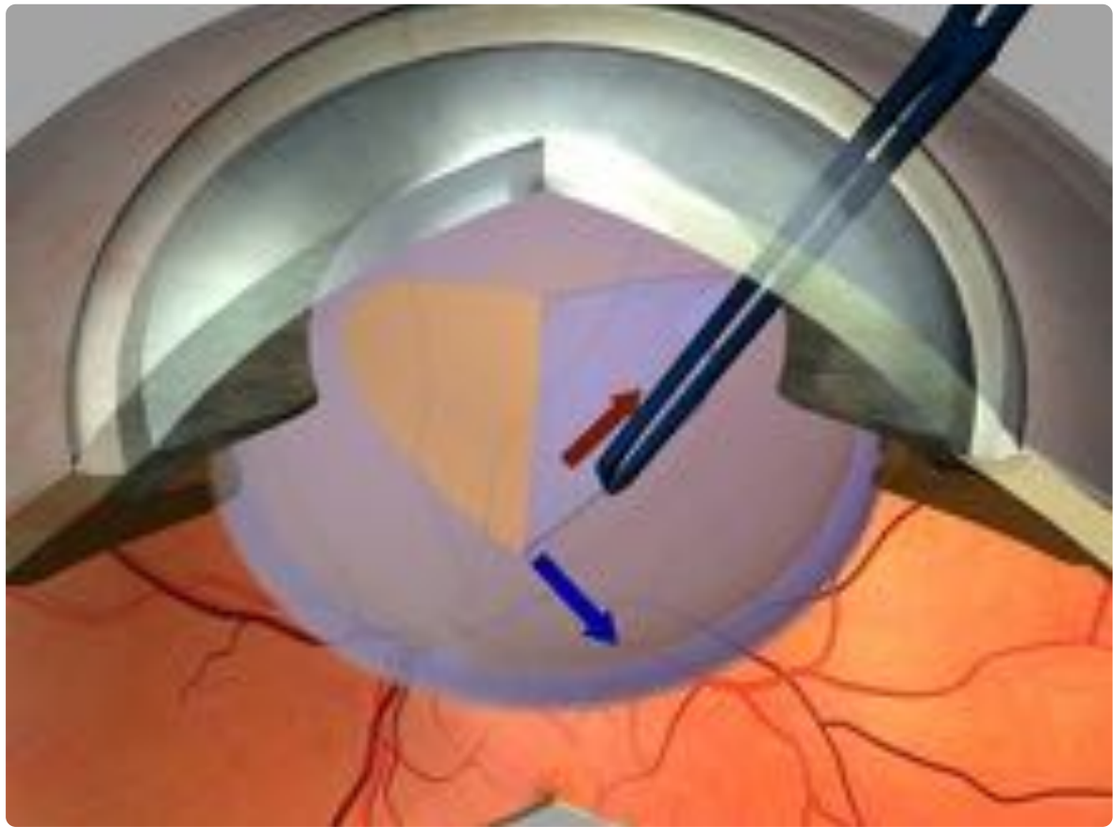

When the flap lies down on the untorn capsule it is not possible to reproduce the smooth symmetry of a circular tear (see Illustration 6.4). Even though the vector of traction is slightly inward (red arrow) the tear will run out (blue arrow) because outward ripping will occur.

The Little rhexis rescue technique

One of the authors has described a highly effective technique for rescuing an errant capsulorhexis using inward ripping

1. The anterior chamber is refilled with viscoelastic.
2. The capsular flap is unfolded so that it lies flat on the lens cortex. This can be achieved using viscoelastic simultaneously with step 1.
3. The edge of the capsular flap is grabbed close to it's origin and pulled slightly backwards (i.e. towards the start of the circumferential tear) applying traction in the plane of the anterior capsule.
4. While maintaining this slight tension in the flap the forceps is then pulled centrally.

This causes an abrupt change in the direction of the tear. It should be discontinued as soon as the tear starts to turn. The capsulorhexis is then completed using the normal shearing technique (i.e. with the capsular flap resting flat on the untorn capsule).

Illustration 6.18 The steps in a capsulorhexis rescue



The tear is noted to be running outwards.

Movie 6.31 Capsulorhexis rescue

An attempt to redirect the flap centrally fails. A rhexis rescue is then successfully performed.

Capsulorhexis enlargement

Figure 6.7 A small capsulorhexis



A small capsulorhexis makes the remainder of the operation difficult.

Hydrodissection is more challenging with a larger surface area of anterior cortico-capsular adhesions to separate. This in turn increases the likelihood of capsular block during hydrodissection and a blow-out of the posterior capsule. Damage to the edge of the rhexis is more likely both from the second instrument and the phaco tip resulting in anterior capsule tear with possible posterior propagation.

Even if the operation is completed successfully a small capsulorhexis may give rise to postoperative problems. Opacification and loop contraction of the edge may result in a very small opening (capsular phimosis) which may cause troublesome glare. As the capsular bag contracts stress on the zonules may cause the intraocular lens to sublux or dislocate.

When to enlarge the capsulorhexis

Capsulorrhexis enlargement is much safer if performed at the end of the operation when possible. Attempted enlargement before phacoemulsification can be difficult to control and may result in a tear out. After phacoemulsification (but before IOL implantation) the bag is floppy. After the intraocular lens has been implanted a degree of capsular tension is restored. This provides useful counter-traction to the tearing forces. The position of the optic edge is also a useful reference point for sizing the tear.

How to enlarge the capsulorrhexis

The anterior chamber is filled with viscoelastic. An intraocular scissors such as a Ong or Vannas is used to make a tangential nick in the edge of the capsule. Coaxial micro-scissors (21 or 23 G) are a very useful alternative as they cause less wound distortion and gape and may be used through a side port. This nick is extended carefully by shearing (i.e. flap folded over) using forceps. The aim is to create a circumferen-

Illustration 6.19 Capsulorhexis enlargement



This eye has pseudoexfoliation. This small capsulorrhexis increases the risk of late dislocation on the lens and bag. A decision is made to enlarge the capsulorhexis.

Capsular dyes

Figure 6.8 Variability of the red reflex.

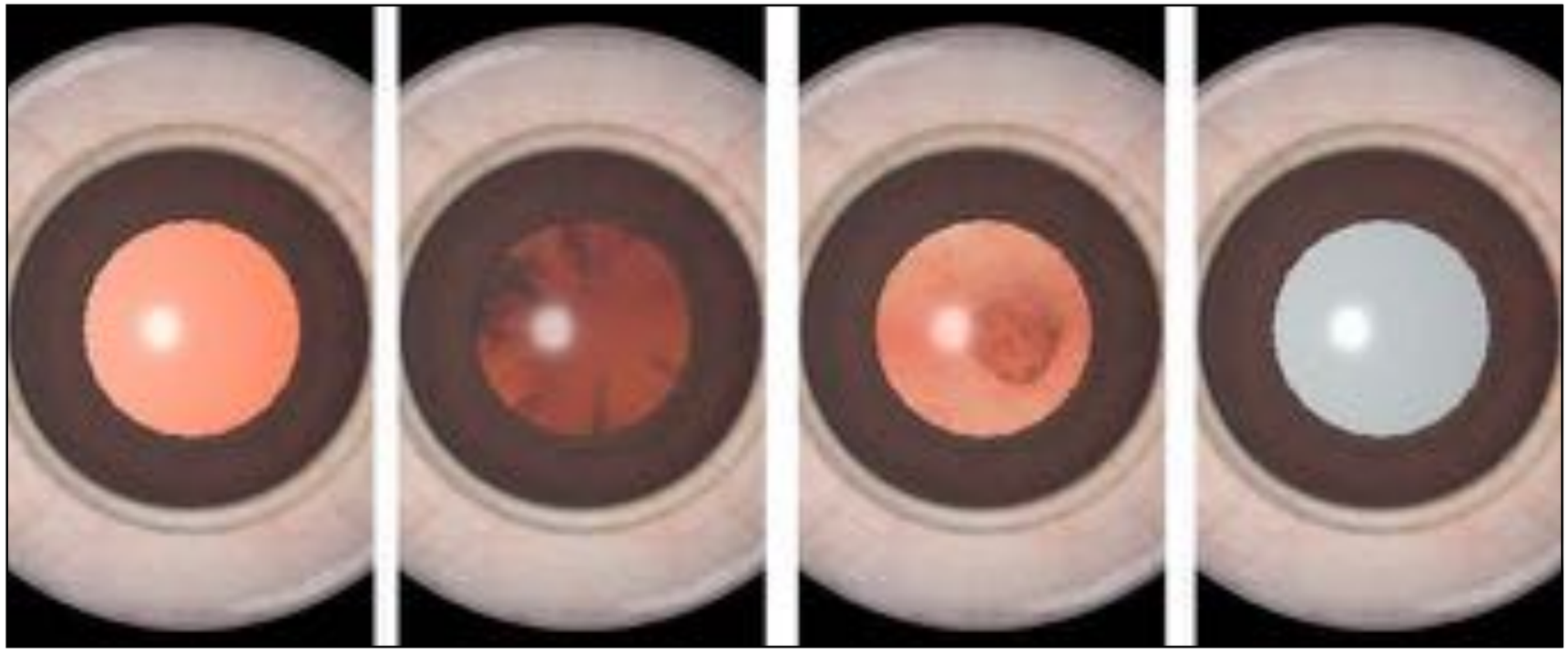

The red reflex in a normal eye and in cortical, posterior subcapsular and mature cataracts.

The anterior capsule of the lens is a basement membrane which takes up vital basement membrane stains injected into the anterior chamber.

Capsular staining

Trypan blue is the most commonly used capsular stain. So called from its ability to kill trypanosomes that cause sleeping sickness.

It may be injected either directly or under a bubble of air to theoretically increase the concentration at the anterior capsule and intensity of staining. In practice the bubble can often displace the dye away from the central capsule towards the periphery so generally direct injection is more reliable. Prolonged contact of up to one minute can increase the intensity of staining.

Ideally the dye should be injected before viscoelastic is introduced. If this is not possible the dye may be injected using a sweeping motion of the cannula under cohesive viscoelastic (this is ineffective under dispersive viscoelastic).

Movie 6.32 Capsular staining technique

Following injection of air the trypan blue is injected and then washed out with saline after allowing contact time of up to one minute.

Increased capsular tension

Figure 6.9 "Mature" cataract

In advanced cataracts the lens contents liquefy and water is osmotically drawn across the lens capsule (which acts as a semi-permeable membrane). This increases the pressure within the lens and therefore the tension within the capsular bag.

The increased capsular tension exacerbates the tendency for the capsulorhexis to run out radially.

A small nick in the capsule may cause the tear to spread very rapidly (if the capsule was previously stained with trypan blue the resulting blue and white bands resemble the national flag of Argentina).

There are two types of strategy to avoid this problem:

- Maintaining a flat anterior capsule throughout the capsulorhexis. This may be achieved by filling the anterior chamber with a highly cohesive viscoelastic and/or minimizing viscoelastic loss through the incision (for example by operating through a side-port).
- Decompressing the capsular bag prior to attempting capsulorhexis (for example by doing a very small initial capsulorhexis and subsequently enlarging it or making a micro-puncture and aspirating some of the fluid lens contents)

These two strategies are often combined in practice.

Movie 6.33 The Argentinian flag

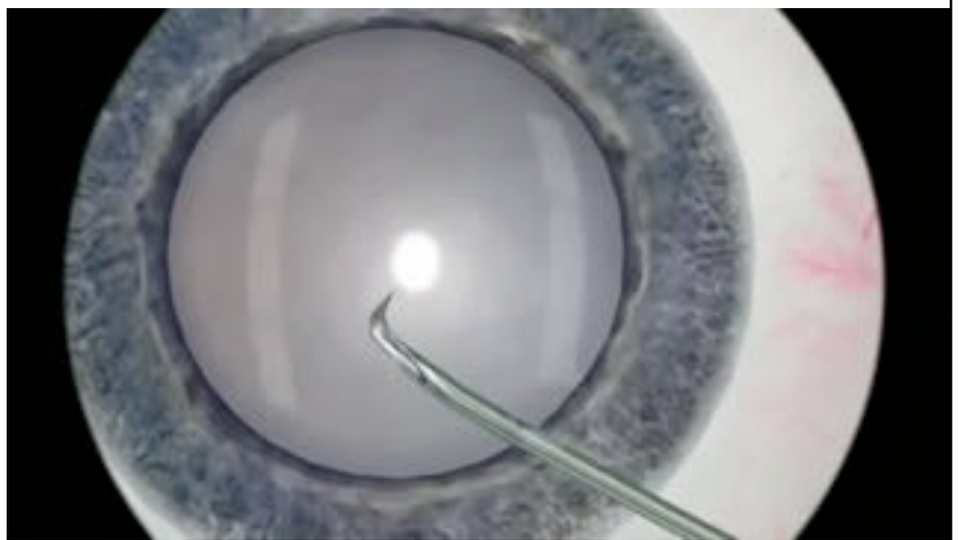

The small nick extends in a second to the equator due to the very high intracapsular tension.

Knowledge review

Review 6.1 Capsulorhexis

Which capsulorhexis is optimal, assuming that a square edged optic IOL 6 mm in diameter is to be inserted?



Check Answer

Review 6.2 Capsulorhexis enlargement

The intraocular lens has been inserted and the capsulorhexis is going to be enlarged. The initial nick is being made with 23G microscissors. Which diagram illustrates the correct point for the capsular incision?

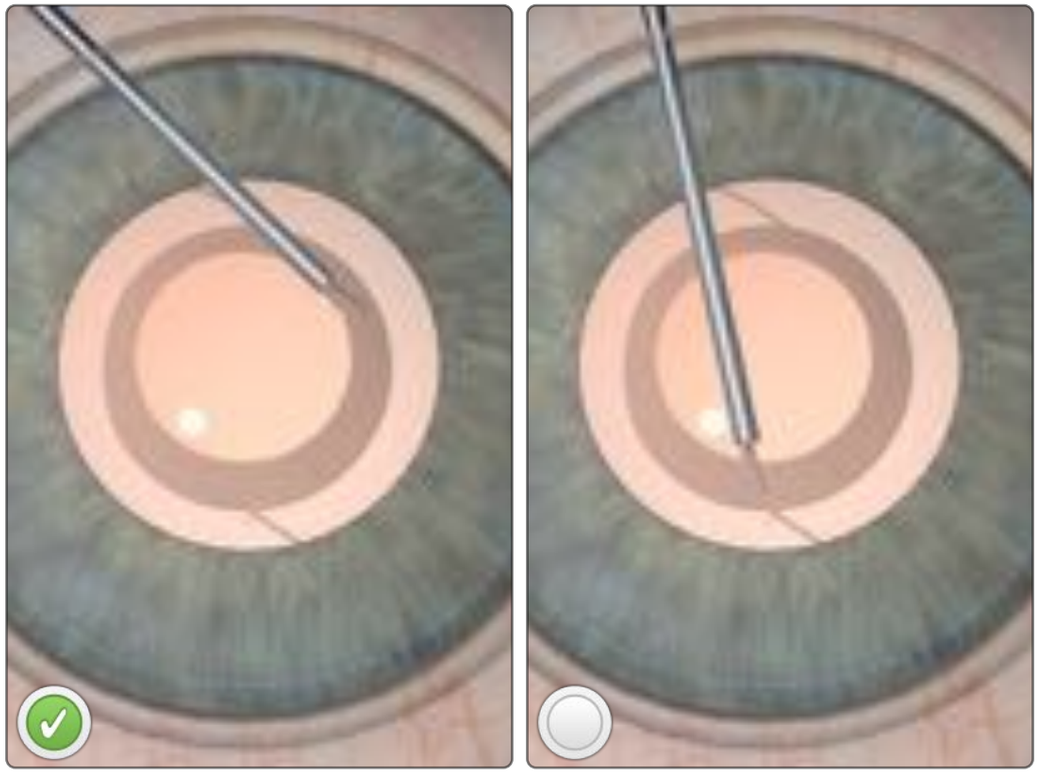

Check Answer

Movie 6.34 Knowledge review - capsulorhexis movie (1)

Look at this video. Why does the capsulorhexis suddenly tear out?

Scroll down for the answer.

Movie 6.35 Knowledge review - capsulorhexis movie (2)

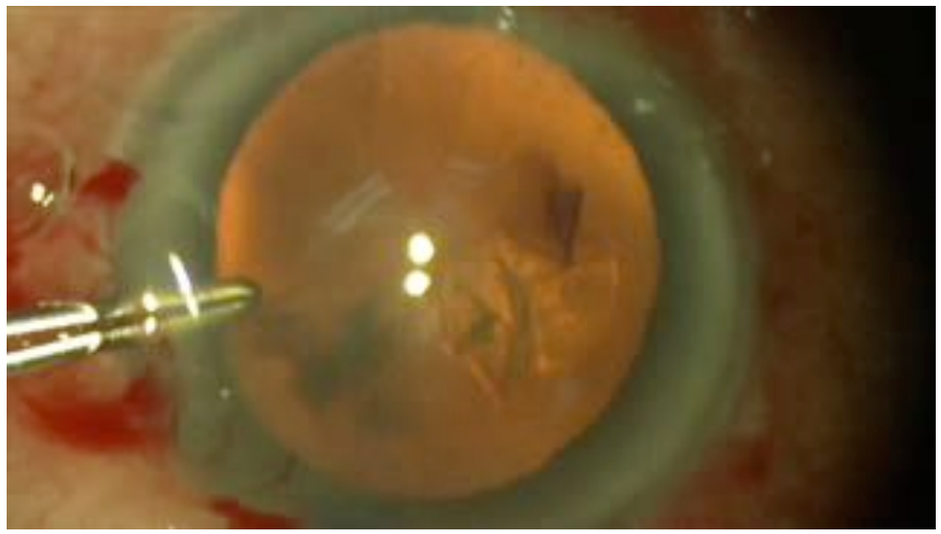

Look at this video. What error is made when grasping the capsulorhexis edge?

Scroll down for the answer.

CHAPTER 7

Hydrodissection

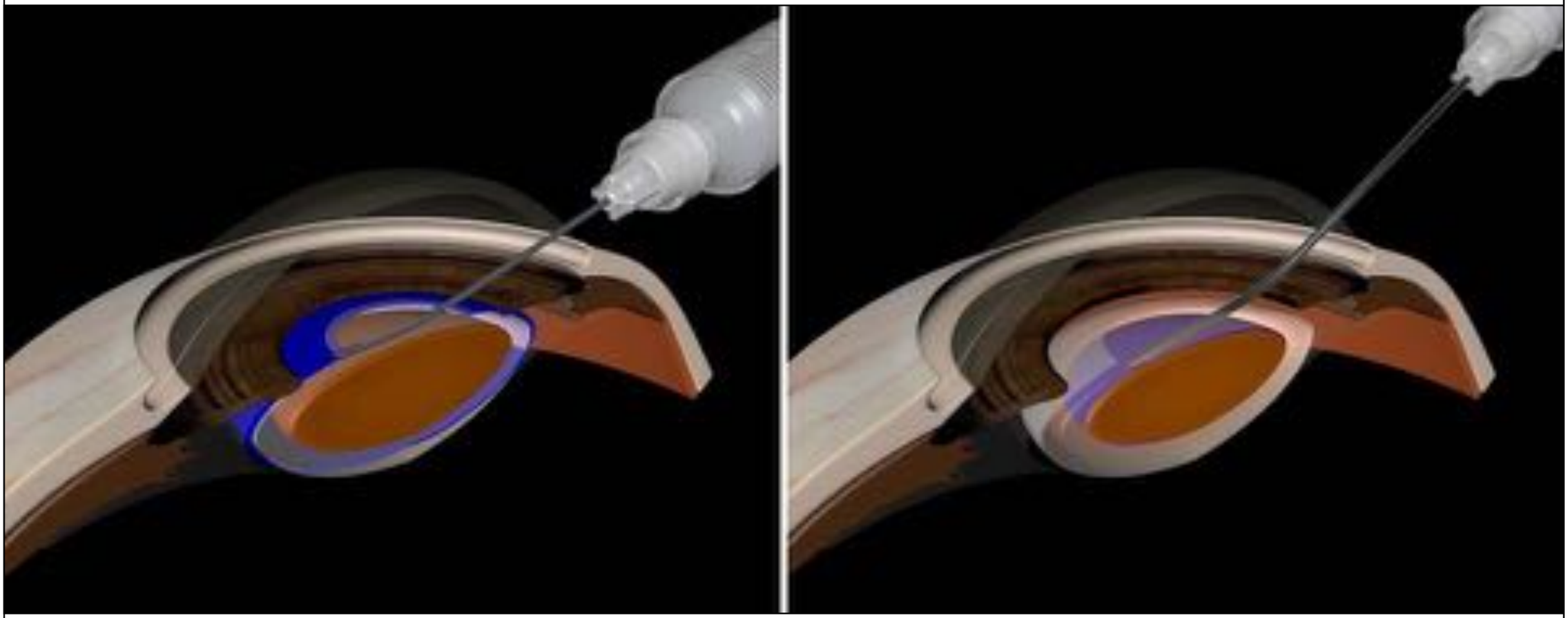

The onion skin-like organization of the layers of the lens cortex are potential cleavage planes which may be opened up by a jet of fluid.

In hydrodissection the cleavage plane is between the capsule and the cortex of the lens.

In hydrodelineation the cleavage plane is between the nucleus and epinucleus.

Hydrodissection

Figure 7.1 Hydrodissection



The cleavage plane is subjacent to the lens capsule.

All strategies for endocapsular nuclear disassembly require the nucleus to be rotatable. This is achieved by sub-capsular cortical cleaving hydrodissection, which breaks the adhesions between the cortex and capsule. If carried out properly (cortical cleaving hydrodissection) very little cortex remains after the epi- and endo-nucleus have been removed.

The cannula should always be attached to the syringe using a Luer lock. Use of an ordinary push fit syringe may turn the cannula into a projectile shot into the eye by the force of the injection. A Pierce type cannula with a flattened tip delivers a fan-shaped jet of water which is more efficient at separating the cortico-capsular adhesions that a round-profiled cannula.

Illustration 7.1 Cannulas

A Luer lock syringe should be used whenever injecting into the eye.



What is cortical cleaving hydrodissection?

In cortical cleaving hydrodissection, the wave of fluid travels adjacent to the capsule rather than between two lamellae of cortex.

Benefits of cortical cleaving hydrodissection are:

- Less cortical clean up during irrigation/aspiration.
- Easier rotation of the nucleus (as there is less friction between the smooth capsule and a cortical lamella than there is between 2 cortical lamellae).

Illustration 7.2 Cortical Cleaving Hydrodissection

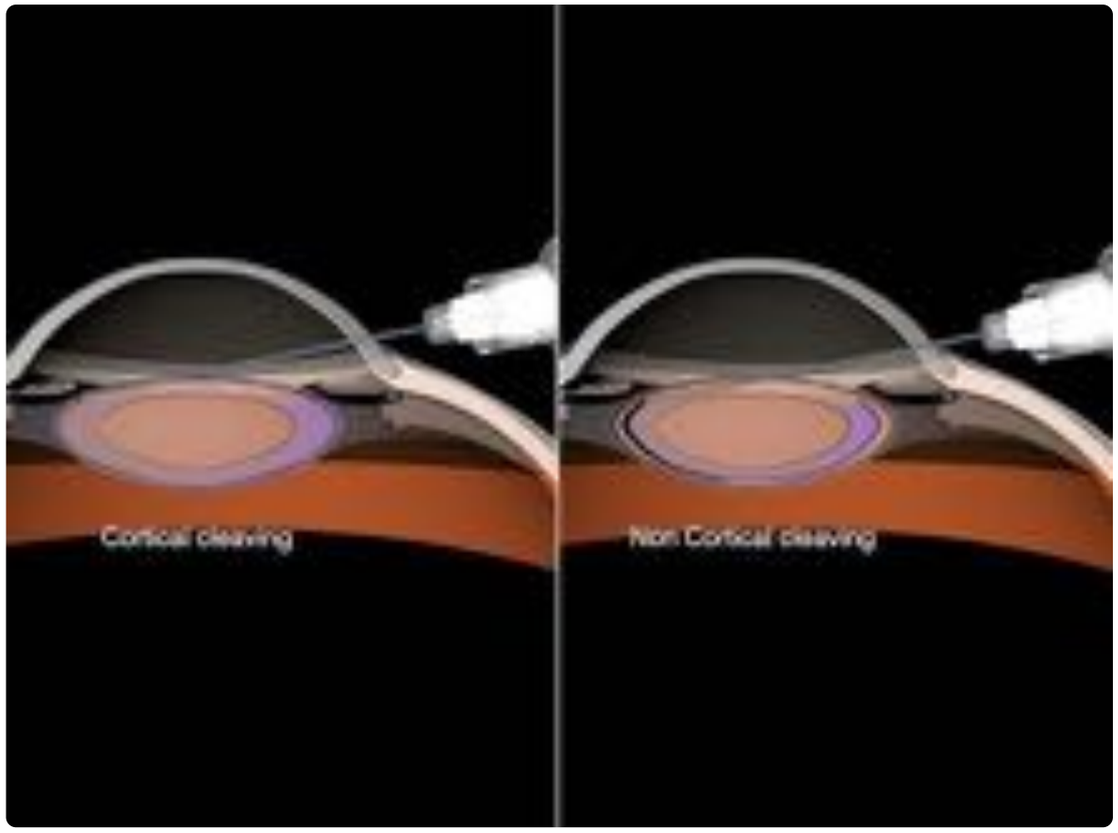

Cortical cleaving hydrodissection cleaves in the subcapsular plane.

Placement of the cannula

The cannula is introduced through the main incision. This allows fluid to escape around the cannula during injection. Many surgeons prefer to evacuate some of the viscoelastic *before* initiating hydrodissection to lower the resistance to outflow of the injected fluid.

The tip of the cannula is advanced under the capsular rim.

The cannula is angled perpendicular to the capsular rim so that the jet of fluid is directed towards the lens periphery.

Illustration 7.3 The cannula through the main incision



The cannula is introduced through the main incision rather than a side port to allow viscoelastic to escape from the eye (blue arrow) during injection.

Illustration 7.4 Cannula placement

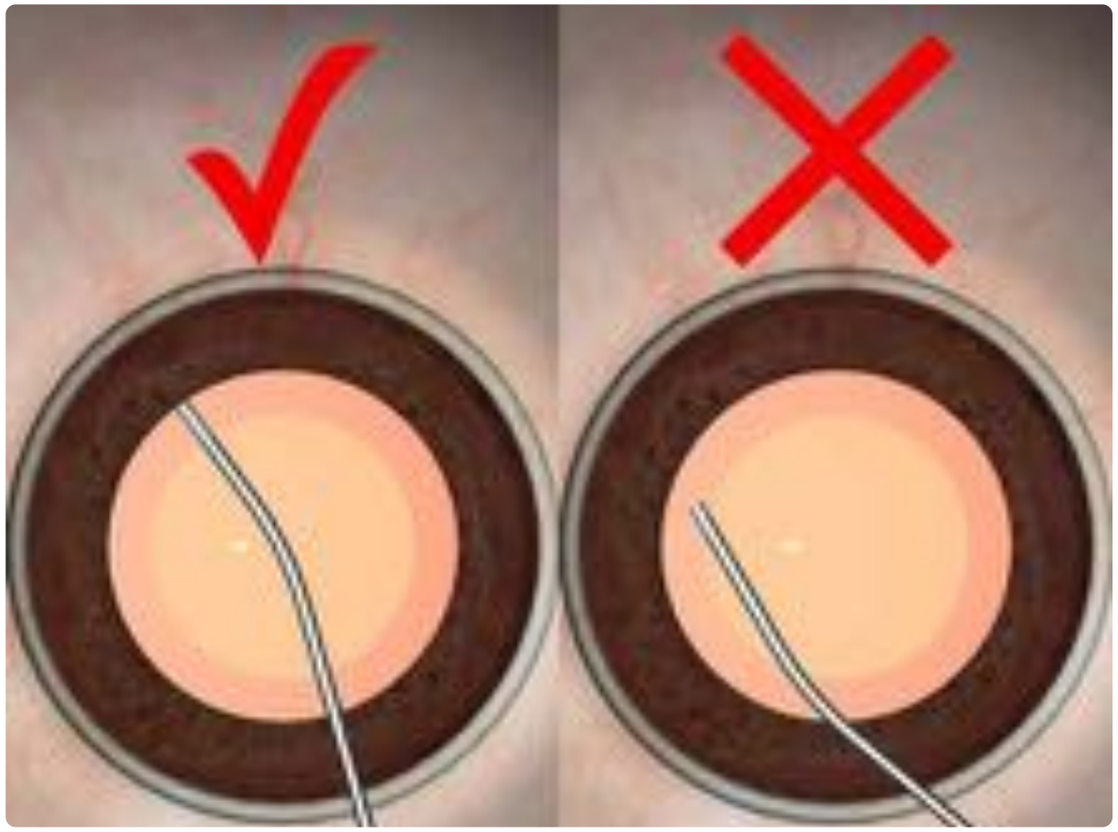

The cannula on the right is too obliquely angled and does not penetrate far enough under the capsule. The eccentric position of the shaft will make it harder to reposition the nucleus if it tumbles forward through the capsulorhexis.

Getting into the subcapsular plane

A simple manoeuvre for getting into the subcapsular plane (so that the fluid wave passes between the capsule and peripheral cortex):

- The cannula tip is peripherally.
- The tip is slowly withdrawn while gently pressing down.
- As the tip retracts over the edge of the capsulorrhexis it drops down into the superficial cortex and a small amount of fluid is seen to travel under the capsular edge.
- The cannula can then be advanced in the subcapsular plane.

Movie 7.1 Getting into the subcapsular plane

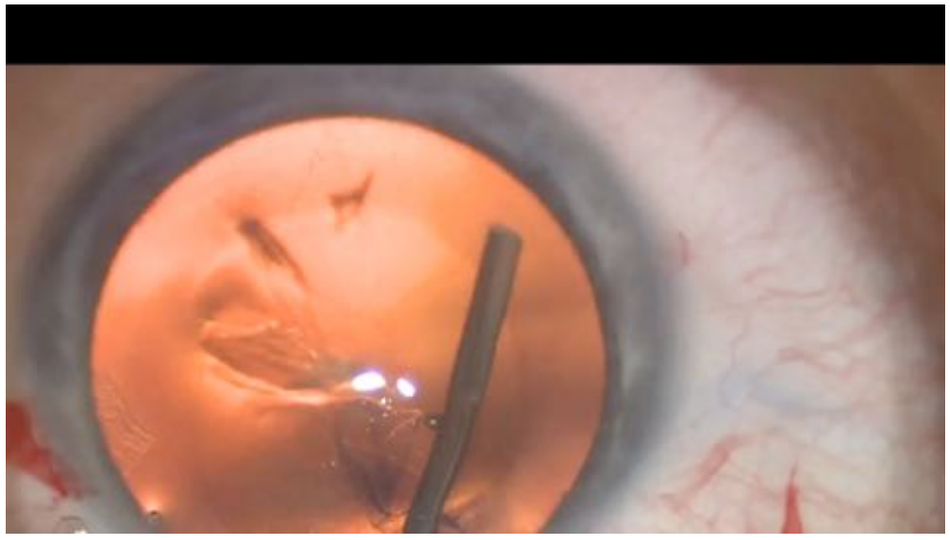

Note the small cleft that appears as the cannula sinks into the subcapsular plane.

Hydrodissection - position of the cannula tip

The cannula tip is lifted up slightly before injecting so that the capsule visibly tents up. This ensures that the plane of cleavage is immediately sub-capsular.

If this is not done the cleavage plane is within the cortex. There is more resistance to rotation between two plates of cortex than between the cortex and the smoother capsule.

As the injection proceeds a wave of opacity is seen progressively crossing the red reflex as the fluid wave passes around the posterior pole of the lens.

Movie 7.4 Hydrodissection animation

Notice that the anterior capsule is tented up prior to injecting.

Illustration 7.5 Capsular tenting



Lifting the tip of the cannula tents the capsule which ensures the hydrodissection is cortical cleaving (i.e. the cleavage plane is between the capsule and the outer layer of cortex).

Movie 7.2 Tenting the capsule up

Note the movement of the capsule and iris as the cannula is brought into the subcapsular plane.

Movie 7.3 The hydrodissection wave

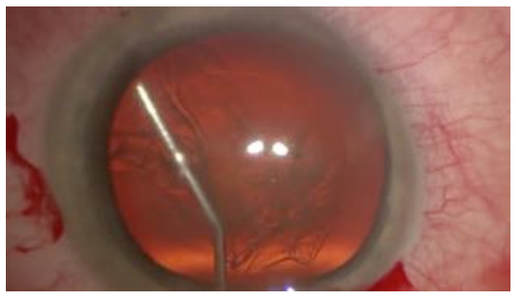

In this eye with a good red reflex the leading edge of the wave is easily seen as an expanding dark ring.

Hydrodissection - intraoperative capsule block

The cleavage wave enlarges around the lens. It encounters resistance at the equator where the cortex is quite adherent to the capsule (the equatorial cortico-capsular adhesions). If injection continues a fluid pocket builds up over the posterior capsule. The trapped fluid pushes the nucleus forward, the so-called 'nuclear lift', thereby stretching the capsulorhexis. This is a normal component of hydrodissection.

What happens next depends on the action taken by the surgeon and the size of the capsulorhexis.

Movie 7.5 Intraoperative capsule block

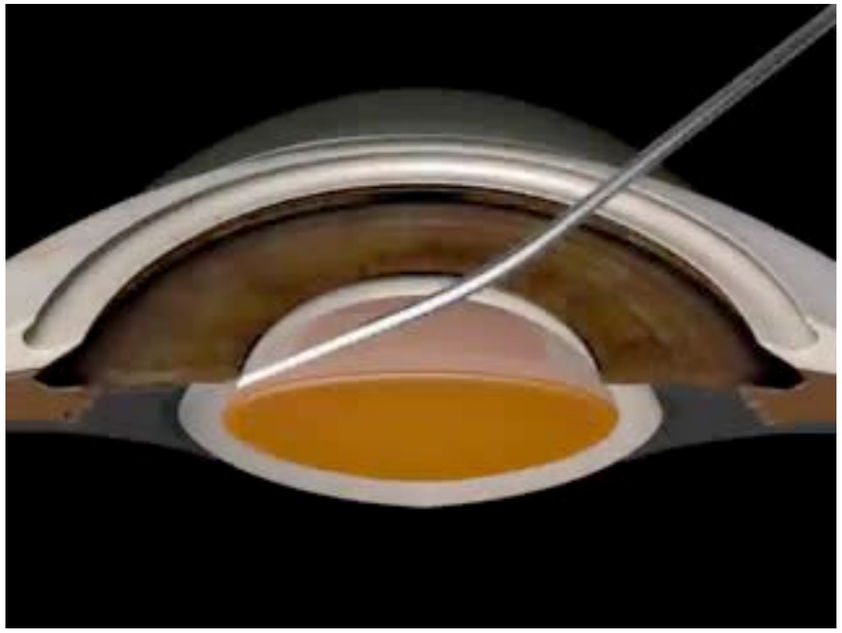

Because of resistance in the equatorial region the fluid is trapped and builds up posteriorly.

Movie 7.6 Intraoperative capsule block

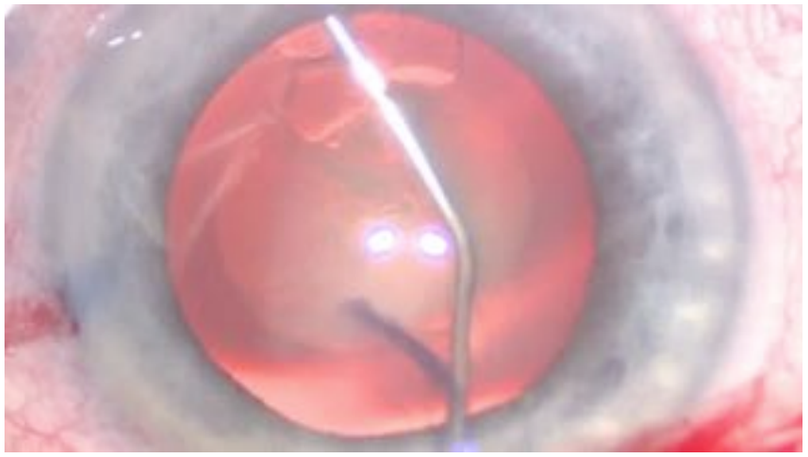

Notice how after the fluid wave travels around the back of the lens the nucleus is pushed forward, stretching the capsule.

Hydrodissection - treating intraoperative capsule block

The correct action once the fluid wave has traversed the red reflex is to stop injecting and push downwards the centre of the nucleus. The trapped fluid is displaced anteriorly, breaking the remaining cortico-capsular adhesions and completing the hydrodissection. It is usually necessary to repeat this at least once in another distal quadrant to ensure all the cortico-capsular adhesions are broken.

Movie 7.7 Capsule block - balloting the nucleus

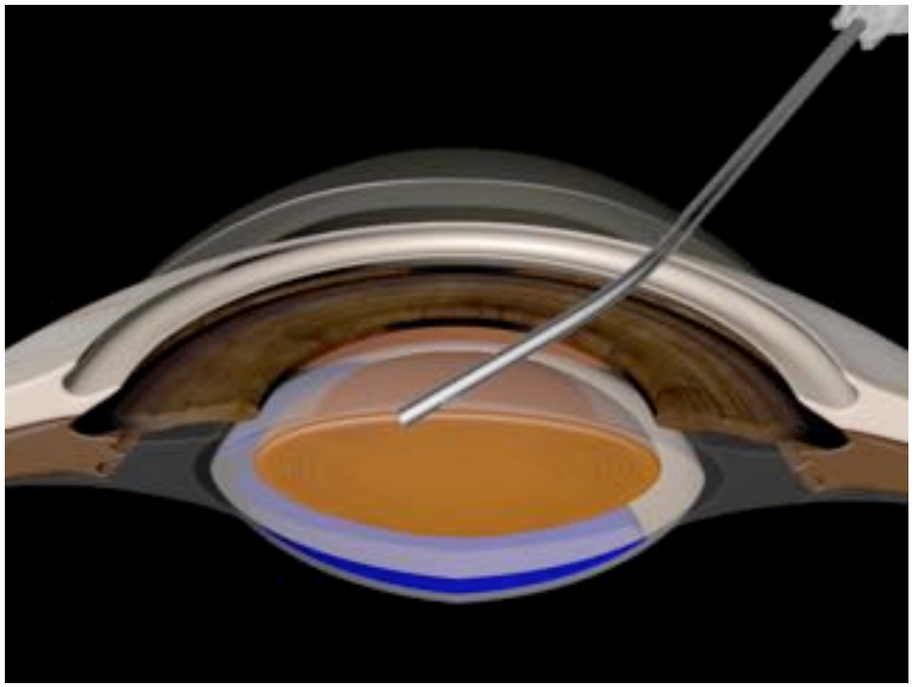

Movie 7.8 Capsule block - balloting the nucleus

Pushing the nucleus downwards after the fluid wave has crossed the red reflex and as soon as the capsulorhexis starts to stretch.

Hydrodissection - consequences of intraoperative capsule block

If the capsulorhexis is large the nucleus may prolapse through it into the anterior chamber.

The nucleus can usually be reposited fairly easily using dispersive viscoelastic and the hydrodissection cannula. If this is impossible the nucleus may be phacoemulsified in the anterior chamber. It is advisable to inject a dispersive viscoelastic between the lens and the cornea to protect the endothelium.

The major consequence of nuclear prolapse is that the hydrodissection wave is incomplete with residual cortico-capsular adhesions. The hydrodissection has to be repeated at several sites to achieve a mobile nucleus.

Movie 7.9 Hydrodissection - nuclear prolapse

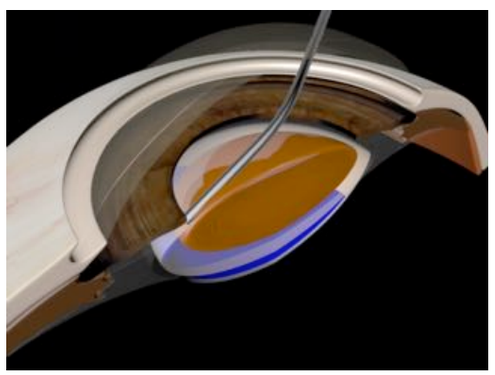

Note that the hydrodissection wave is incomplete.

Movie 7.10 Nuclear prolapse into the anterior chamber

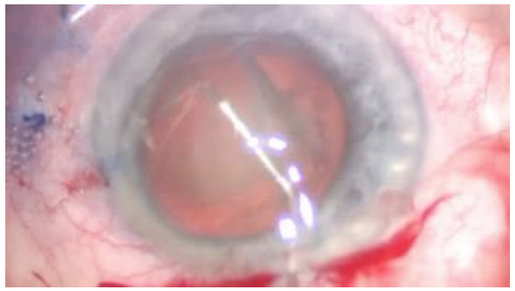

Failure to ballot the nucleus - progressive fluid accumulation behind the nucleus pushes it through the capsulorhexis.

Movie 7.11 Management of nuclear prolapse

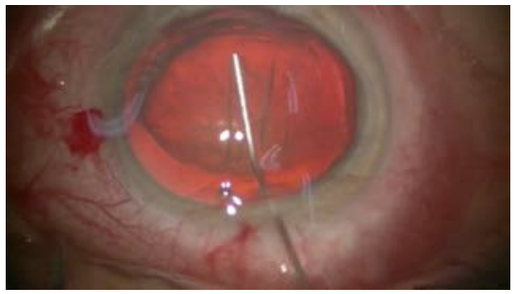

The nucleus an normally be reposited fairly easily.

Movie 7.12 Iris plane phacoemulsification

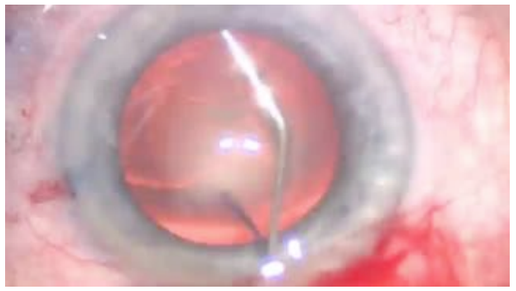

Several unsuccessful attempts are made to reposit this nucleus. Finally it is rotated to bring it fully into the anterior chamber and phacoemulsified in the anterior chamber under dispersive viscoelastic. Nuclei which behave in this way tend to be soft and minimal ultrasound energy was required. The cornea had minimal edema on the first postoperative day which quickly cleared.

Hydrodissection - consequences of intraoperative capsule block

Rapid injection in the presence of a small capsulorhexis can split the posterior capsule.

Firstly nuclear lift from hydrodissection blocks the capsulorhexis opening. If injection of fluid continues, the anterior chamber initially continues to shallow as the nucleus is pushed forward and then it very suddenly deepens at the moment the posterior capsule splits, accompanied by rapid shut-down of the pupil. This is the Pupil Snap sign.

Movie 7.13 The pupil snap sign

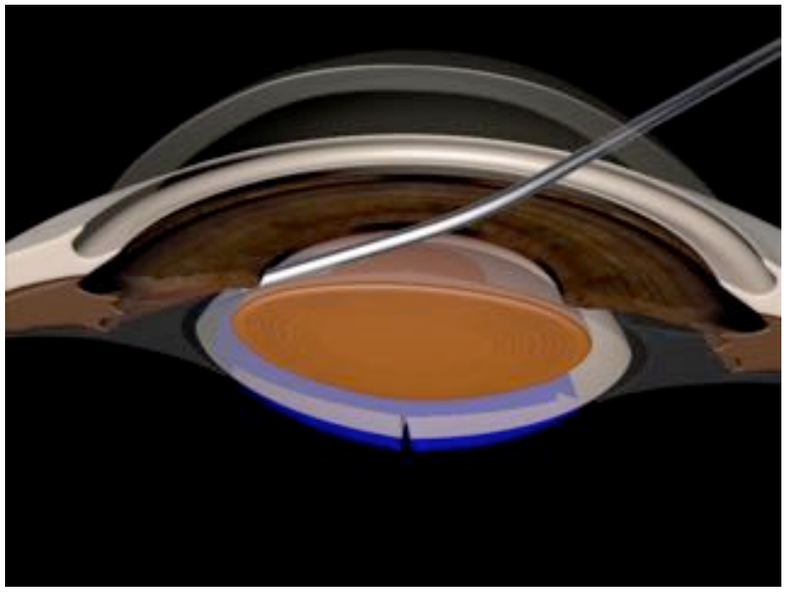

The changes in pupil diameter are a consequence of distention and then deflation of the capsular bag.

Movie 7.14 The pupil snap sign

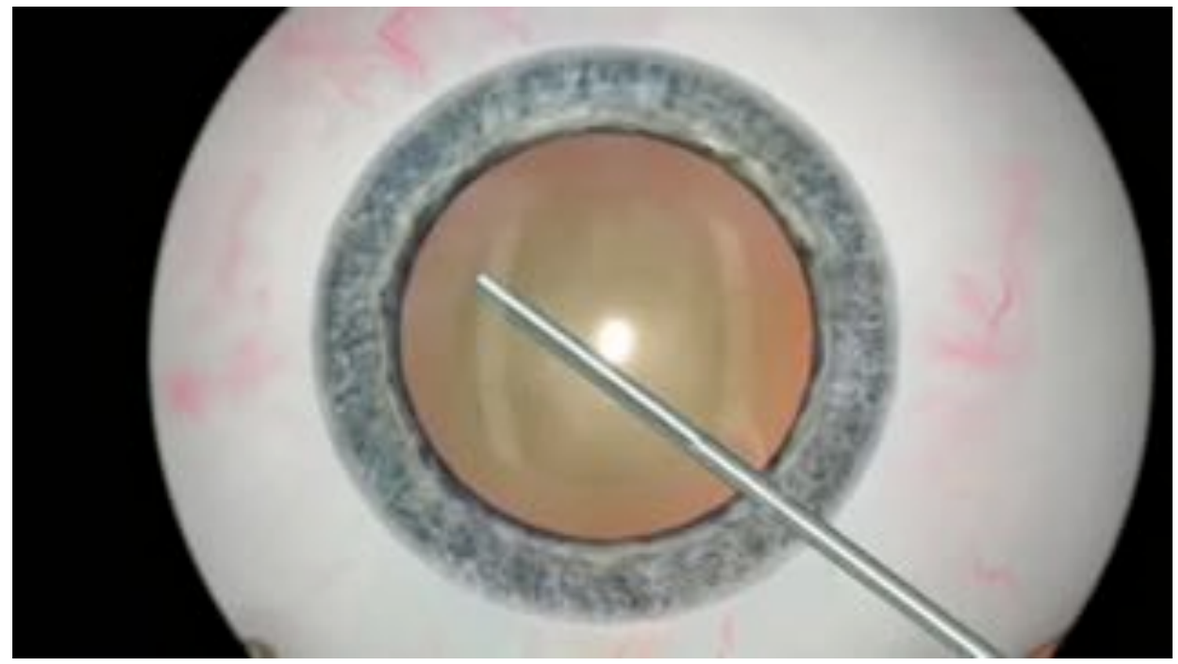

The change in diameter of the pupil is very rapid.

Assessing completeness of hydrodissection

If a complete cortical cleaving hydrodissection has been achieved the lens should rotate easily within the capsular bag. It is worth making sure that the nucleus spins freely before proceeding to phacoemulsification.

Inability to rotate the nucleus indicates that some cortico-capsular adhesions remain and hydrodissection should be repeated at another site. Failure to do this has two consequences:

- Manipulation of the nucleus stresses the zonules.
- Attempts to rotate the nucleus after grooving cause the central parts of the nucleus to break off. This leaves a bowl of peripheral nucleus which is much more difficult to remove than a nucleus that has been systematically disassembled by chopping or cracking.

Movie 7.15 Confirmation of successful hydrodissection

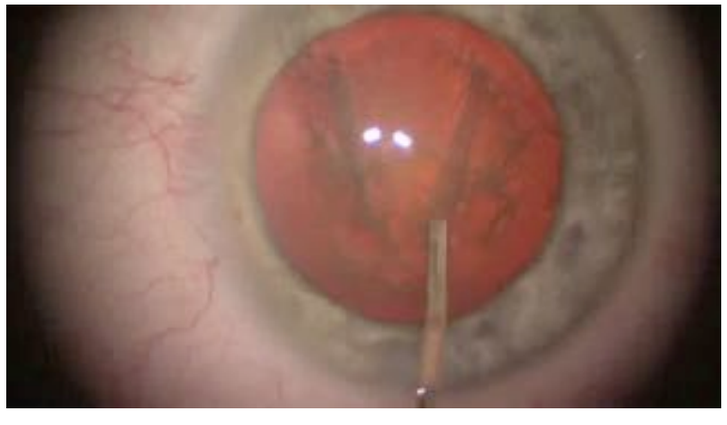

It is worth checking that the nucleus is freely mobile before proceeding to the next step

Movie 7.16 Failure to rotate the nucleus

Incomplete cortical cleaving hydrodissection leads to difficulty rotating the nucleus.

Hydrodelineation

Figure 7.2 Hydrodelineation

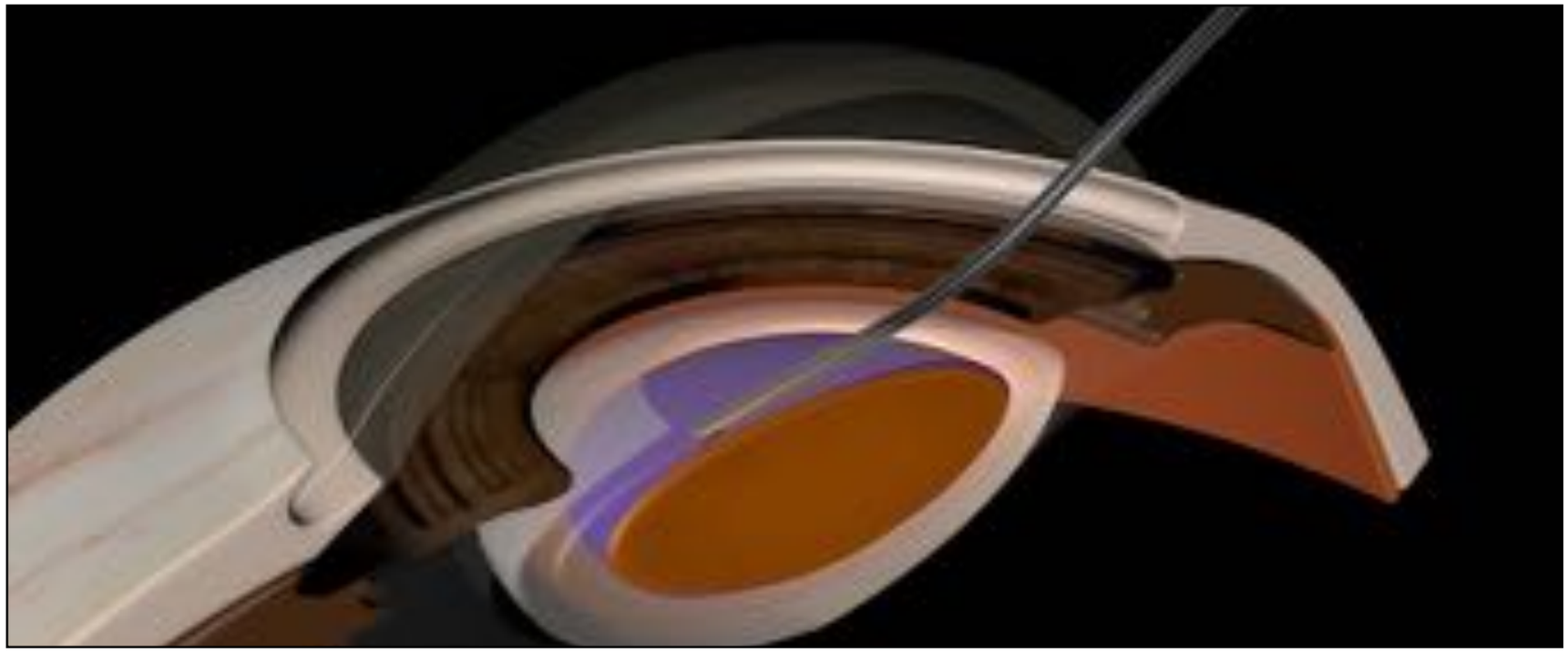

The cleavage plane is around the nucleus.

Hydrodelineation defines and separates the endonucleus creating an outer safety cushion of epinucleus and cortex. This protects the posterior capsule while the nucleus is being disassembled.

Hydrodelineation

The cannula is pressed downward and forward into the lens through the epinucleus. When it encounters the harder endonucleus the lens moves slightly. The cannula is moved forward over the surface of the endonucleus, then withdrawn slightly. Injection of fluid creates a fluid wave which tracks around the endonucleus. A refractile "golden ring" is often seen around the endonucleus - this arises from bright specular reflections from the fluid/lens interface.

As when performing hydrodissection the maneuver may need to be repeated several times at different points.

If the endonucleus is large the golden ring may be obscured by the iris.

Movie 7.17 Hydrodelineation

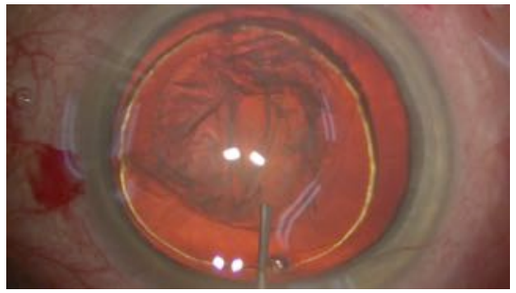

Note the golden ring around the endonucleus.

Movie 7.18 Hydrodelineation

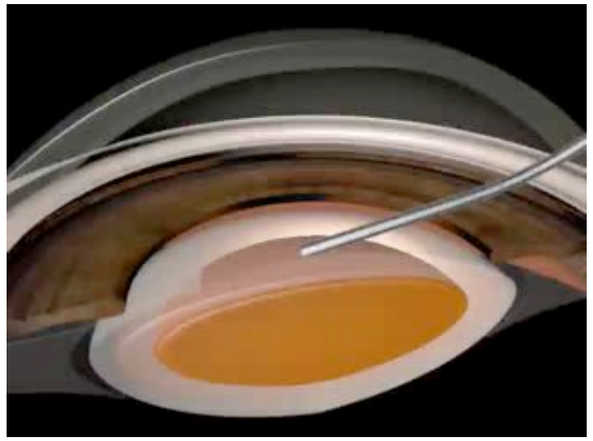

The lens moves when the cannula encounters the endonucleus.

Movie 7.19 The purpose of hydrodelineation

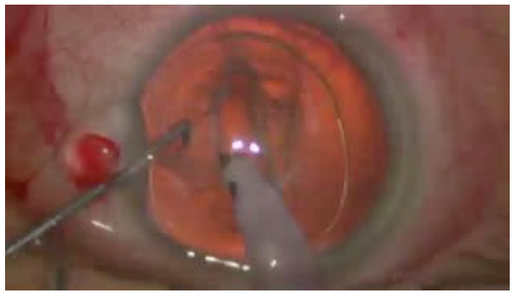

The separation between the endonucleus and the softer protective epinuclear shell is well seen when this soft nucleus is cracked.

Capsular abnormalities

Figure 7.3 Posterior polar cataract



Subcapsular hydrodissection should *not* be carried out in the presence of known or suspected posterior capsule defects or strong capsular adhesions at the posterior lens pole.

Posterior polar abnormalities which preclude hydro-dissection include:

- Congenital abnormalities (posterior polar cataract).
- Acquired capsular defects due to trauma (including surgical trauma during vitrectomy)

Illustration 7.6 Capsular defects

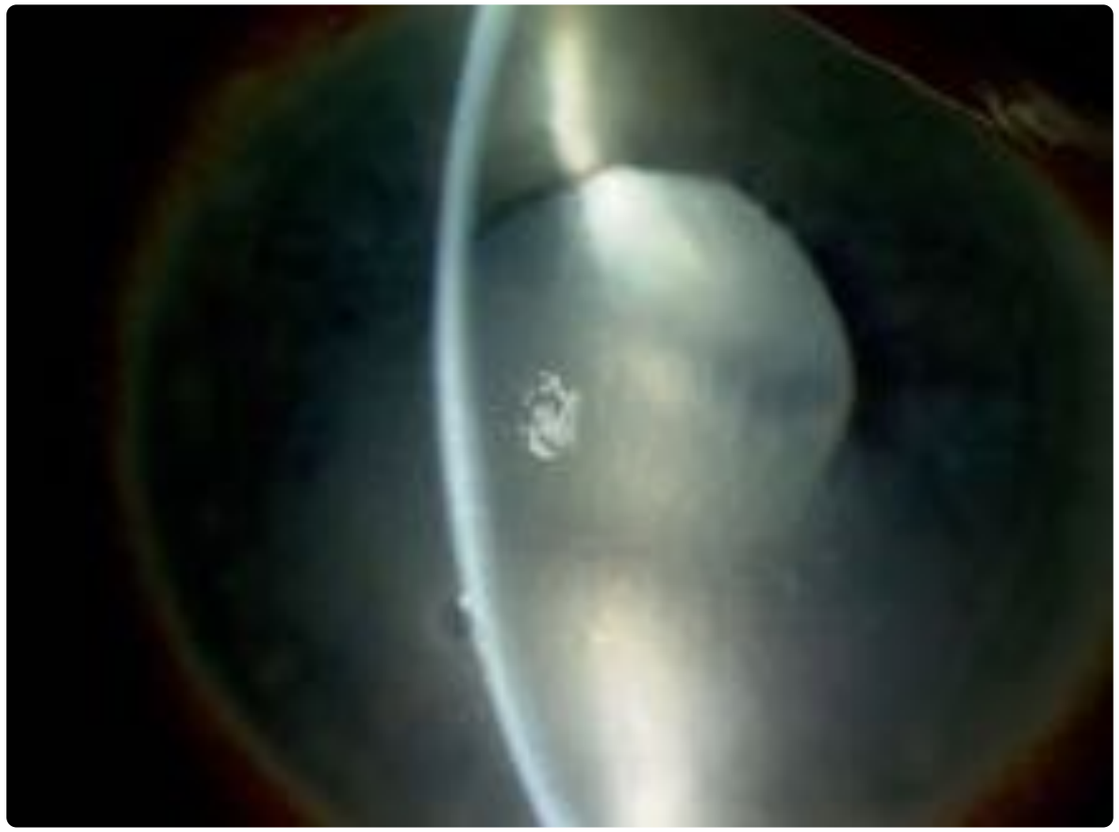

Phacolysis following iatrogenic trauma during vitrectomy. Water enters the eye through the capsular defect. Lens material leaks out of the defect. Lens material in the anterior chamber blocks the trabecular meshwork causing glaucoma. It also excites an immune response because the lens crystallins and other proteins, immunologically sequestered during development, are recognized as immunologically alien.

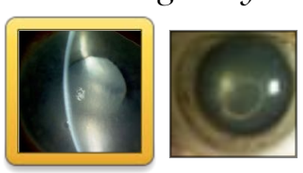

Management of capsular abnormalities

There are several strategies for the management of cataracts with capsular defects.

Large capsular defects are best managed by vitreolensectomy.

Adherent plaques may be managed by phacoemulsification using hydrodelineation alone, particularly if (as is often the case) the nucleus is soft. Following aspiration of the endonucleus the adherent cortex may be stripped off the capsule around the plaque using viscoelastic.

Movie 7.20 Hydrodelineation

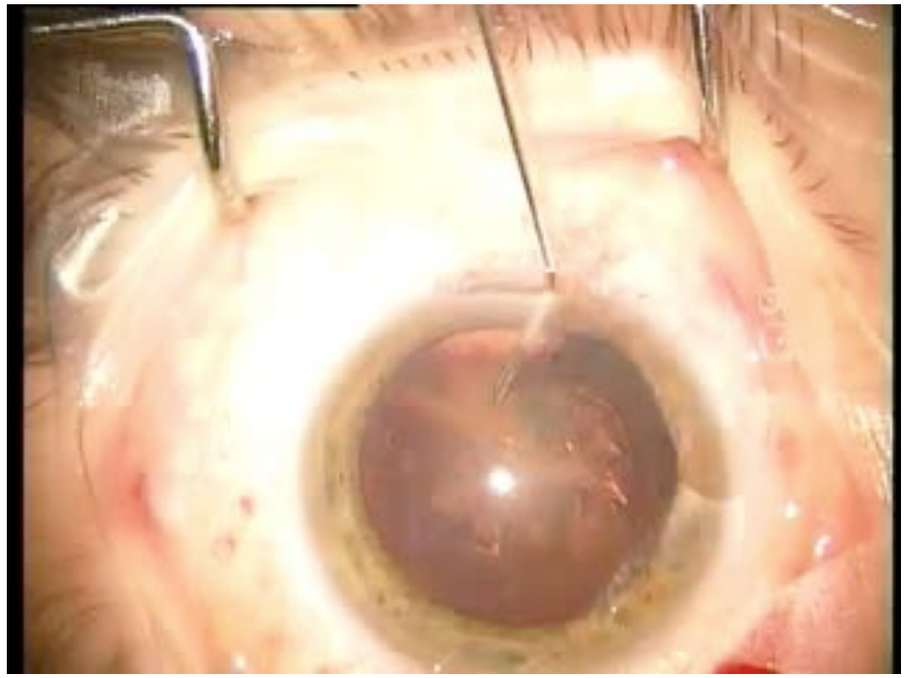

This patient had an adherent capsular plaque following vitrectomy. Hydrodelineation is performed without hydrodissection.

Movie 7.21 Viscodissection

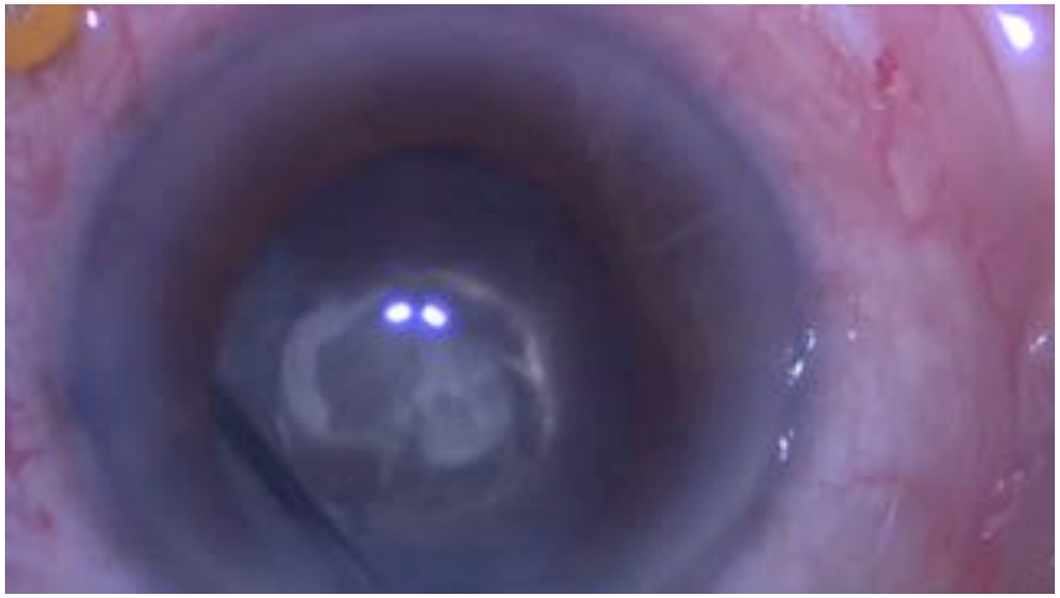

This is a posterior polar cataract. The fellow eye had suffered posterior capsule rupture with a dropped nucleus. This eye was successfully managed be performing hydrodelineation, removing the nucleus and then viscodissection to strip the cortical lens matter off the capsule.

Knowledge review

Review 7.1 Hydrodissection

Which of these statements is correct?

- **A.** Use of a luer lock cannula is contraindicated.
- ✓ **B.** In cortical cleaving hydrodissection the cleavage plane is adjacent to the capsule.
- **C.** The capsule should not be tented up prior to injection
- **D.** If a golden ring is not seen during hydrodelineation it is unlikely to be complete

Check Answer

Review 7.2 Hydrodissection

In which of these images is the cannula in the best position for cortical cleaving hydrodissection?

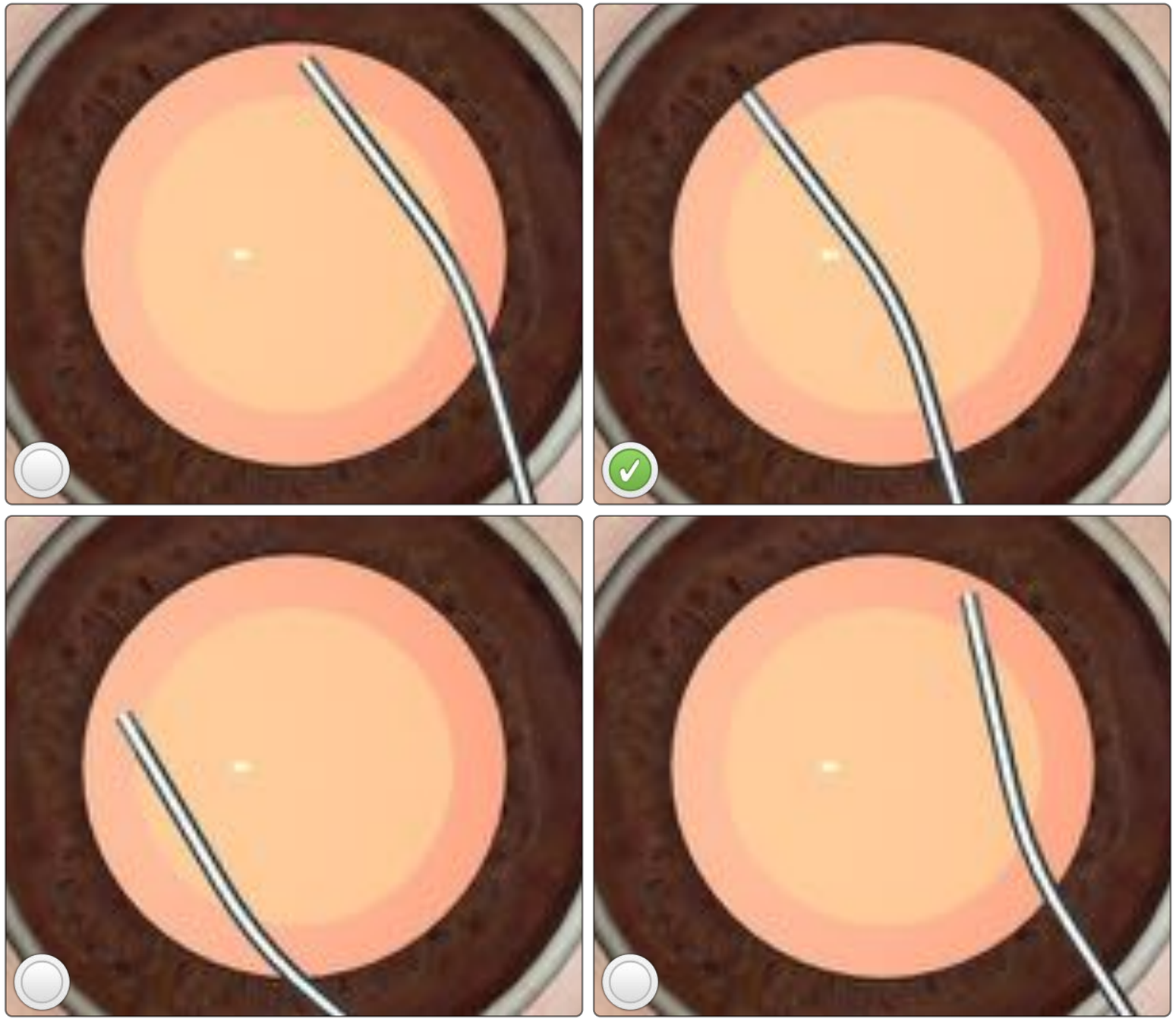

Check Answer

Movie 7.22 Knowledge review - hydrodissection movie (1)

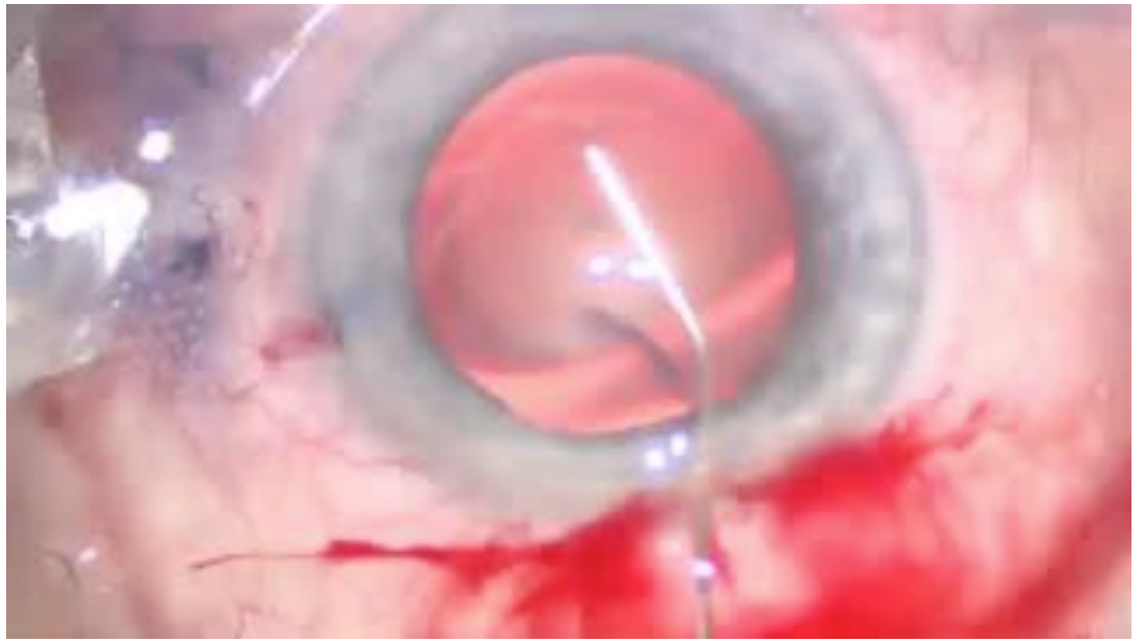

Look at this video.

1. Why has this happened?

2. What are the implications for the completeness of hydrodissection?

3. How should it be managed

Scroll down for the answer.

Movie 7.23 Knowledge review - hydrodissection movie (2)

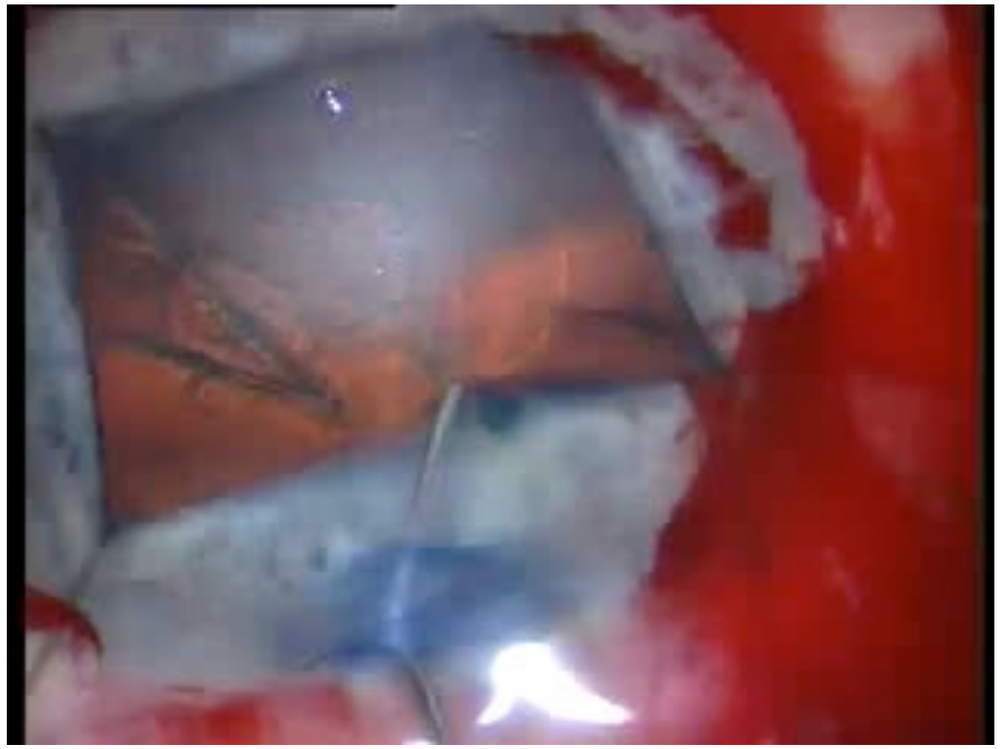

Look at this video.

1. What has happened?

2. What is the likely cause?

Scroll down for the answer.

Movie 7.24 Knowledge review - hydrodissection movie (3)

Look at this video.

What is unusual about this cataract?

How should it be managed?

Go to the next page for the answers

Movie 7.25 Management of posterior polar cataract

Hydrodissection is avoided. Hydrolineation is performed. The nucleus is very soft and is sliced using a chopper. Removal of the epinucleus creates space centrally. This allows viscodissection to separate the epinucleus from the capsule.

This is a posterior polar cataract.

Hydrodissection should be avoided.

The video on the left of this box illustrates how it should be managed.

CHAPTER 8

Nuclear Disassembly-Divide and Conquer

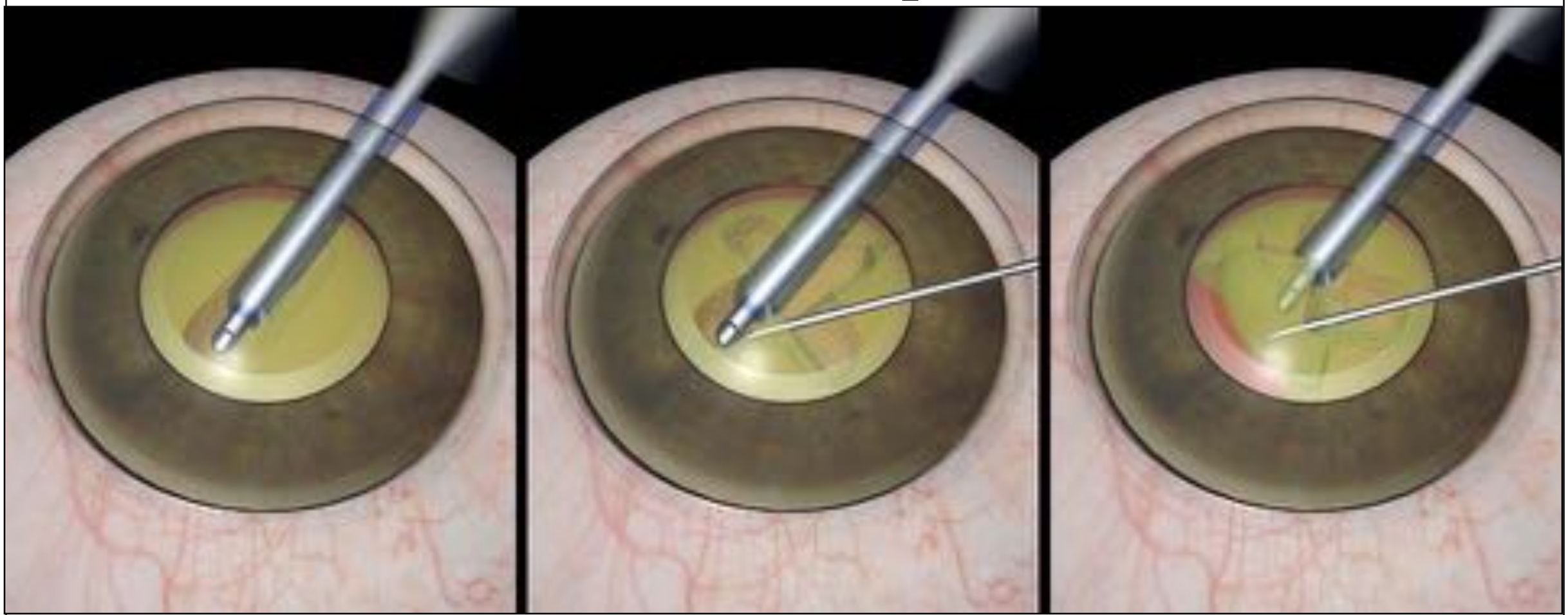

Divide and conquer is often the first technique learnt by trainees. It is still many surgeons' preferred technique. It provides a useful fallback when other techniques fail.

Sculpting

Figure 8.1 Nuclear sculpting

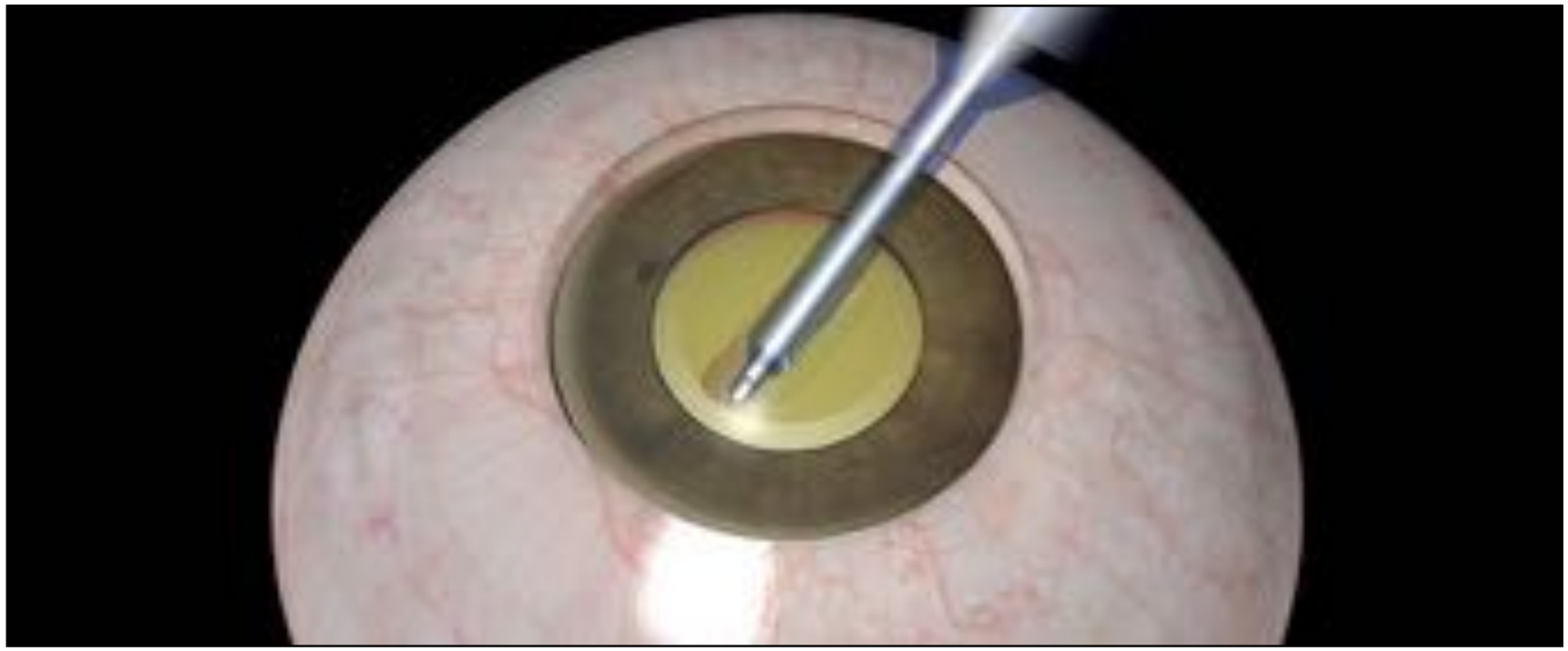

Sculpting is the creation of a succession of grooves in the nucleus to form a trench.

The depth, width, length and cross sectional profile of the trench determine the ease with which the nucleus can be cracked.

Correct use of phacoemulsification power and aspiration as well as correct orientation of the probe help to achieve these goals.

Preparation for sculpting

The nucleus should be freely rotatable.

The soft lens material (cortex and epinucleus) within the capsulorhexis rim is aspirated out of the way so that the phacoemulsification probe has access to the endonucleus.

Illustration 8.1 Clearing the epinuclear material



This is performed with aspiration and exposes the endonucleus.

Movie 8.1 Clearing the epinuclear material

Note that the phacoemulsification probe enters the eye with infusion activated (foot position 1).

Sculpting - general principles

- The trench is deepened using shallow grooves. Occlusion of the tip of the phacoemulsification probe should be avoided.
- Movements of the phacoemulsification probe should pivot around the incision ('wound neutrality').
- Aspiration should not be excessive - just sufficient to clear emulsified lens material.
- Irrigation should be initiated before the phacoemulsification probe enters the eye. It should remain active as long as the probe is in the eye. The irrigation level should be sufficient to maintain the anterior chamber depth. Use of the 'continuous irrigation' setting is the most reliable way of avoiding chamber collapse.
- The nucleus should not move during sculpting. If the nucleus starts to move the probe should be moved more slowly or the ultrasound power increased or the depth of the pass decreased or any combination thereof.

Movie 8.2 Foot position during sculpting

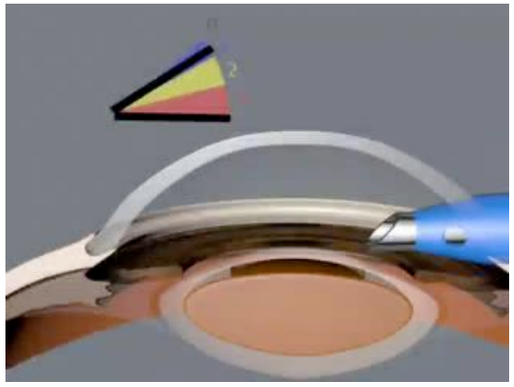

Foot position 3 is engaged only while sculpting. At all other times foot position 1 is used.

Illustration 8.2 Nuclear engagement

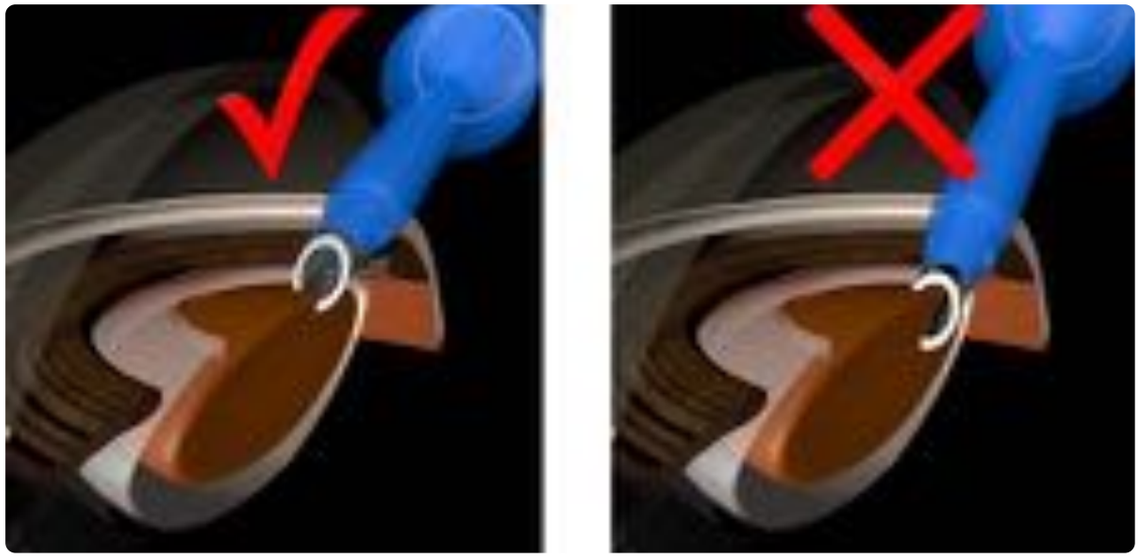

The nucleus should be devoured delicately in thin slivers rather than 'wolfed down'. Occlusion of the tip of the probe (right) is undesirable.

Sculpting - orientation and trench length

The initial groove starts just under the incision, past the edge of the capsulorhexis. It is then extended along the surface of the nucleus past the mid point to the other side, just short of the capsulorhexis edge.It should be as long as possible within the constraints imposed by the capsulorhexis diameter.

Subsequent passes of the phacoemulsification probe deepen and widen this groove to make a trench. It should be wide enough to freely accommodate the width of the irrigation sleeve to avoid friction on the sidewalls of the groove causing unwanted movement of the lens. These passes may be made *slightly* longer than the most superficial groove as there is no risk of damage to the edge of the capsulorhexis. Care must be taken not to pass through the periphery of the endonucleus. If the

Illustration 8.3 Length and orientation of the grooves

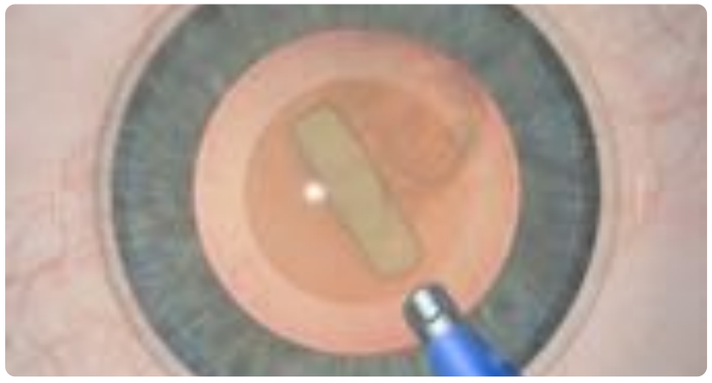

The first groove starts just central to the capsulorhexis edge. It passes via the mid point the the opposite edge. Note that these superficial grooves are well within the capsulorrhexis.

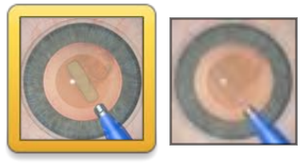

Illustration 8.4 The final length

The end result of several grooves is a cruciate trench. This nucleus is ready for cracking. The deeper grooves extend the trench slightly more peripherally but do not need to go to the end of the nucleus.

Movie 8.4 Length of the groove

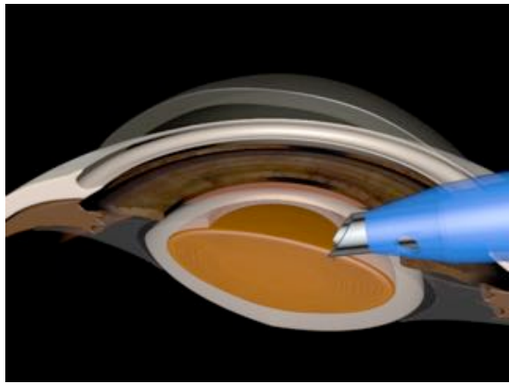

The groove is deepened to form a trench. While the first groove is constrained by the capsulorrhexis diameter the deeper grooves may extend more peripherally.

Movie 8.3 Length of the grooves

The first groove ends within the capsulorhexis. Later grooves are extended more peripherally but no too deep - once the red reflex changes the trench is deepened centrally

Sculpting - width of the trench

The width of the initial groove is equal to the width of the tip of the needle of the probe. It must be widened before making deeper grooves to allow passage of the infusion sleeve. Failure to do this, particularly if the nucleus is quite tough, causes the infusion sleeve to get jammed in the groove. The whole lens then starts to move when an attempt is made to deepen the trench.

In soft nuclei the trench should not be made too wide if it is cruciate as in divide and conquer, otherwise the nucleus may disintegrate into a bowl during cracking.

Widening the groove slightly also makes space for a second instrument when the nucleus is cracked.

Illustration 8.5 Trench width

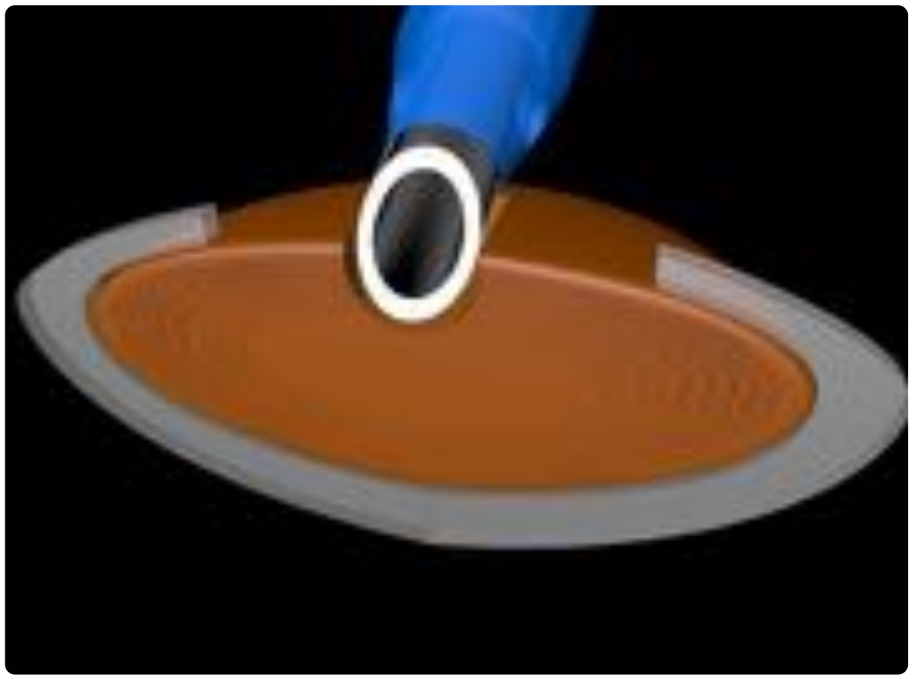

The initial groove is the width of the needle.

Movie 8.5 Narrow groove

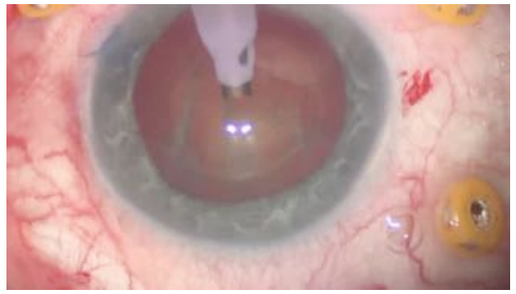

The groove is too narrow. When attempts are made to deepen it the infusion sleeve gets jammed in the top of the groove and the whole nucleus moves. Subsequent cracking was very difficult in this case because the groove was not deep enough.

Illustration 8.6 Trenches too wide

In this soft nucleus the trenches are too wide. This is likely to disintegrate into a bowl on attempted cracking (or even on attempted rotation).

Sculpting - depth of the trench

The trench must extend most of the way though the endonucleus to allow cracking. This is particularly important in soft nuclei. Failure to do this, particularly in the central zone where the cataract is thickest, is the probably the commonest error when learning phacoemulsification. It is exceptionally rare to pass the phacoemulsification probe through the posterior capsule. Conversely failure to make the groove deep enough is far more likely to lead to capsular and zonular problems because of the difficulty with subsequent lens disassembly.

The depth of the trench may be assessed by:

- The change in the red reflex, which get progressively brighter as the trench is deepened.
- Using the width of the phacoemulsification needle as a reference. The mean central thickness of cataractous human lenses is 4.63 mm. The width of phacoemulsification needles varies slightly. Most are approximately 1mm. This is a useful reference in eyes with no red reflex (for example dense vitreous hemorrhages).

Because of the concavity of the posterior lens surface the trench is made shallower peripherally. This is also judged by the red reflex.

Illustration 8.7 The depth of the trench

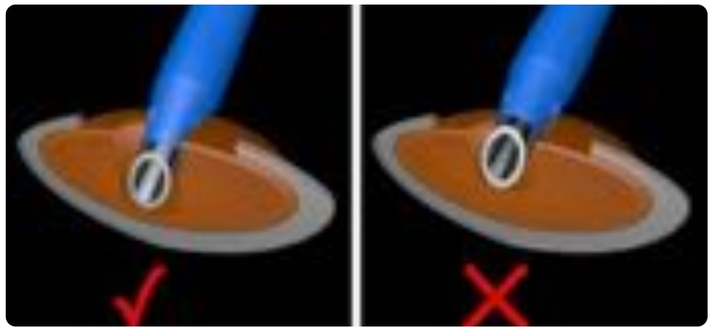

The trench should extend most of the way through the endonucleus. Failure to do this is probably the most common error when learning phacoemulsification surgery.

Illustration 8.8 Gauging the depth of the trench

As the trench gets to the correct depth a red reflex is seen.

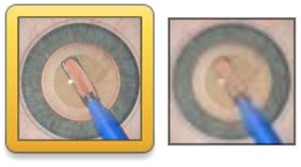

Sculpting - depth of the trench (ctd.)

The desirable trench depth is not uniform. Because of the concavity of the posterior lens surface the trench must be shallower peripherally. This depth of the trench along its' length is judged by the change in the red reflex.

Illustration 8.9 The subincisional trench

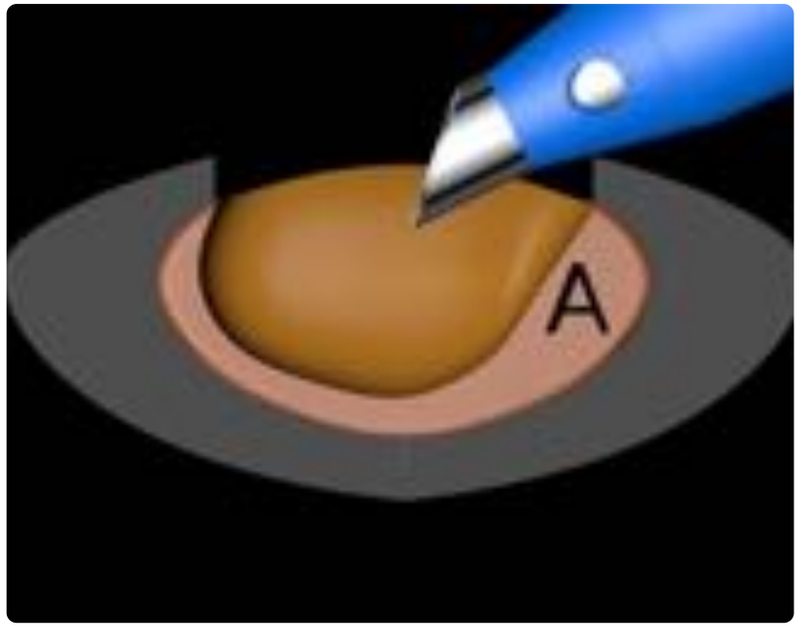

Owing to the angle of approach of the phacoemulsification probe the nucleus in zone A cannot be grooved.

Illustration 8.10 The longitudinal profile of the final trench

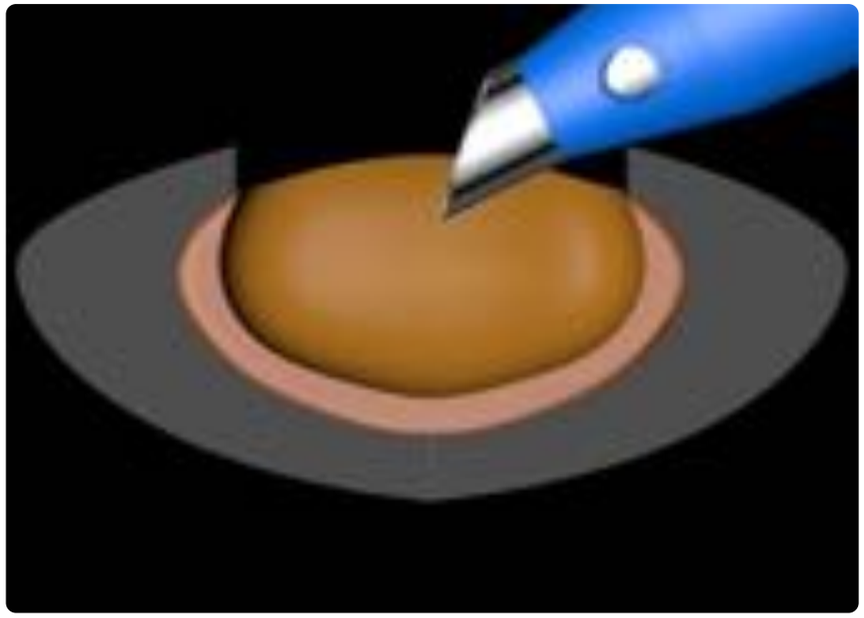

This lateral view of the trench reveals its' longitudinal profile. Because the nucleus is thinner peripherally the trench is shallower here.

Sculpting - profile of the trench

The width of the trench should be uniform (i.e. the walls of the trench should be vertical). If the walls slope cracking the nucleus becomes difficult. The instruments may push the nucleus down rather than splitting it in two.

Illustration 8.11 The trench walls

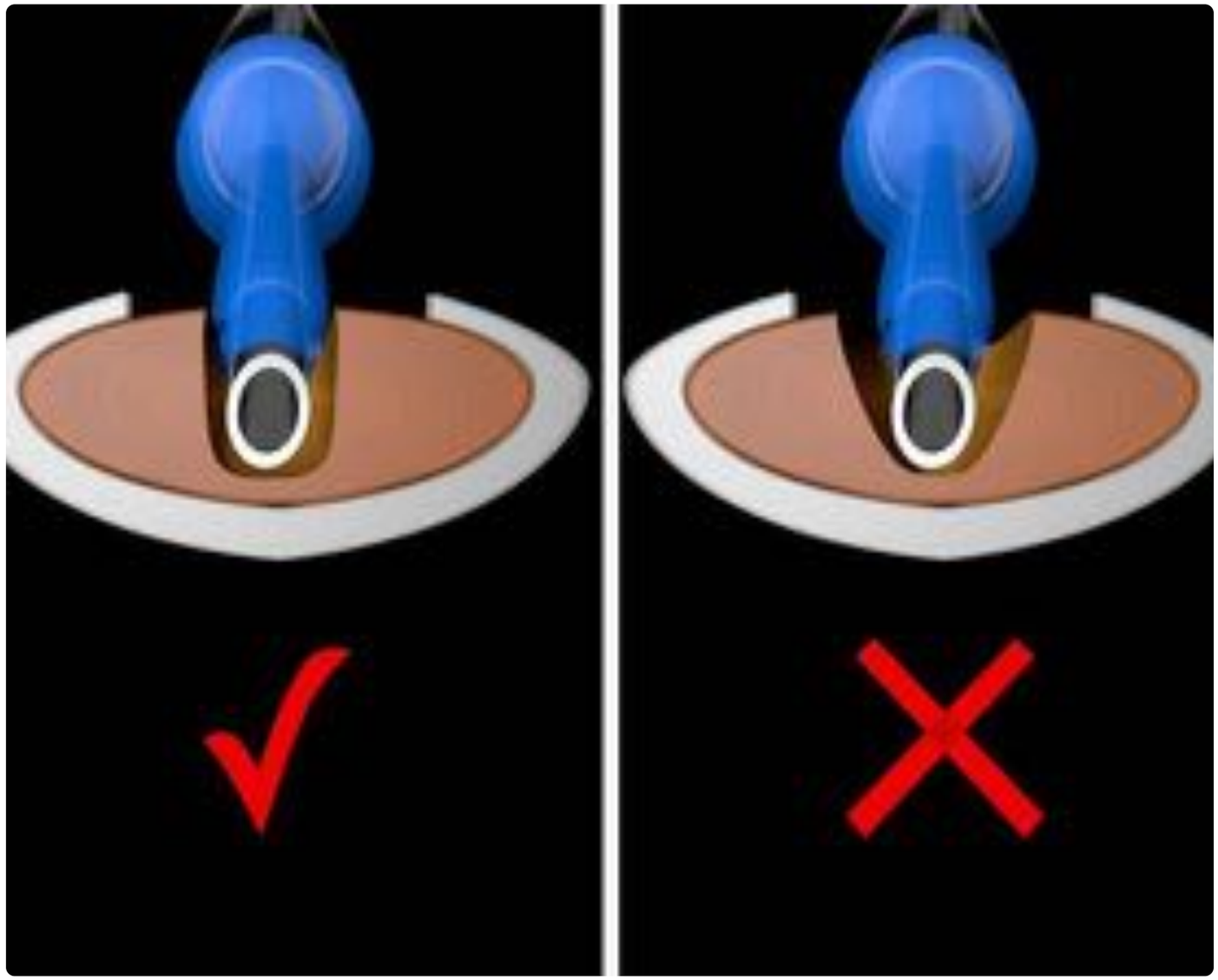

The trench walls should be vertical. Sloping walls make cracking difficult.

Rotating the nucleus

When the first trench has been completed the nucleus is rotated through 90^0 to make the second groove.

The nucleus is rotated by placing a second instrument in the base of the groove and applying a rotational force.

The rotational force (torque) is the product of the force applied and the distance of this force from the centre of movement.

The second instrument is therefore placed in the peripheral part of the groove.

The phaco probe can be used to assist rotation at the other end of the groove. This produces a very efficient dipole of torque that acts around the centre of rotation of the nucleus.

The second instrument is literally rotated between finger and thumb to produce the required angular rotation.

Illustration 8.12 Torque and instrument position

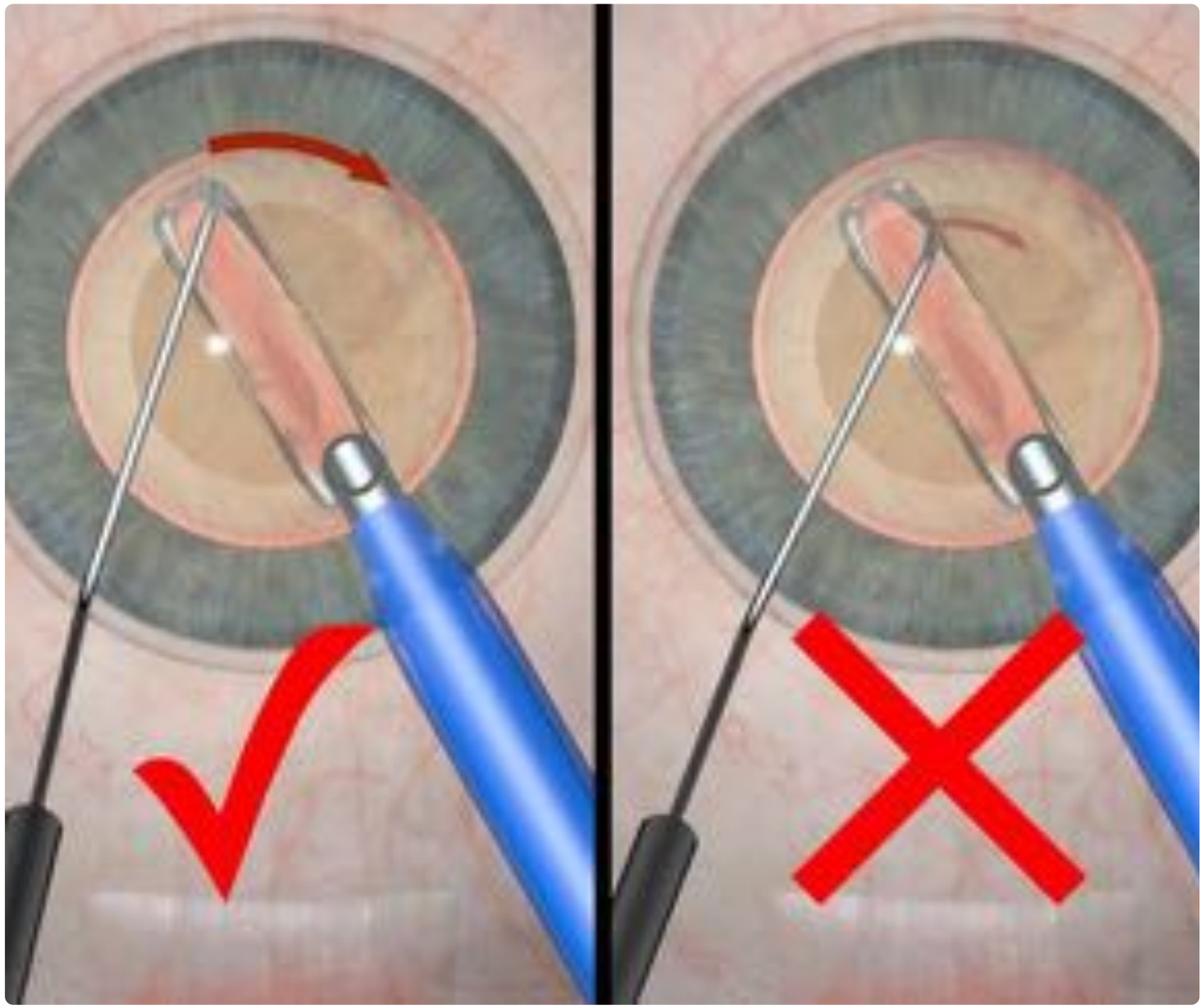

The torque (turning force) is much greater if the second instrument is placed in the peripheral part of the groove.

Completion of sculpting

The cruciate shape of the completed trench is created by repeated rotation and grooving of the nucleus.

Some surgeons rotate the nucleus through 180^0 and complete the trench in the original axis before making the tributary grooves. Provided all parts of the trench are deep enough the order in which the grooves are made is not critical.

Movie 8.6 Sculpting the nucleus

Note that the nucleus moves at several points. This was a vitrectomized eye and developed mild iris-lens retropulsion. The posterior displacement of the lens reduced the effective angle of the tip, so that although the tip had a 30^0 bevel it behaves as though the bevel was less and occlusion was prone to develop. The iris retropulsion can be overcome and the chamber shallowed by lifting the iris forward with the second instrument (Cionni manouevre)

Cracking

Figure 8.2 Cracking the nucleus

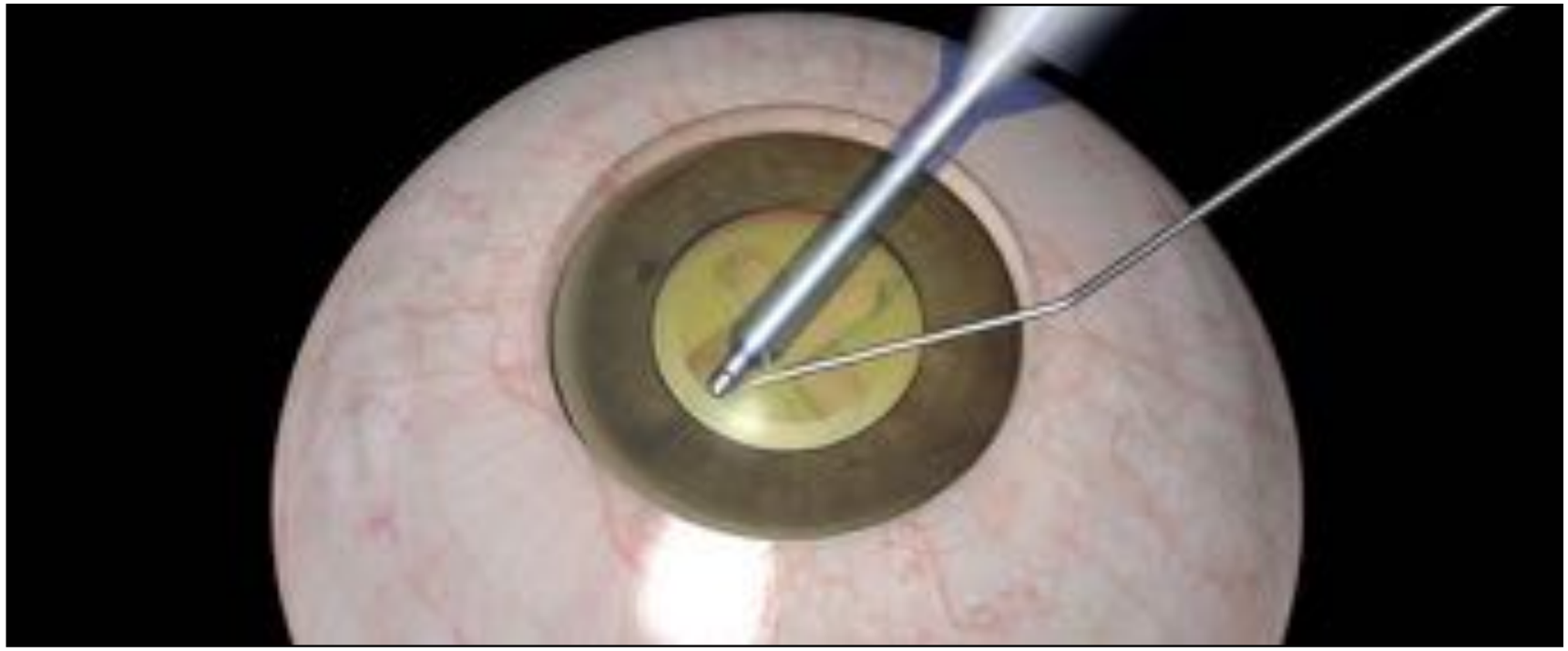

The nucleus is cracked with a spreading movement of two instruments resting in the bed of the trench. Usually the phacoemulsification probe and one other instrument, such as a chopper or mushroom, are used.

Although cracking is conventionally performed after the cruciate trench has been completed each groove may be cracked as it is completed.

Cracking principles

Prior to cracking it is helpful to rotate the nucleus so that the long axis of the trench to be cracked lies between the phacoemulsification probe and the second instrument.

Cracking is then usually easy to accomplish provided:

- The trench is deep enough
- The side walls of the trench are vertical.
- The instruments are placed deep in the groove.

Illustration 8.13 Orientation of the lens

The lens has been rotated so that the axis of the groove to be cracked (red and white line) lies between the two instruments.

Movie 8.7 Cracking - instruments deep in the trench

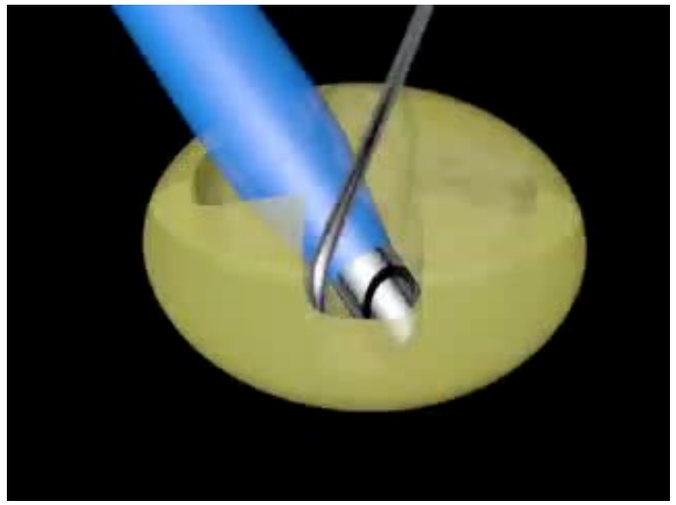

Because the instruments are deep in the trench all layers of the nucleus are cracked.

Movie 8.8 Cracking - instruments too superficial in the trench

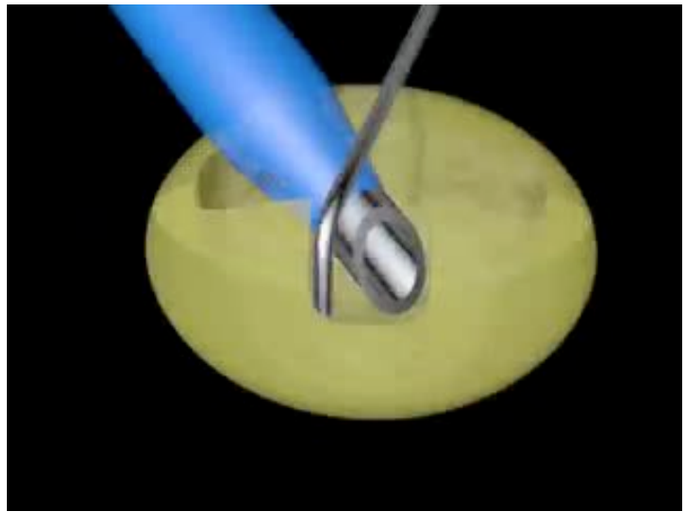

The instruments are not deep enough in the trench. Although the superficial layers of the nucleus have split the deeper layers remain intact.

Movie 8.9 Nuclear cracking

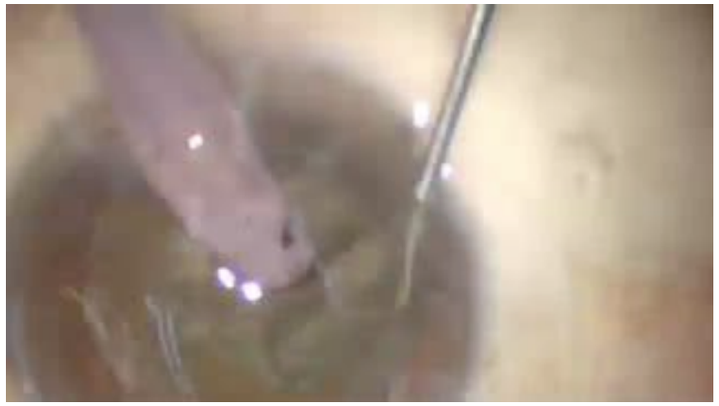

Sculpting has produced a cruciate trench. The phacoemulsification probe and a chopper are used to crack each quadrant in turn. The quadrants are left in situ until cracking has been completed as this makes rotation of the nucleus easier.

Movie 8.10 Cracking a soft nucleus

If the nucleus is soft the trench should be particularly deep. The posterior nuclear plate is somewhat elastic and splits gradually and locally so that the cracking may have to repeated at several points.

Quadrant removal

Figure 8.3 Quadrant removal

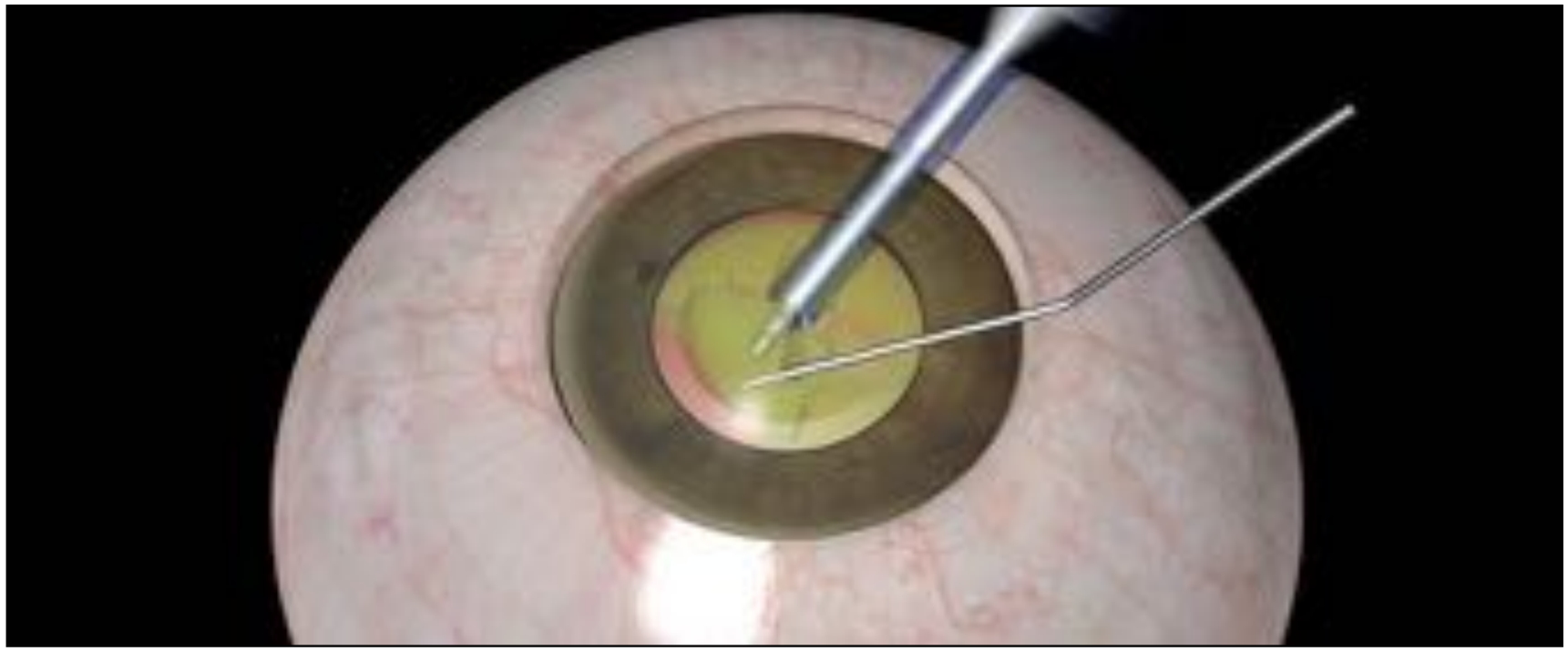

Once the quadrants are freely mobile they are engaged with the phacoemulsification probe.

The safe zone

During quadrant removal high vacuum is used. If mobile structures such as the iris or posterior capsule enter the aspiration port the results may be disastrous.

In order to avoid the iris and capsule a central 'safe zone' may be defined where, even in the presence of significant fluid currents in the anterior chamber, these delicate structures are unlikely to enter the tip of the phacoemulsification probe.

This safe zone is the area within the margins of the capsulorrhexis in the iris plane. Mobile lens fragments should be engaged and drawn into this area before high vacuum is used.

Illustration 8.14 The safe zone

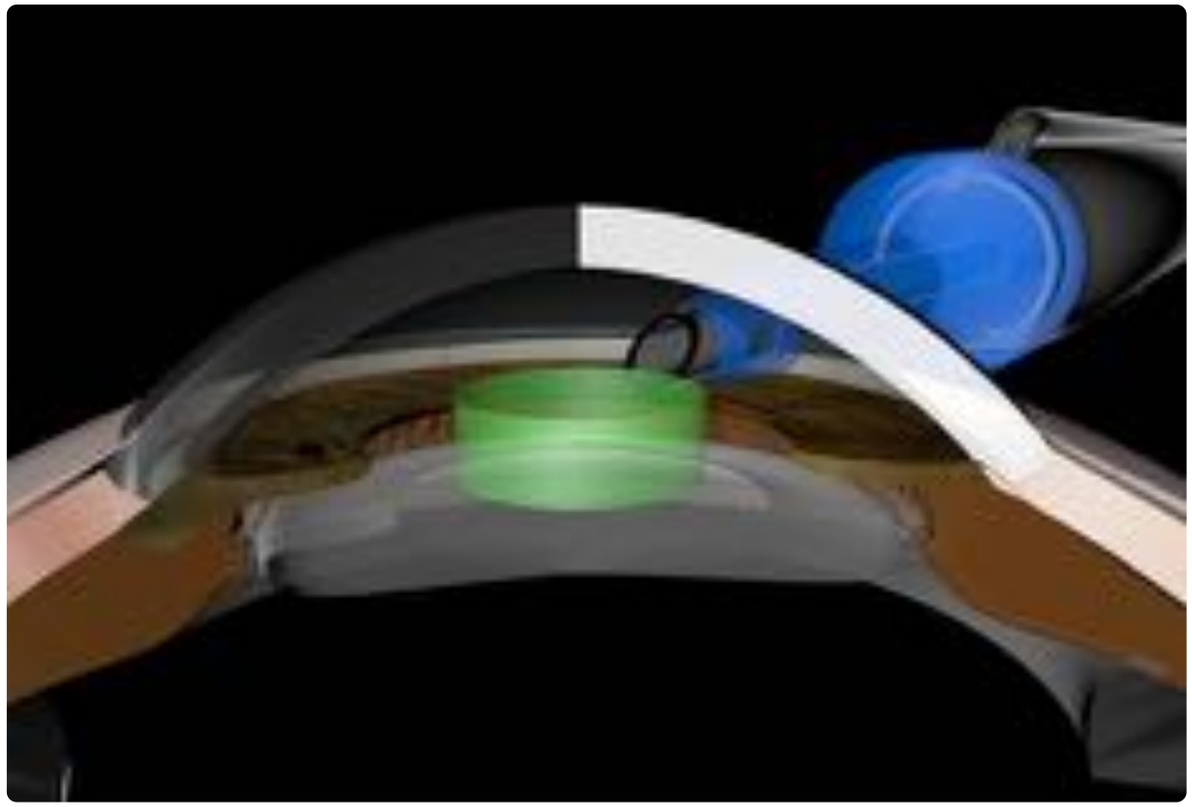

The safe zone is a construct defining the limits for safe emulsification. It corresponds to the capsulorhexis edge and the iris plane but these dimensions are not absolute. If the iris constricts the diameter of the safe zone reduces.

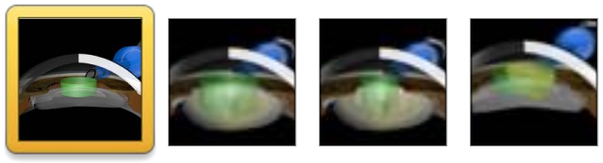

Quadrant engagement

The quadrants must be moved into the safe zone to be safely emulsified. In a hard nucleus the fragments interlock, limiting their freedom of movement. Significant traction is then required to move the first quadrant into the safe zone.

This traction requires occlusion of the phacoemulsification aspiration port and high vacuum.

Occlusion may be easier to achieve if the phacoemulsification probe is rotated 90^0. Alternatively a brief burst of phacoemulsification power is used to bury the tip of the needle in the fragment. Once this has been achieved no further phacoemulsification power is used - i.e. the foot pedal stays in position 2 as the fragment is pulled into the safe zone. When using a peristaltic system it is important to give the vacuum a few seconds to build up before pulling on the fragment.

Illustration 8.15 Interlocking

In this hard nucleus the quadrants are interlocked - there is resistance to removal of the first quadrant.

Illustration 8.16 Rotating the probe to achieve occlusion



Occlusion of the bevelled tip with the wall of the quadrant may be achieved by rotating the probe 90^0 about its' long axis. In this case a 45^0 bevel on the probe has been used to illustrate this more clearly.

Movie 8.11 Use of phacoemulsification power to occlude the aspiration port

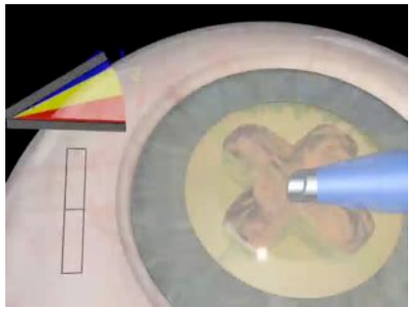

A short burst of phacoemulsification buries the tip of the probe in the nucleus to achieve occlusion. Note that the footswitch then stays in position 2 while the vacuum inside the tip builds up (this is a peristaltic system) and then while the quadrant is moved into the safe zone. Inadvertently moving into position 3 would break the occlusion and allow the quadrant to slip back - this is a very common error when learning.

A second instrument may be used to help break the interlock by tipping the quadrant.

Removal of the first quadrant breaks this interlock and the other quadrants may be moved much more easily.

Movie 8.12 Unlocking with the second instrument

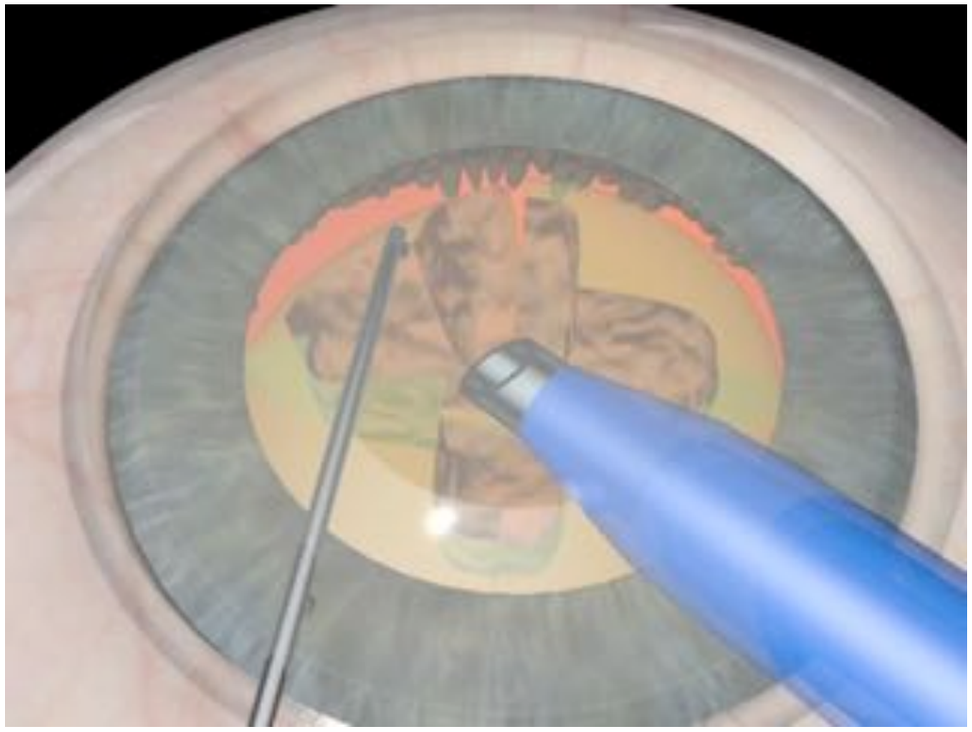

Pressure outward and slightly downward tips the inferior plate of the quadrant upwards, unlocking it.

Illustration 8.17 Interlocking (2)

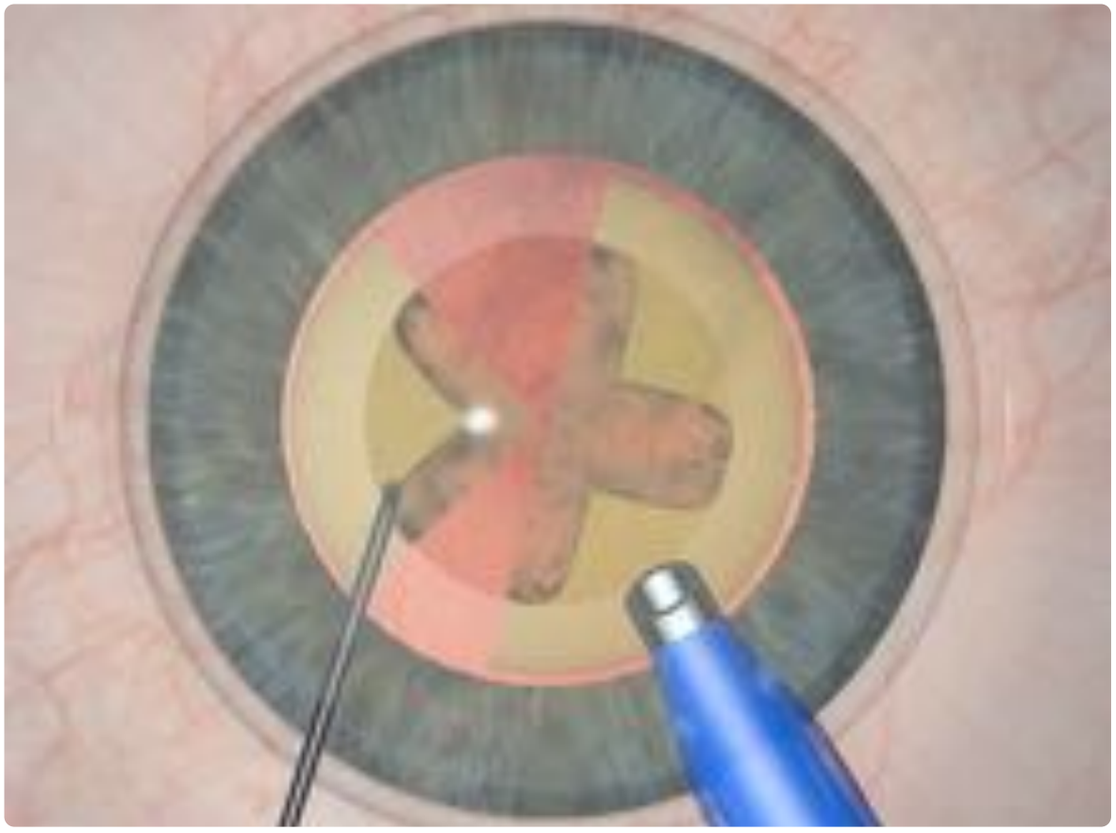

Following removal of the first quadrant the remaining 3 quadrants are more mobile.

Quadrant emulsification

Once it is in the safe zone each quadrant is emulsified in turn. The second instrument may be used to manipulate the quadrant, feeding it to the aspiration port and chopping it.

Traditional teaching about the use of a second instrument is that it is necessary to keep it in the eye at all times in order to protect the posterior capsule and stop it from coming forward towards the phaco tip. But for most of the time during removal of the free quadrants the sec-

Movie 8.13 Emulsification

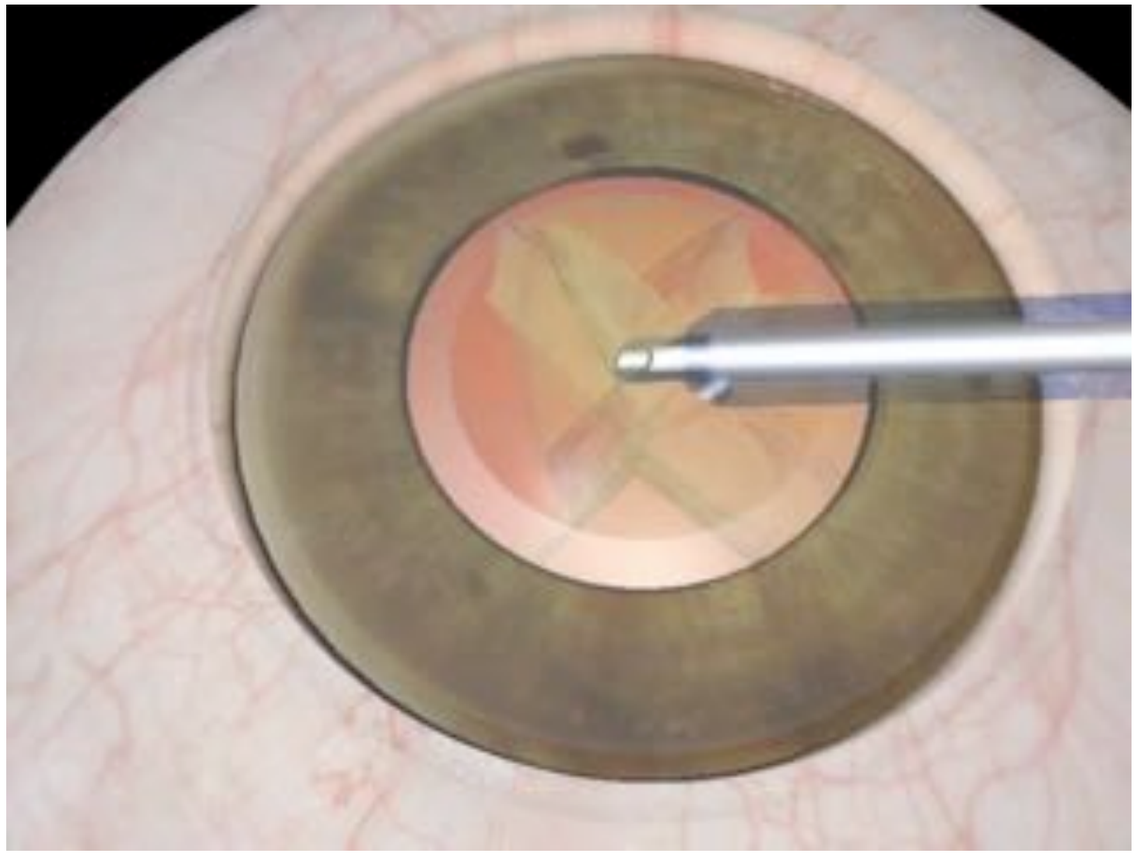

This requires high phaco power and sufficient vacuum and flow to counteract lens repulsion due to the jackhammer effect of the tip. The pedal is therefore moved into position 3. Emulsification is easier if some form of discontinuous (in this case pulsed) phacoemulsification is used. In the absence of some form of IOP compensating mechanism the infusion pressure is higher than while sculpting to prevent post occlusion surge.

Movie 8.14 Quadrant removal

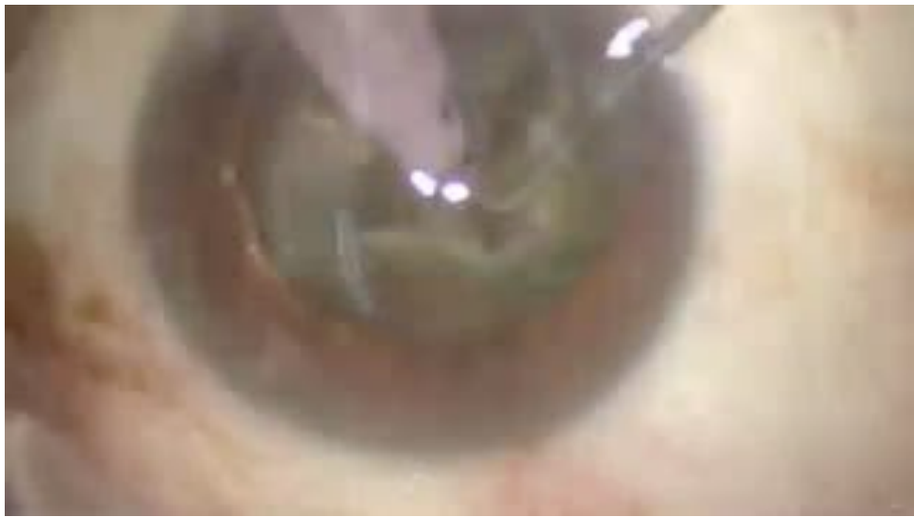

An unedited video of quadrant removal. Vacuum is used to draw quadrants into the safe zone before emulsification using pulsed phacoemulsification. Note how the second instrument facilitates by manipulating and chopping the quadrants. The second instrument is removed before emulsification of the final quadrant - this was a vitrectomized eye with a very mobile posterior capsule.

Movie 8.15 Difficult quadrant removal

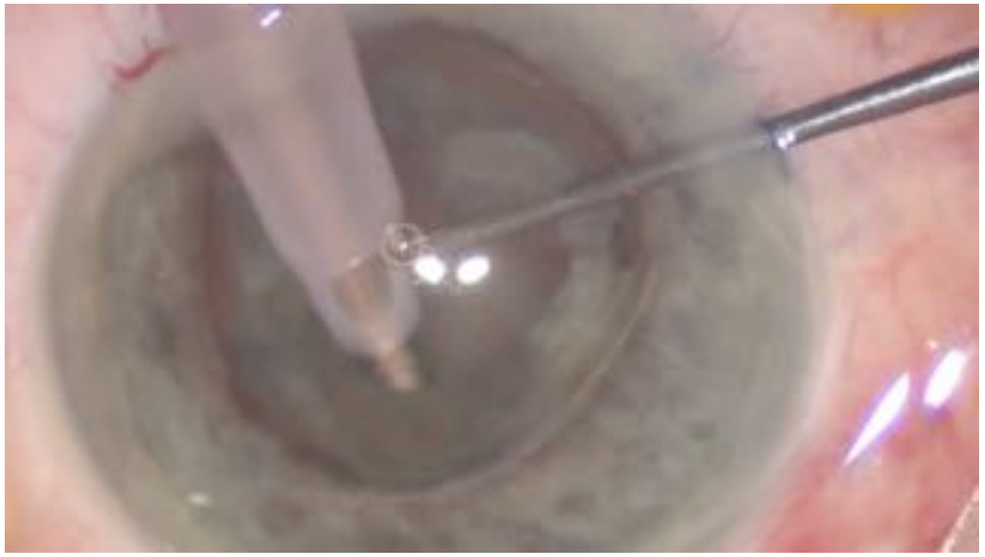

This video demonstrates the importance of fully cracking the nucleus, which had not been achieved here. Great difficulty is experienced with engagement of the quadrant. The posterior nuclear plate is intact so that the quadrants repeatedly spring back. The end result is a nuclear bowl.

Knowledge review

Movie 8.16 Movie review

Why is this surgeon experiencing difficulty cracking the nucleus?

Scroll down for the answer.

CHAPTER 9

Nuclear disassembly - chopping

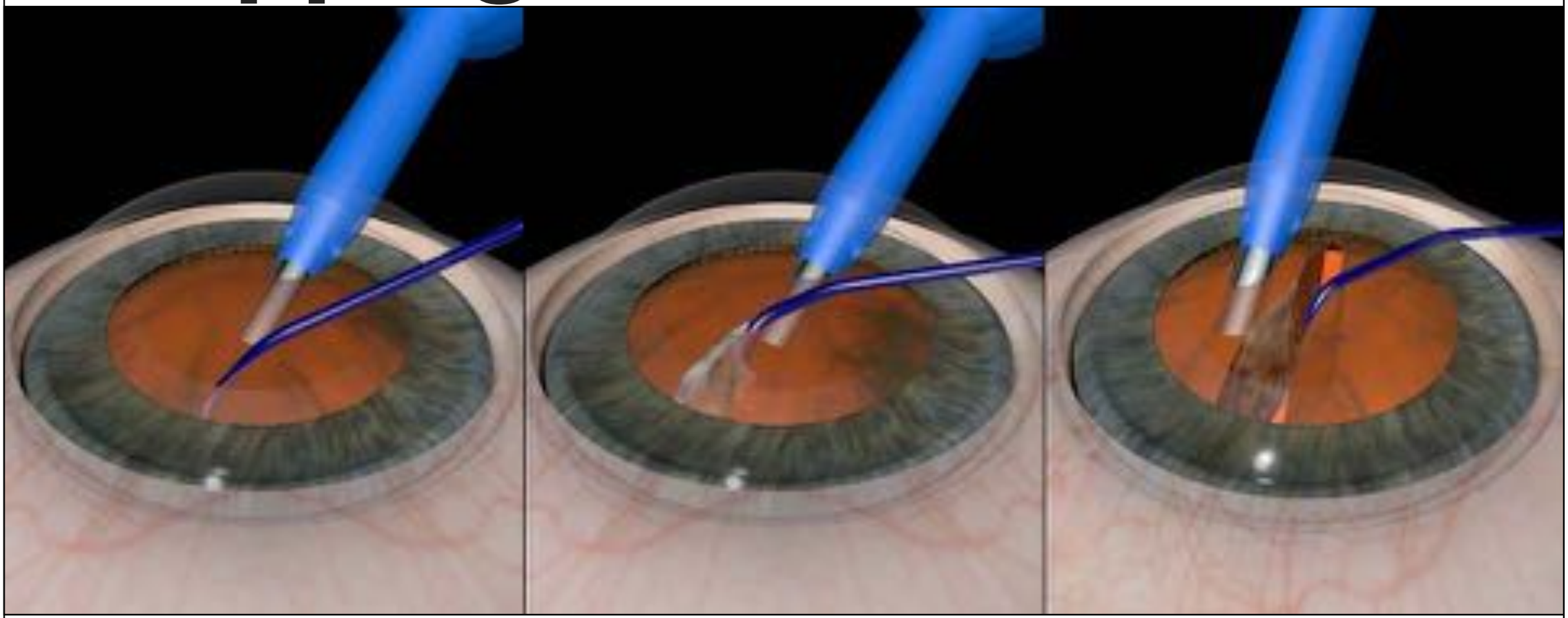

Chopping uses physical force rather than ultrasound energy to segment the nucleus.

Introduction to chopping

The advantages of chopping over divide and conquer are:

- Reduction in the amount of ultrasound energy delivered to the eye, as the nucleus is segmented by mechanical force from the instruments rather than ultrasound. This reduces endothelial cell loss and post operative blood-aqueous barrier breakdown.
- Reduction in stress on the zonules.
- Reduced reliance on the red reflex (for example in eyes with vitreous hemorrhage, where assessing the depth of sculpting may be difficult).

Movie 9.1 The zonules during divide and conquer (Miyake-Apple view from the posterior segment).

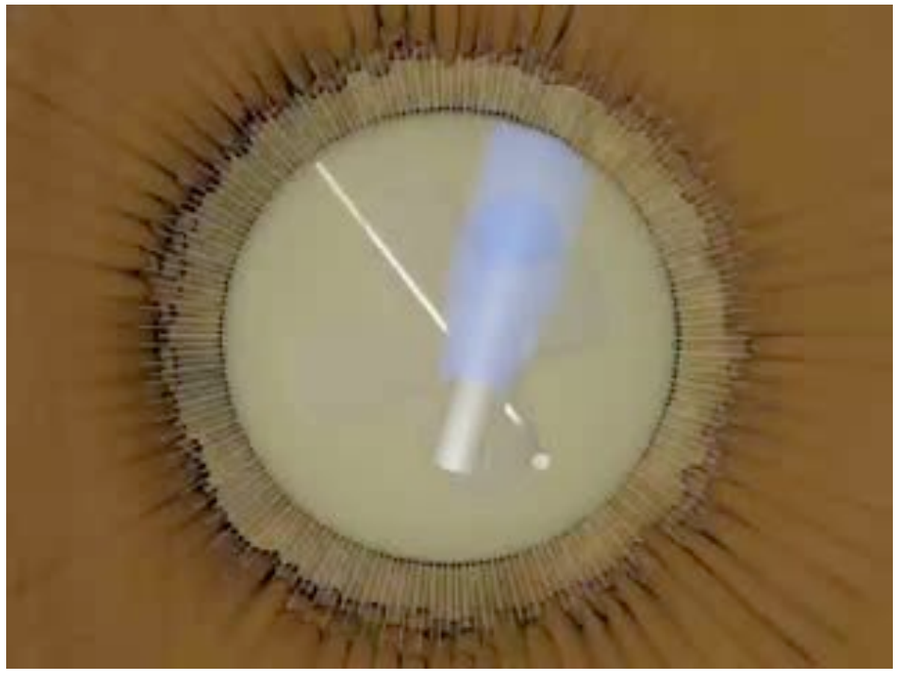

During divide and conquer the nucleus is stabilized during manipulation by the capsular bag. The Miyake-Apple technique, which allows phacoemulsification on cadaver eyes to be viewed from the posterior segment, has shown that sculpting and cracking cause zonular stress.

Principles of chopping

The radial orientation of lens fibers creates potential cleavage planes.

Under stress the lens fractures along these cleavage planes.

The process is analogous to chopping wood with an axe, where the initial fracture tends to propagate between the grains in the wood.

Illustration 9.1 The radial orientation of lens fibers

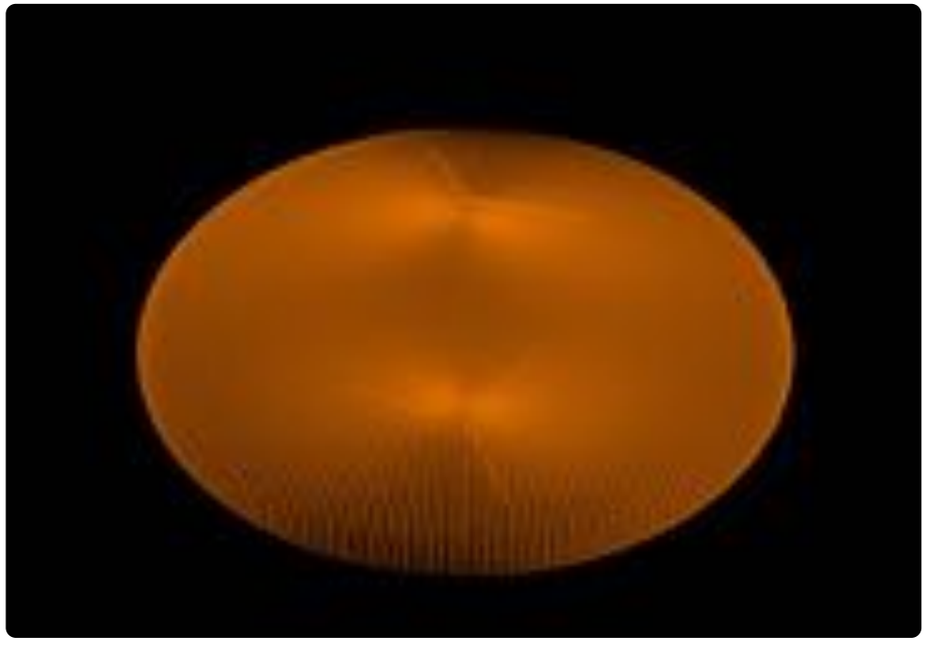

Cracking opens up radial cleavage planes between these fibers.

Movie 9.2 Cleavage planes while chopping wood

The grain creates fault lines which become cleavage planes under mechanical stress.

The chopper

There are many types of chopper.

All have a 45-50^0 bend about 10-15mm from the tip so that the end of the chopper can lie in the correct angle in the eye.

Vertical choppers tend to have sharp tips to allow them to penetrate the outer layers of the nucleus. Because of the sharp tip it is very important that this instrument is only used for the vertical chopping part of the surgery. It should be exchanged for a blunt ended instrument if any other form of nuclear manipulation or horizontal chopping is performed.

Horizontal choppers have a somewhat longer tip and a blunt end. The sharp edge is on the inside aspect

Illustration 9.2 A horizontal chopper.

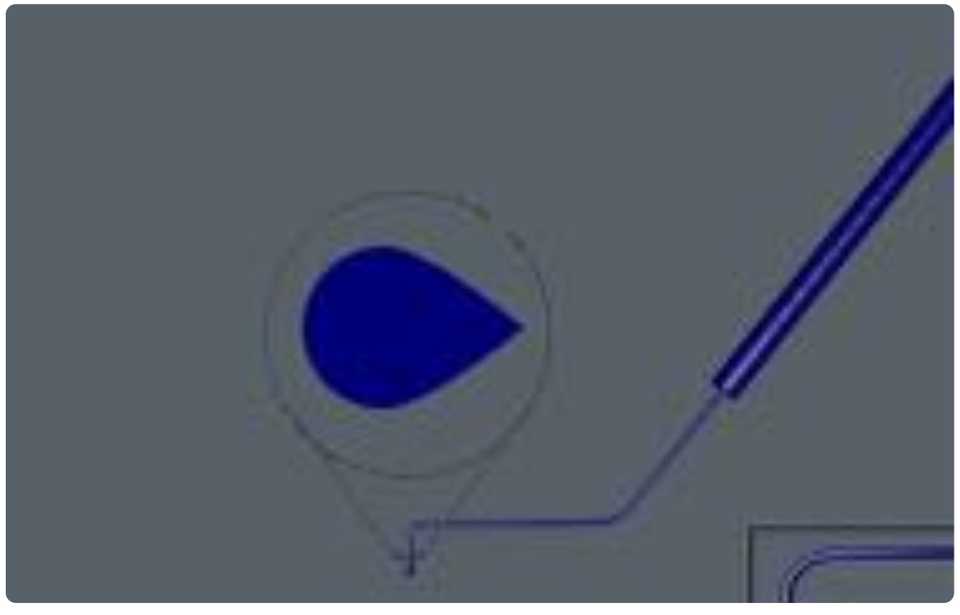

The bent tip is a little longer than the vertical chopper. Although the tip is blunt there is a cutting edge on the back side of the tip. Horizontal choppers with curved tips are also available (inset).

Illustration 9.3 A vertical chopper

The tip is a little shorter than the horizontal chopper and ends with a spike. Other types of tip such as a chisel (see inset) are also available.

Preparation for chopping

- The incision should be corneal rather than scleral. Scleral incisions do not allow the steep entry to the nucleus required in chopping.
- A long incision should be avoided as it makes it difficult to tilt the phacoemulsification probe vertical enough to tilt the nucleus.
- The capsulorhexis should not be too small (i.e. no less than 5mm), particularly for horizontal chopping.
- A complete hydrodissection with a freely mobile nucleus is essential.
- Many surgeons find hydrodelineation helpful.
- Aspiration of the epinuclear material within the capsulorhexis exposes the endonucleus.
- The phacoemulsification probe must be impaled into the nucleus. Depending on the tip design the infusion sleeve may be moved a little way up the needle to achieve this.*
- For a horizontal chop the pupil should be reasonably well dilated. This is not so important for a vertical chop as the instruments stay fairly central throughout.

Illustration 9.4 Retraction of the sleeve



Impaling the nucleus is easier if the sleeve is slightly withdrawn.

*for certain probes this is unnecessary and counterproductive - if in doubt check with the manufacturer.

Horizontal chopping

Figure 9.1 The primary horizontal chop

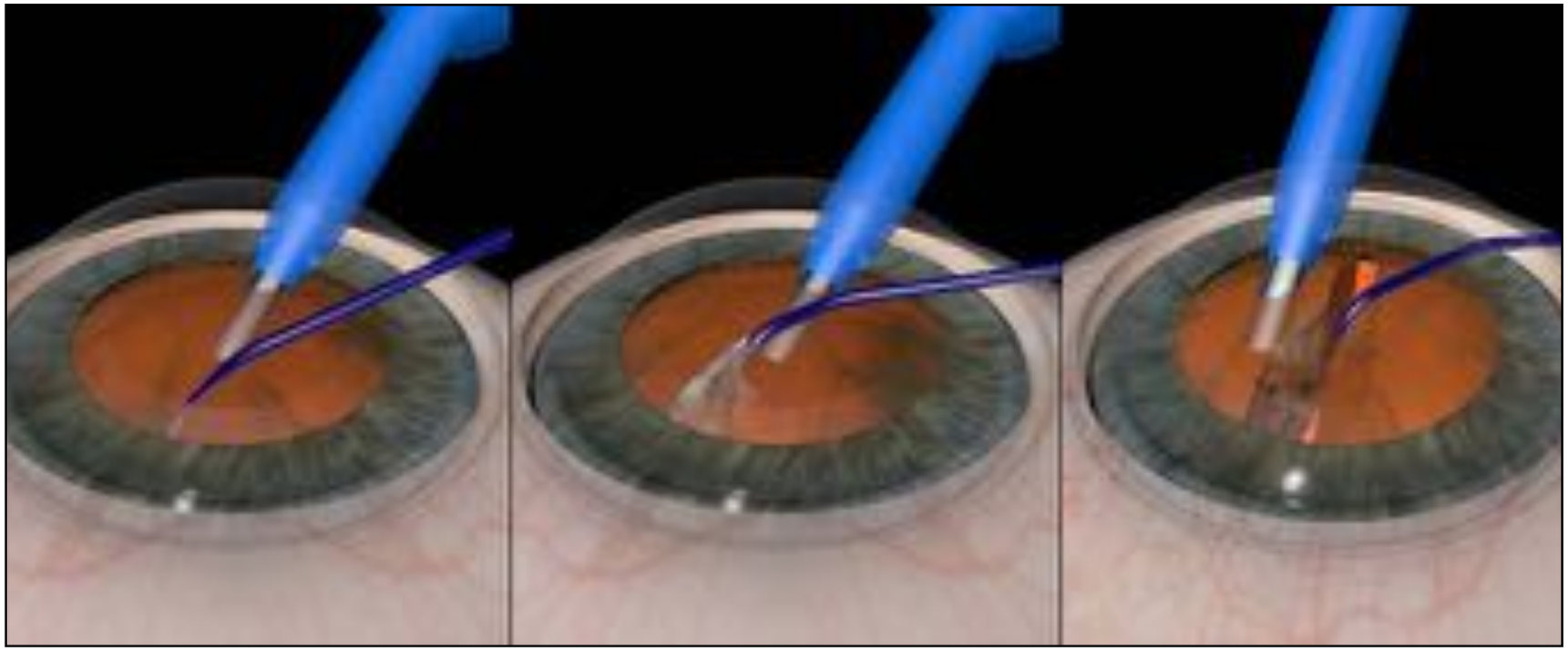

Kunihiro Nagahara demonstrated that the nucleus could be disassembled without sculpting using a phacoemulsification probe and a second instrument. The technique he described used movements of the instruments in the horizontal plane to create forces which fracture the nucleus.

Indications for horizontal chopping

This technique is particularly useful in hard cataracts and eyes with weak zonules.

Very soft nuclei may be hard to chop because the instruments glide through the lens without resistance so the compressive forces that lead to nuclear fracture do not build up.

It requires:

- A well dilated pupil.
- An adequate capsulorhexis.
- A freely rotatable nucleus (i.e. adequate hydrodissection).
- An incision that is not too long.

Illustration 9.5 Effect of a long incision

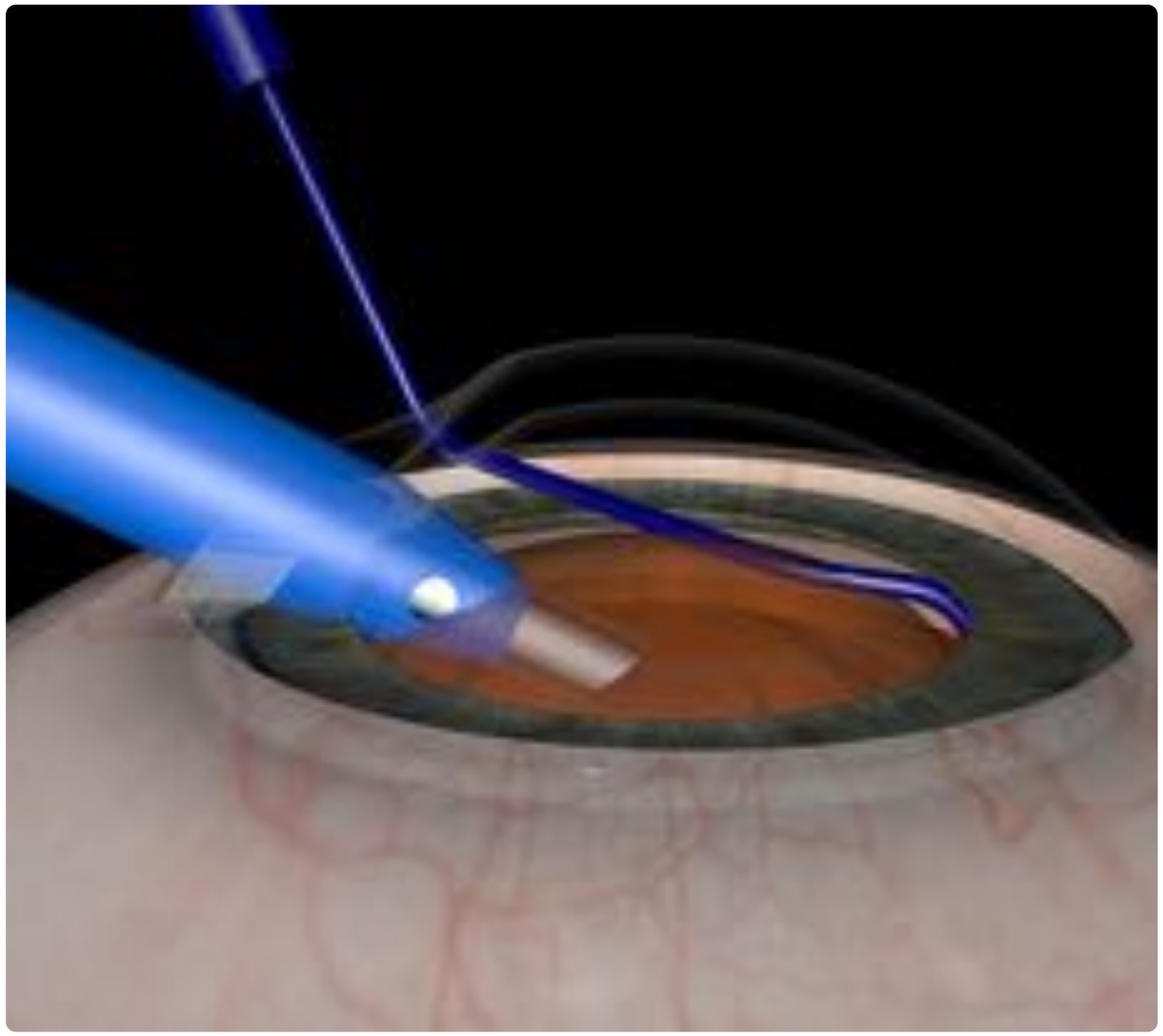

Tilting the phacoemulsification distorts the cornea. The resulting stress lines impair the view. Consequently the chopper has been placed incorrectly above the anterior capsule.

The steps in horizontal chopping (1) - clearing the epinucleus

The epinuclear material within the capsulorhexis is aspirated using the phacoemulsification probe.

Illustration 9.6 Aspiration of epinuclear material

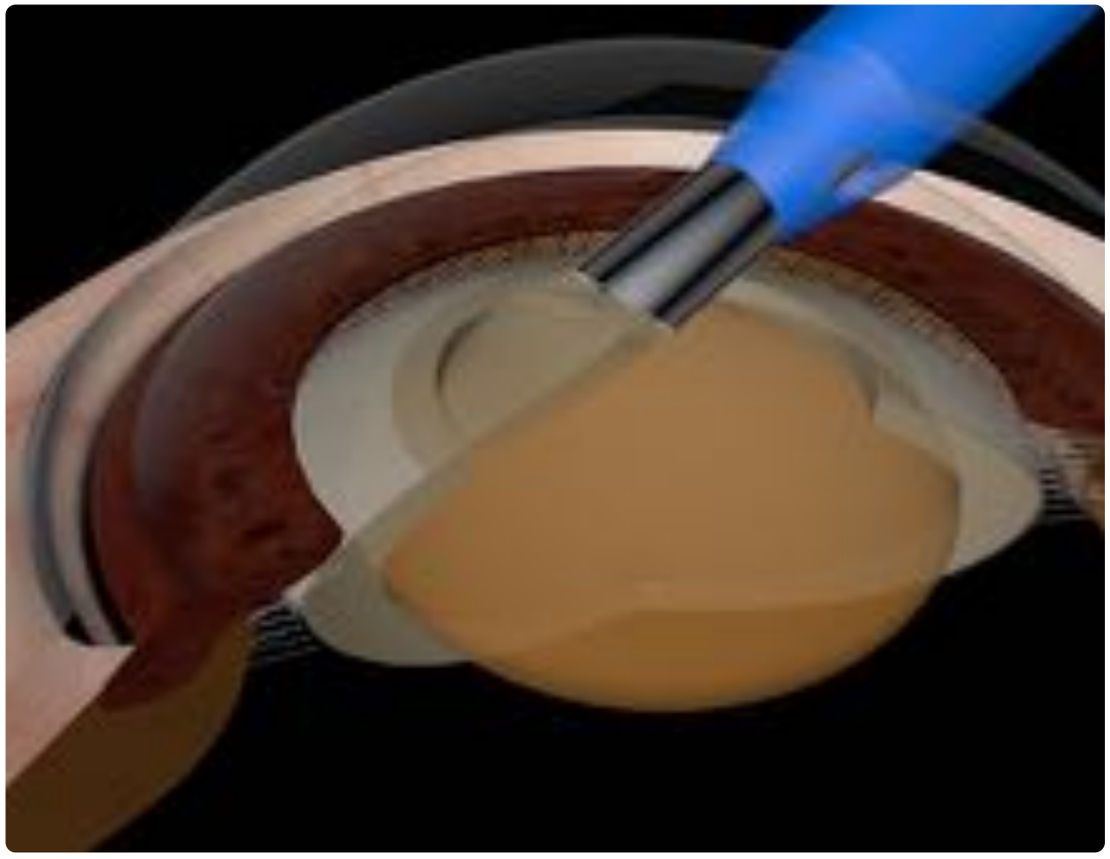

This is performed with the phacoemulsification mode in foot position 2. In this case the probe is 'bevel down' to achieve better occlusion.

The steps in horizontal chopping (2) - Insertion of the chopper

The chopper is moved to hook the equator of the lens.

To ensure that it lies under the capsule:

- Downward pressure is exerted as the chopper is moved peripherally so that the tip remains in contact with the surface of the endonucleus.
- Some surgeons prefer to rotate the chopper so that it passes flat under the edge of the capsulorhexis.
- If the chopper is correctly placed rotatory movements of the tip of the chopper (about the optical axis) will rotate the nucleus but should not affect the lens capsule or the capsulorrhexis.

Movie 9.3 Placement of the chopper

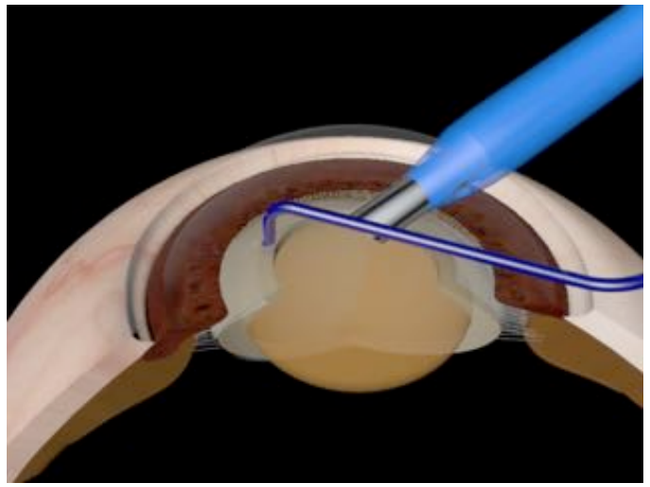

Note that the tip of the chopper remains in contact with the endonucleus as it moves peripherally, ensuring that it passes under the anterior capsular rim. The capsulorrhexis is stretched as the chopper moves under it, although this does not normally cause any problems.

Movie 9.4 Rotation of the chopper

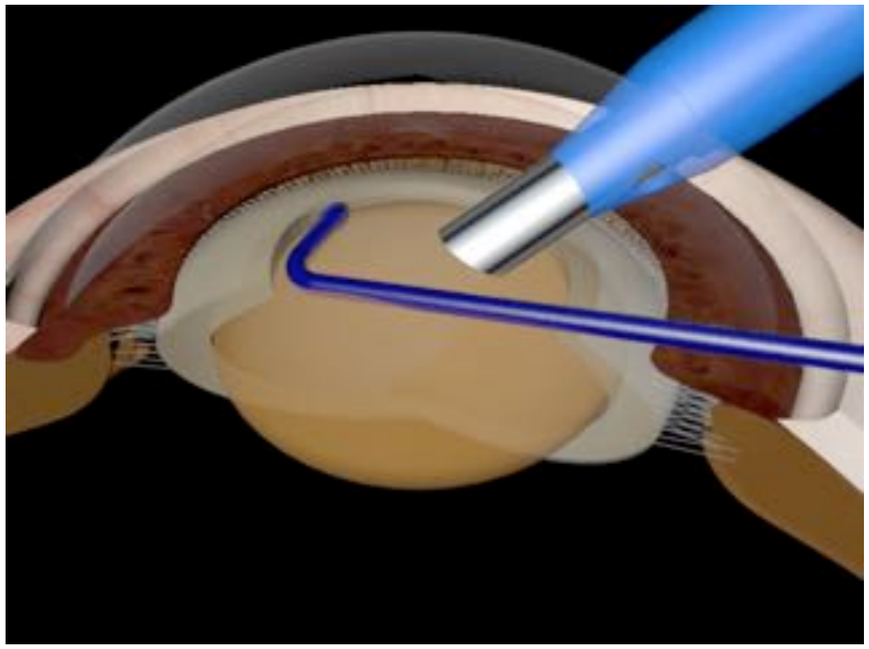

In this case the chopper is rotated before being slid under the capsule to minimize stress on the capsulorrhexis.

The steps in horizontal chopping (3) - Impaling the nucleus

The phacoemulsification probe is advanced into the centre of the nucleus.

This requires:

- The retraction of the infusion sleeve to 2 - 2.5 mm (or creation of a shallow pre-groove) so that the tip can reach the centre of the nucleus *
- A steep angle of entry.
- Entry to the endonucleus about 1 mm proximal to the centre of the nucleus.
- The probe orientation may be 'bevel up' or 'bevel down'. The latter is the authors' choice and is shown here is it achieves instant occlusion but this many surgeons perform chopping bevel up.

As there is phacoemulsification with occlusion there is no fluid flowing through the tip. Without fluid flow the tip may overheat so that some 'lens milk' (denatured lens protein) appears. This is transient and does not go on for long enough to cause a wound burn.

Illustration 9.7 The location and angle of entry of the phacoemulsification probe

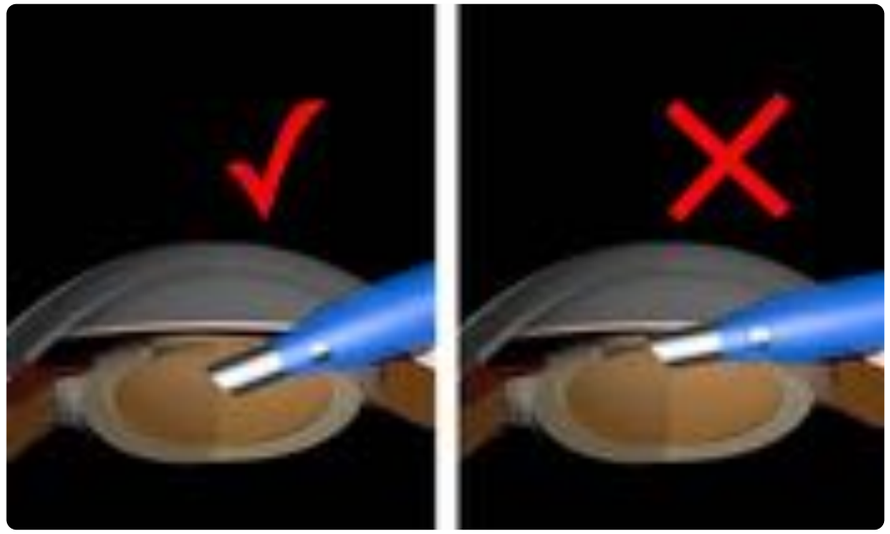

The angle of entry into the nucleus must be steep. In this case the phacoemulsification probe is orientated bevel down - this is a personal preference of the authors and is not mandatory.

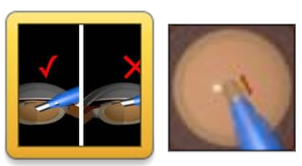

A common mistake when starting chopping is to fail to advance the tip of the probe deep enough into the nucleus. The fear of creating a hole in the posterior capsule is understandable but given the thickness of cataractous lenses it is not possible for a 2 mm tip to reach the posterior capsule.

*for certain probes this is unnecessary and counterproductive - if in doubt check with the manufacturer.

Illustration 9.8 The path of the chopper

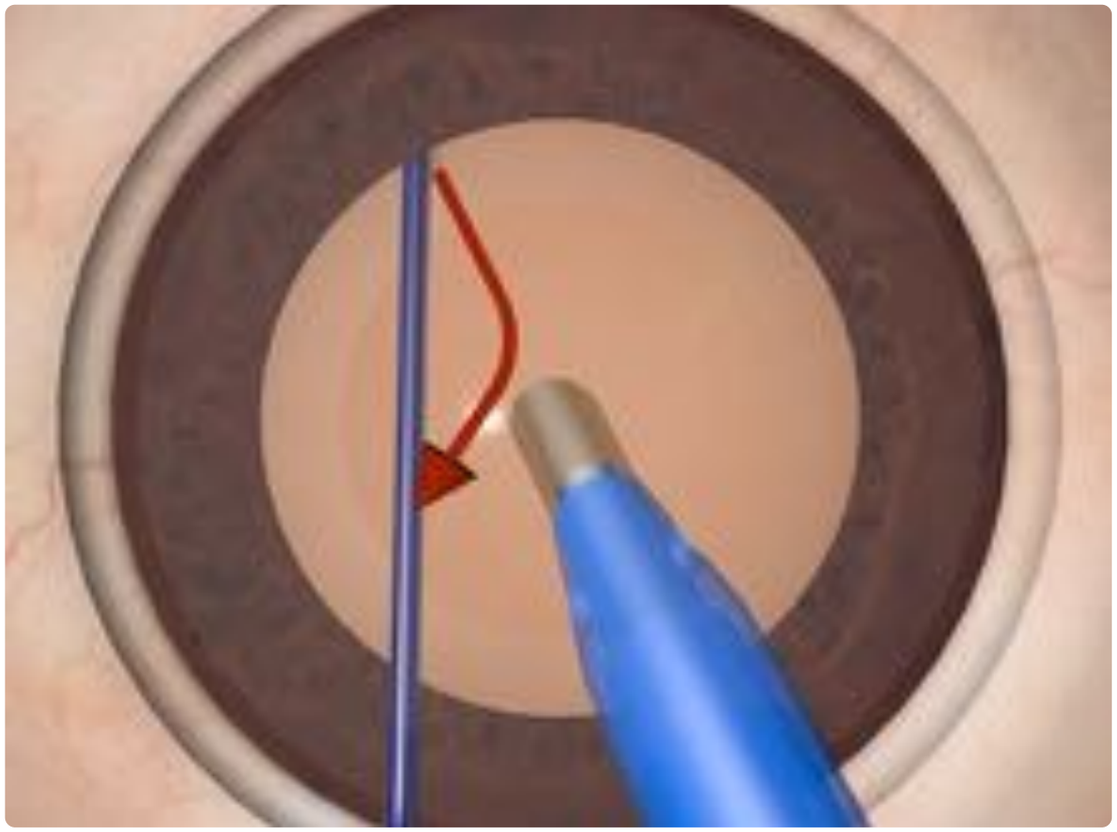

The chopper is initially moved in a line directly towards the probe tip. The depth of the chopper in the nucleus must be maintained as it is moved. The phacoemulsification probe stays completely still.

Movie 9.5 The primary chop

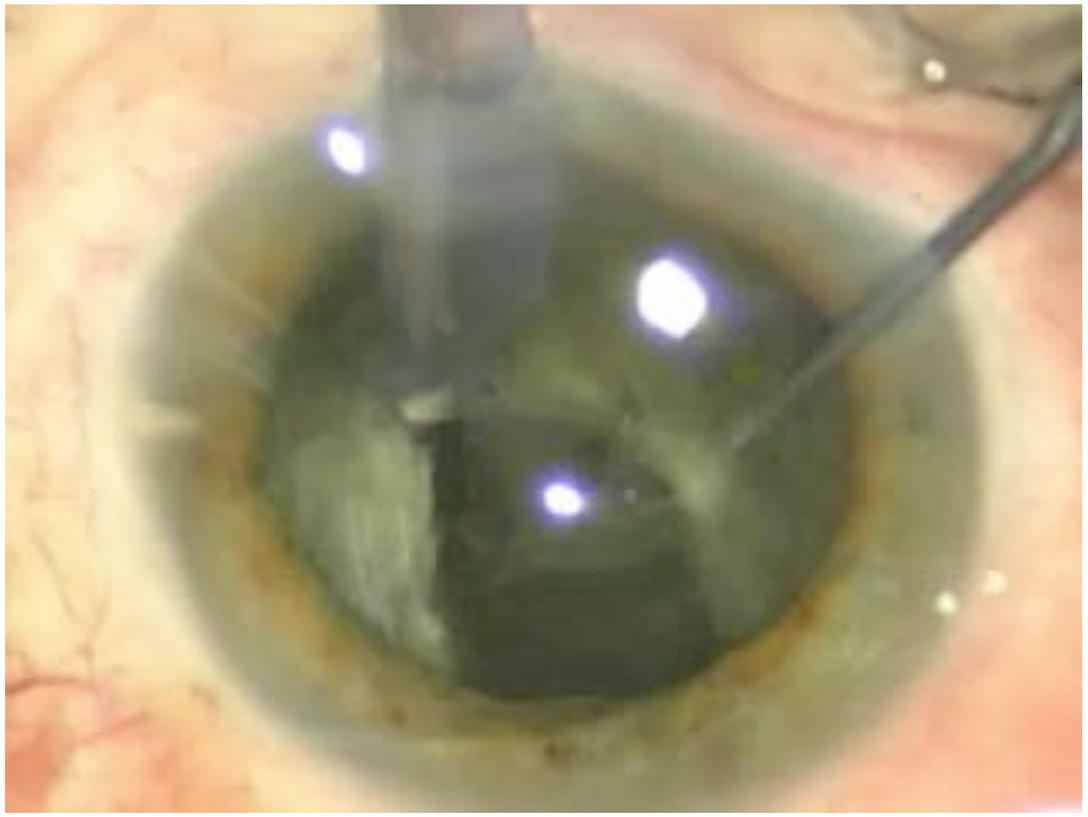

The steps in horizontal chopping (4) - secondary chops

Once the primary chop has been completed a series of secondary chops segment the heminuclei. The centre of the nucleus is now easily accessible in the face of the divided segment. The phacoemulsification probe is used bevel up to achieve occlusion on this vertical face. Vacuum holds the phacoemulsification probe in place while the chopper is used in the same way as during the primary chop. If the nucleus is soft the heminucleus may be divided and each quadrant removed. If the nucleus is hard the segments tend to interlock and 6-8 smaller segments are created.

This may be easier if vacuum and emulsification can be controlled independently using the yaw function on the foot pedal.

Illustration 9.9 Secondary chop

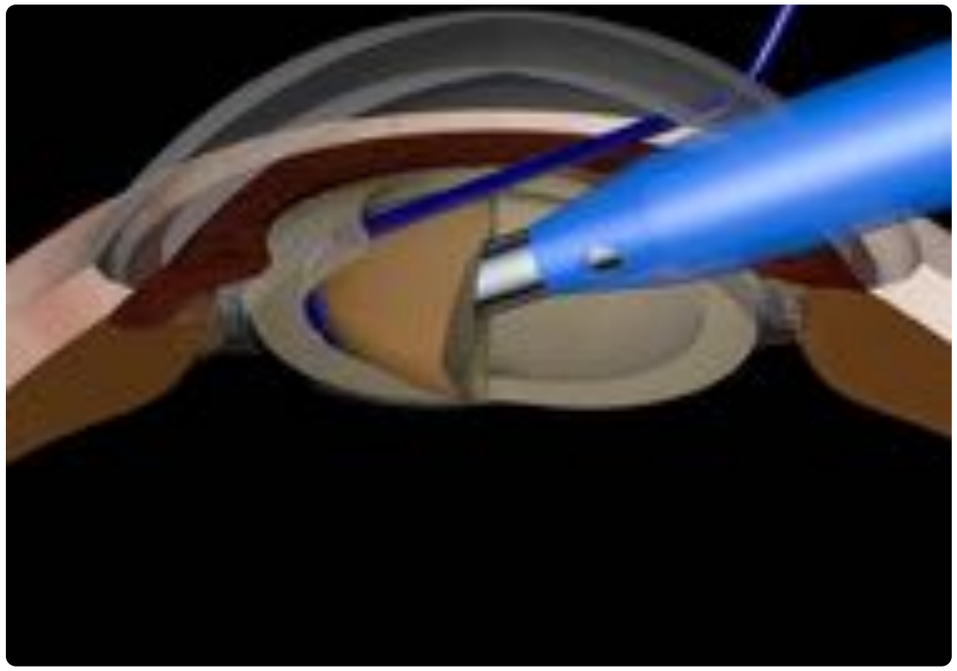

The phacoemulsification probe has access to the central nucleus on the wall of the heminucleus. As this wall is vertical the probe is now used bevel up to achieve occlusion.

Movie 9.6 A secondary chop

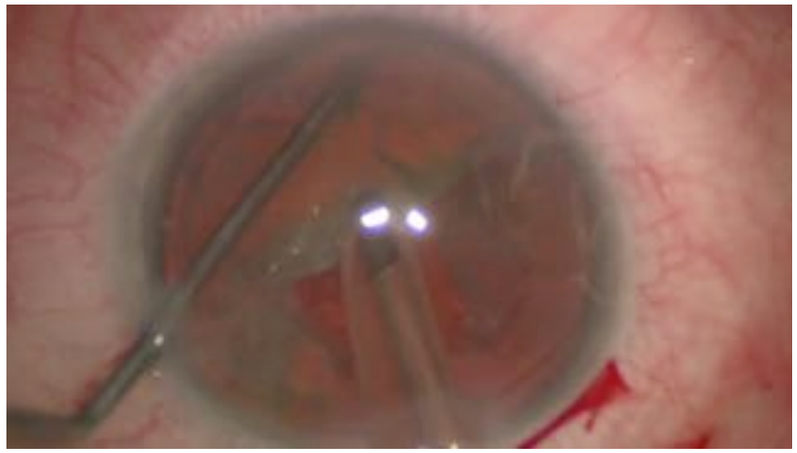

The phacoemulsification probe is impaled in the vertical wall at the edge of the heminucleus.

Vertical chopping

Figure 9.2 Vertical chopping

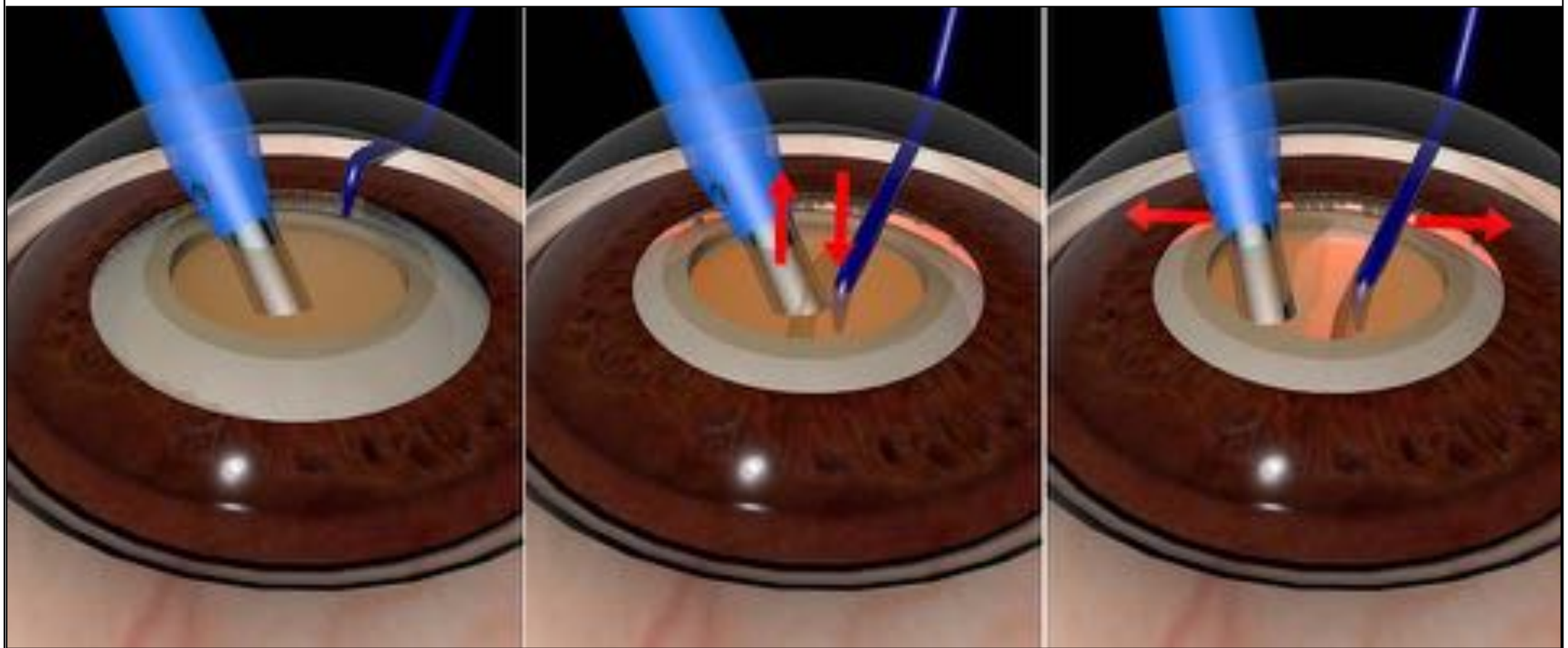

The forces that create initial fracture are vertical rather than horizontal. A useful technique in small pupils as in this case.

Vladimir Pfeiffer and Hidaharu Fukasaku developed this technique in which vertical rather than horizontal forces are used to fracture the endonucleus. It is particularly useful in eyes with moderately hard nuclei and limited pupil dilation.

The steps in vertical chopping

The first steps, including clearing the epinucleus and impaling the nucleus, are the same as when performing horizontal chopping. The vertical chopper differs from the horizontal chopper in possessing a shorter and sharper tip.

The vertical chopper is placed on the endonucleus slightly lateral to the tip of the phacoemulsification probe. It is pressed down so that it penetrates the endonucleus while the phacoemulsification probe is slightly lifted away from the surgeon. High vacuum is required to prevent the nucleus slipping off the tip of the phacoemulsification probe. When the lens starts to fracture the instruments are moved apart. The phacoemulsification probe then engages each heminucleus in turn as they are segmented with opposing vertical movements of the two instruments.

Use of very high vacuum without ultrasound is required to maintain the grip of the phacoemulsification probe on the nucleus when performing vertical chopping.

Illustration 9.10 Vertical chopping

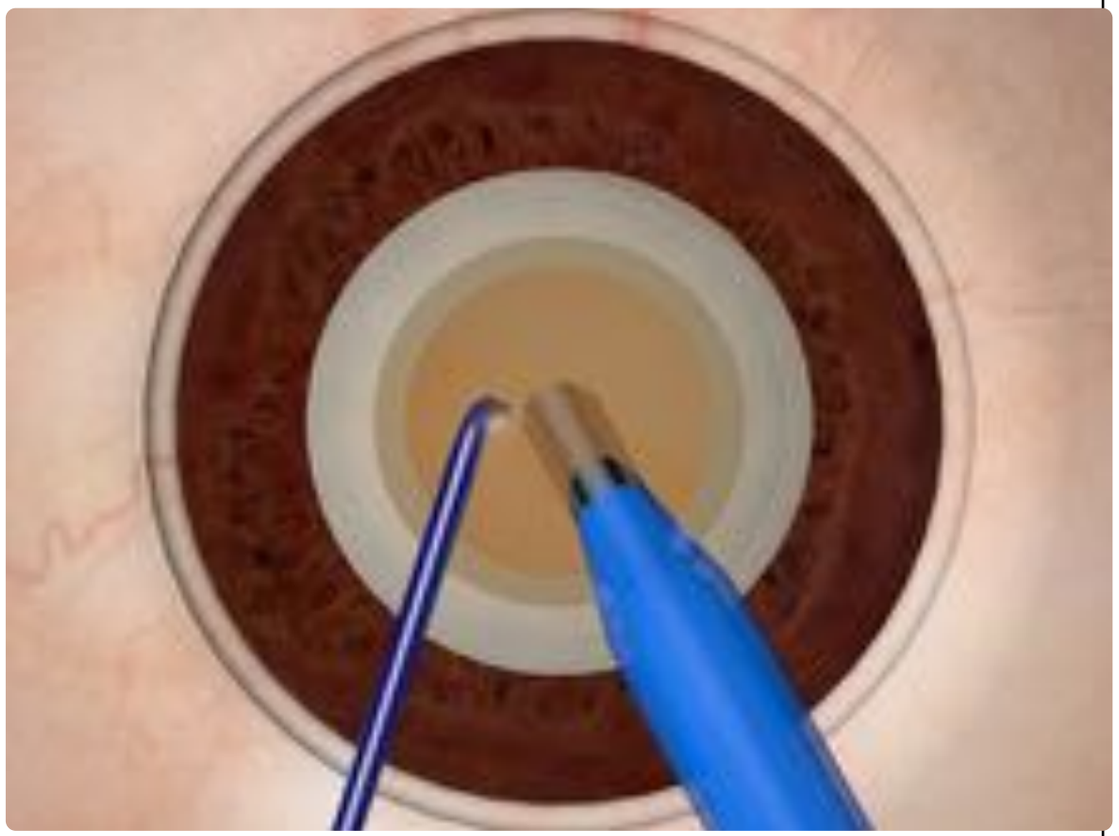

The vertical chopper is placed on the endonucleus slightly lateral to the tip of the phacoemulsification probe.

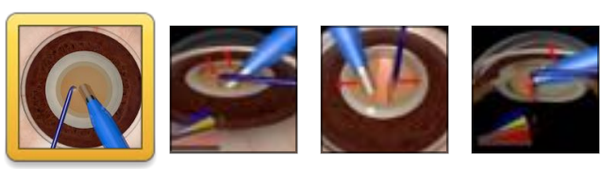

Movie 9.7 A secondary vertical chop

Stop and chop

Figure 9.3 Stop and chop

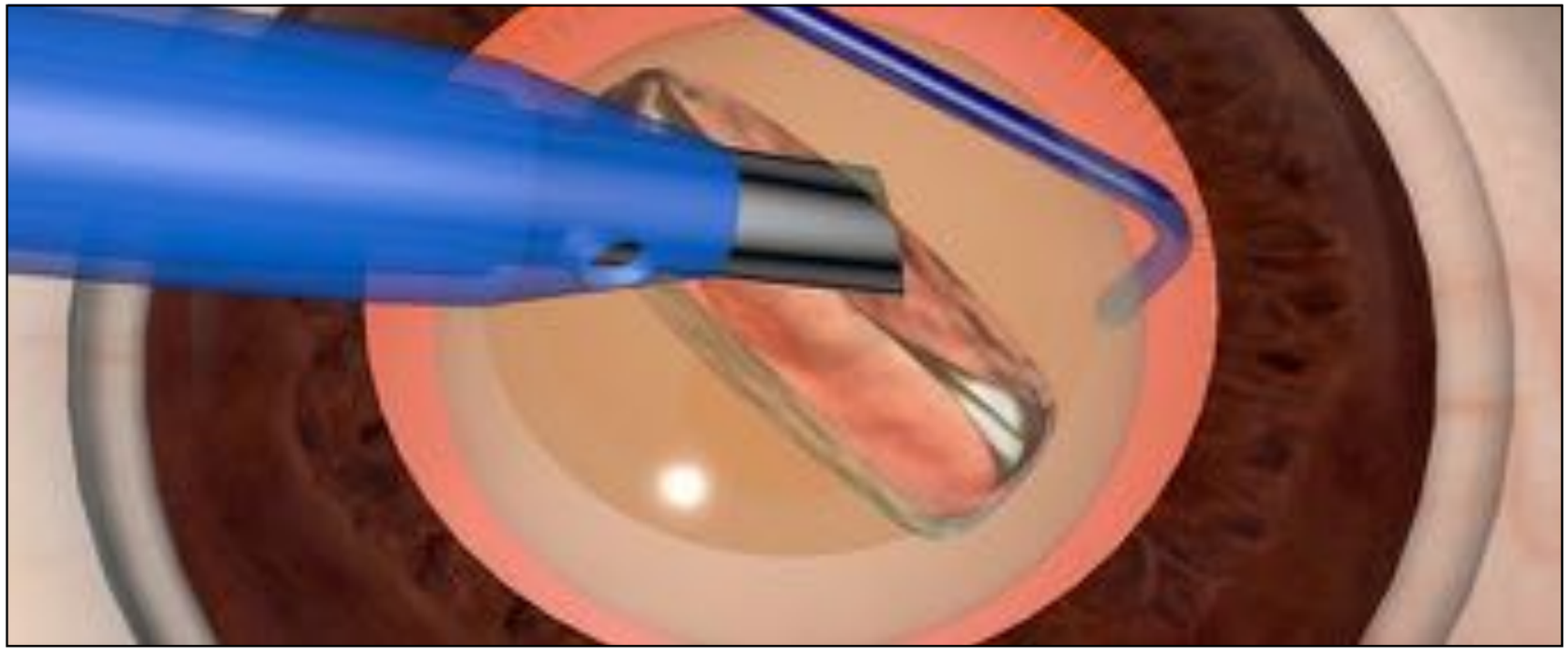

Paul Koch described this technique which combines elements of the divide and conquer approach with chopping.

Stop and chop

A single deep trench is made and the nucleus cracked in two. Chopping is then used to segment the hemi-nuclei. The groove provides space which makes is easier to engage and remove the nuclear fragments.

Illustration 9.11 The steps in stop and chop

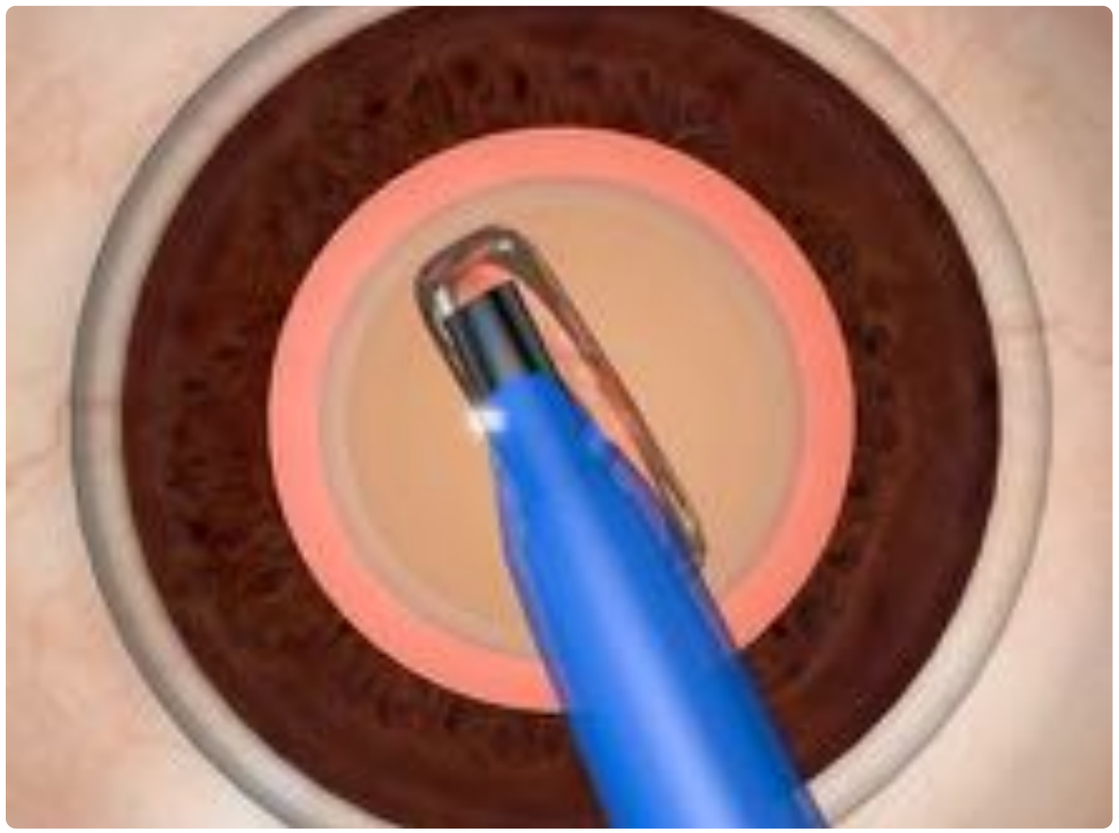

Following capsulorrhexis, hydrodissection and hydrodelineation a deep central trench is sculpted.

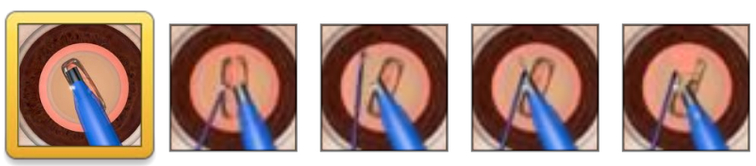

Movie 9.8 Stop and chop

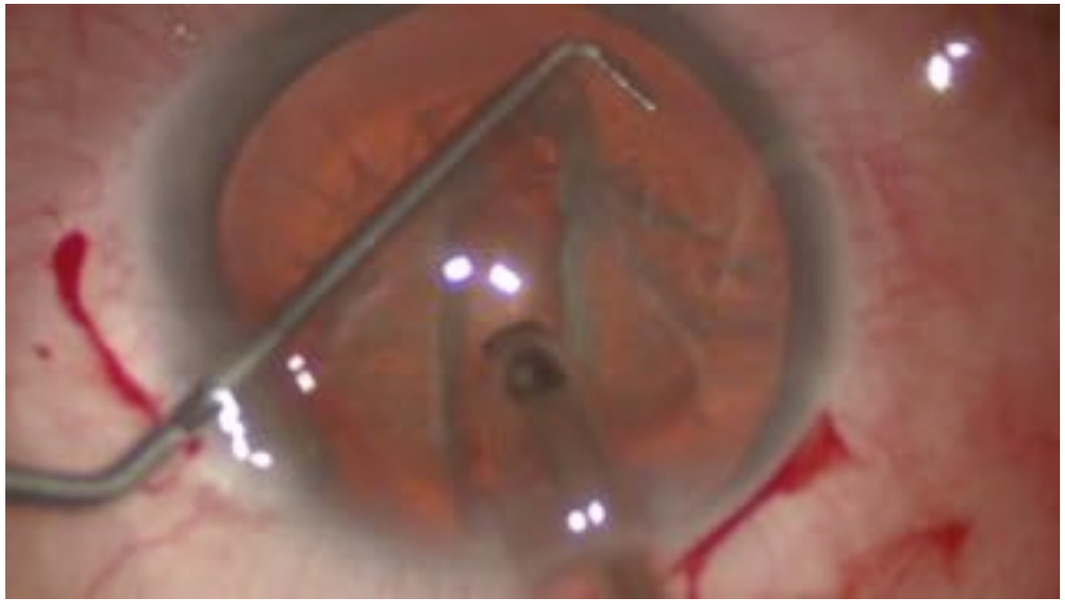

Following sculpting and cracking the lens is rotated and he first hemi-nucleus is chopped horizontally. Note that the phacoemulsification probe is impaled in the heminucleus before insertion of the chopper to stop the nucleus rotating. Also note how easy it is to place the chopper in the correct plane by moving it along the nuclear fissure.

CHAPTER 10

Removal of the epinucleus

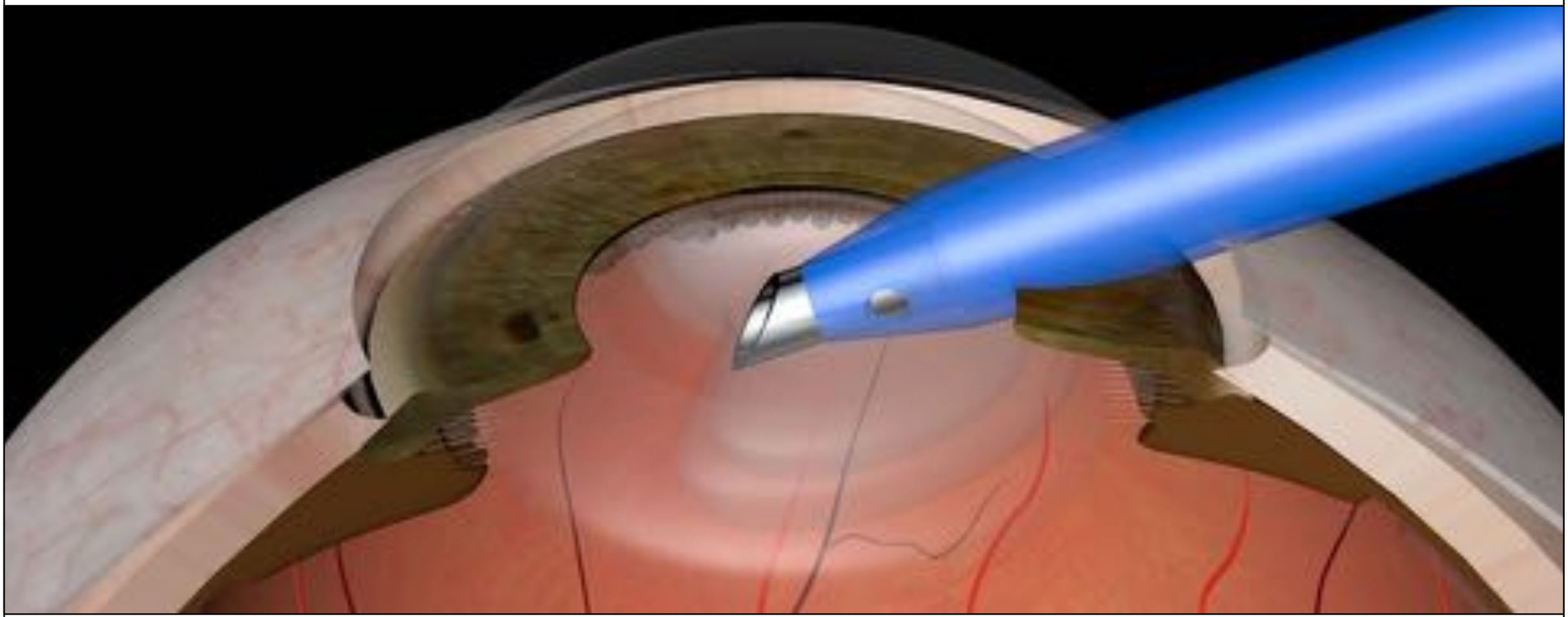

The epinucleus provides a protective shell around the endonucleus while it is removed.
After the nucleus has been removed the epinucleus is removed by aspiration, usually using the phacoemulsification probe.

The epinucleus as a protective cushion

If hydrodelineation is performed the epinucleus protects the capsule while the endonucleus is removed.

This is particularly useful when learning phacoemulsification.

Some surgeons do not perform hydrodelineation and prefer to remove the nucleus and epinucleus together.

Movie 10.1 The protective cushion

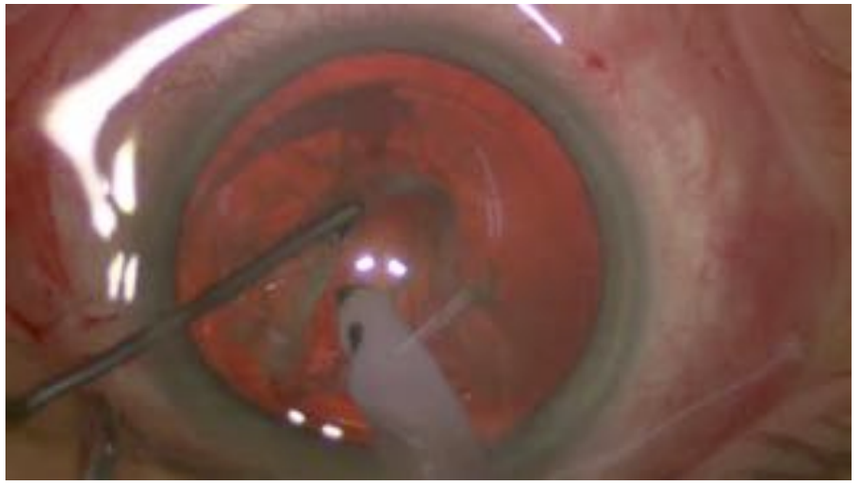

Hydrodelineation has been performed. The endonucleus separates from the epinucleus, which is protecting the capsule.

Movie 10.2 Removal of epinucleus and endonucleus together

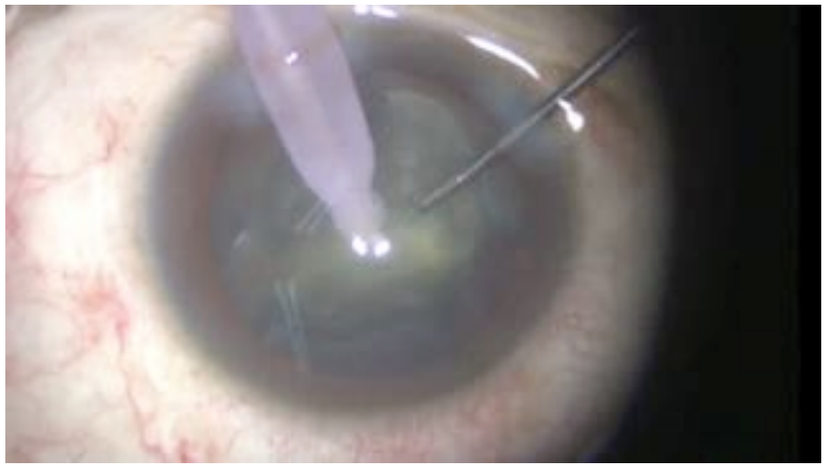

No hydrodelineation had been performed in this case.

The second instrument

A second instrument with a blunt tip may be used to rotate the epinucleus and brush the epinucleus out of the capsular bag.

The second instrument may also be held in the eye behind the epinucleus while it is being aspirated to protect the capsule. However many surgeons prefer to remove the second instrument from the eye at this stage, since the reduced leakage through the side port increases anterior chamber stability as well as fragment followability to the phaco tip.

Illustration 10.1 The role of the second instrument when removing epinucleus.

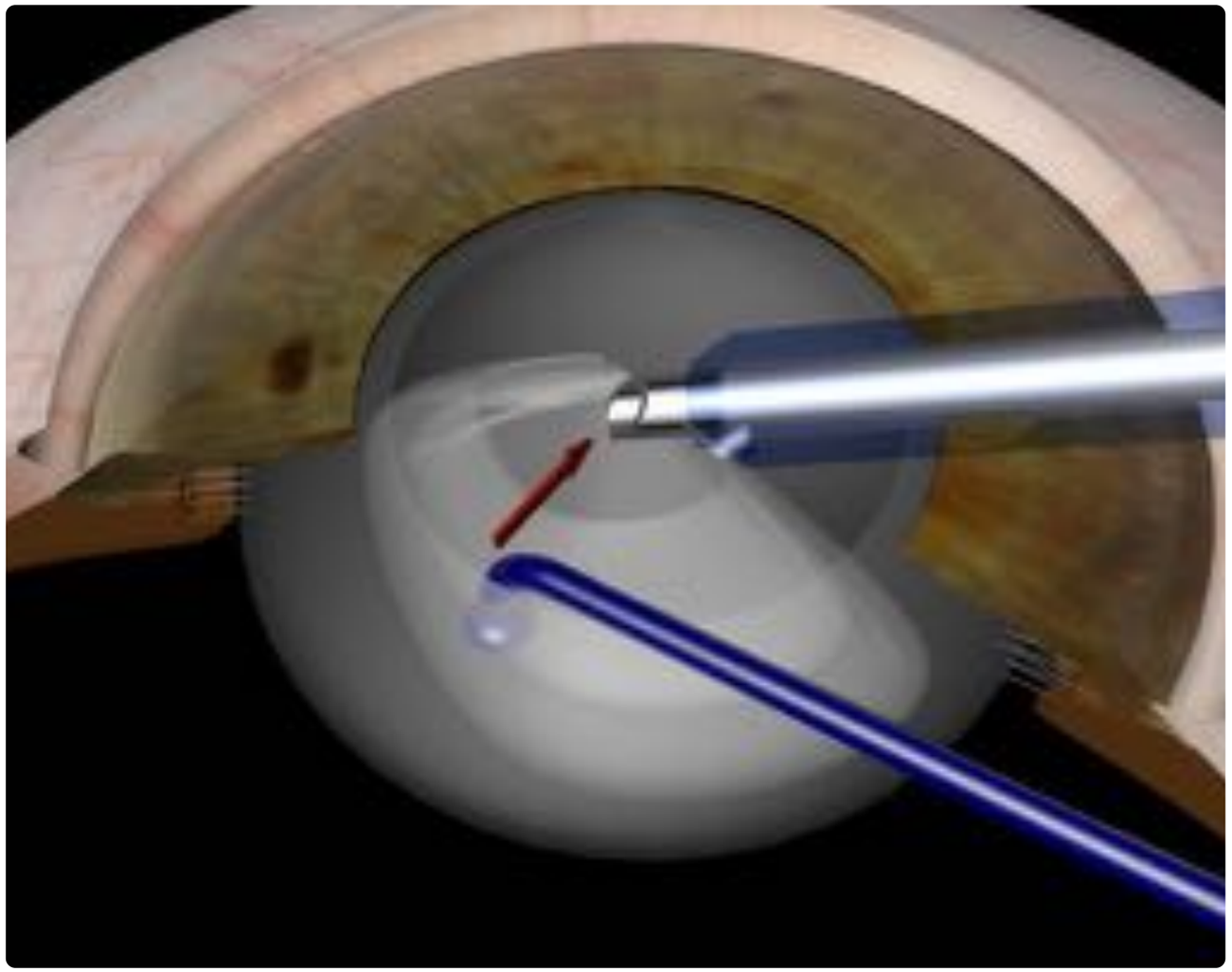

Manipulating epinucleus towards the tip of the probe.



The epinucleus is usually much softer than the endonucleus. In this case it is possible to aspirate it using the small bore irrigation/aspiration system but this is often very slow. Using a phacoemulsification probe is much more efficient.

The phacoemulsification machine is used with high infusion pressure (to protect against post occlusion surge). Linear control of the vacuum is used so that moderate vacuum is used to engage the epinucleus which is increased to aspirate it once the tip of the probe is in the safe zone. Often no ultrasound power is required. If the epinucleus is hard ultrasound may be used after the epinucleus has been drawn into the safe zone. No ultrasound energy should be used while the tip of the probe is near the capsular bag.

Many modern machines have a preset panel option for removal of the epinucleus, with linear control of vacuum in an extended range of foot position 2 and linear control of ultrasound power of about 15% in foot position 3.

This may be easier if vacuum and emulsification can be controlled independently using the yaw function on the foot pedal.

Movie 10.3 Aspiration of epinucleus (1)

The epinucleus is soft and easily deforms to occlude the tip of the probe. Once occlusion develops even moderate vacuum may cause the epinucleus to disappear very quickly. The epinucleus may disappear very quickly with a risk of post occlusion surge. While experienced surgeons may enjoy this efficiency trainees should control vacuum to achieve a more controlled removal.

Movie 10.4 Aspiration of epinucleus (2)

The more controlled removal is achieved by controlling the vacuum in foot position 2

The importance of a mobile epinucleus

If adequate cortical cleaving hydrodissection has been carried out the epinucleus is easy to rotate.

Failure of the epinucleus to rotate indicates the presence of persistent cortico-capsular adhesions. These make it much more difficult to remove the epinucleus without capsular trauma. If the capsule is still adherent then it will be aspirated with the attached epinucleus into the phaco tip.

If the epinucleus does not rotate freely further hydrodissection or viscodissection may be performed.

Movie 10.5 Mobile epinucleus

The epinucleus rotates freely and is easy to remove.

Movie 10.6 Immobile epinucleus

Due to inadequate hydrodissection the epinucleus is difficult to rotate and therefore difficult to remove.

Single-handed removal of the epinucleus

The mobilized epinucleus is engaged with low vacuum. Withdrawal of the probe, using light aspiration, moves it centrally away from the capsule. It is then aspirated in the iris plane, with a little ultrasound power if necessary.

Movie 10.7 Settings for aspiration of epinucleus

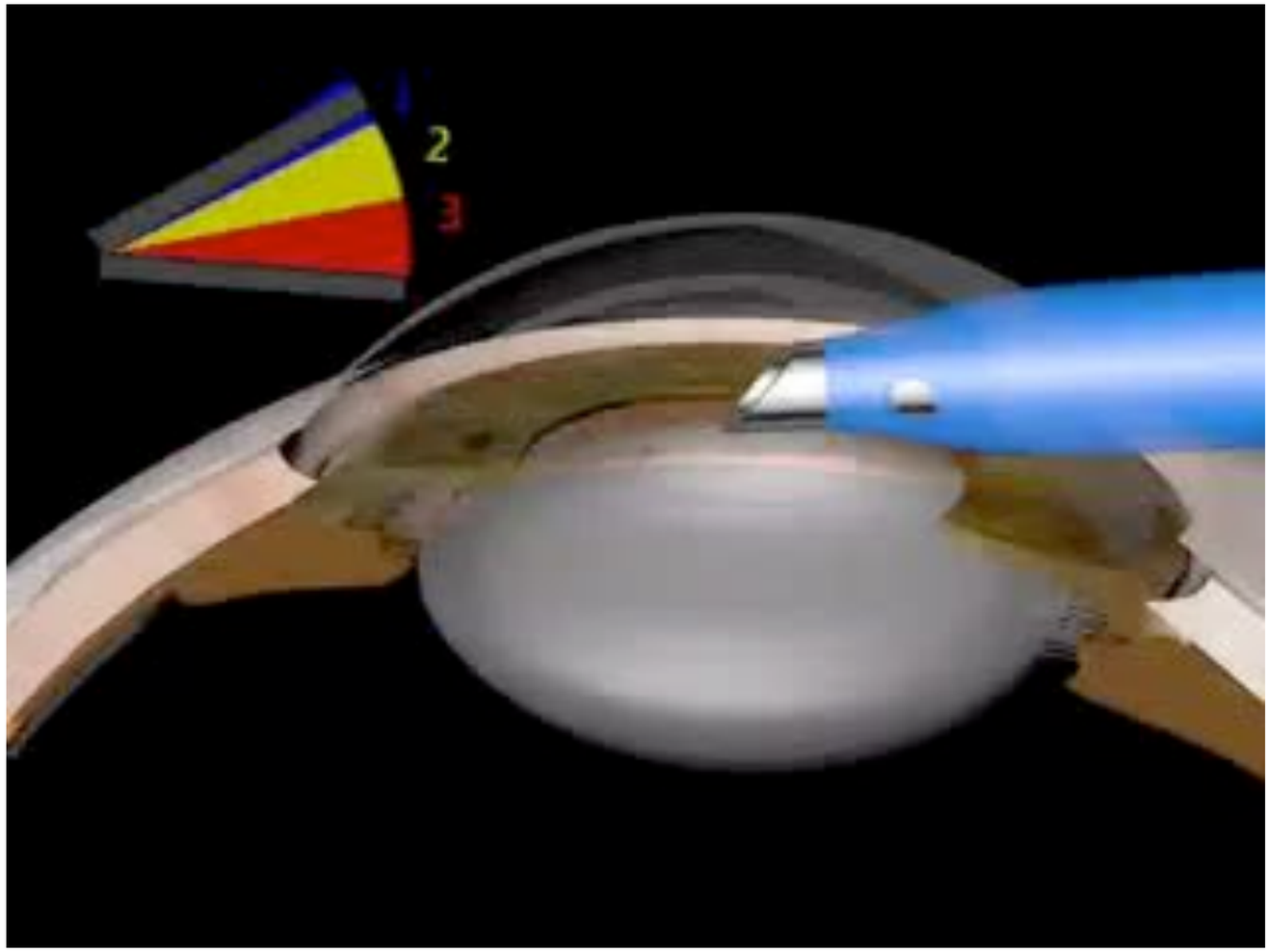

In this case pulsed ultrasound is used - this is not usually necessary. Note that only moderate vacuum and no ultrasound are used near the capsule. Higher vacuum and ultrasound (if necessary) are used in the safe zone.

This may be easier if vacuum and emulsification can be controlled independently using the yaw function on the foot pedal.

Bimanual removal of the epinucleus

The second instrument may be used to push the epinucleus inferiorly so that it flips out of the capsular bag (inverting in the process) so that it may then be aspirated.

Illustration 10.2 Using the second instrument to tumble the epinucleus out of the capsular bag.

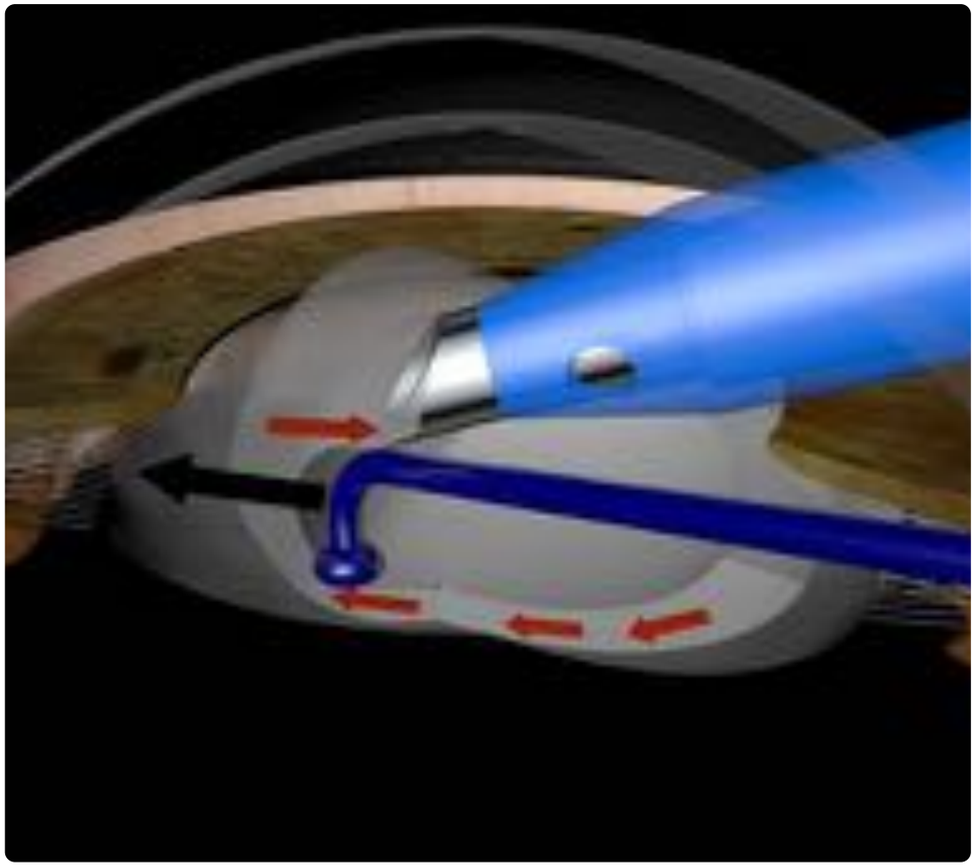

Stroking movements are made away from the surgeon.

Movie 10.8 Using the second instrument to tumble the epinucleus out of the capsular bag.

Note that following a removal of a segment of the epinuclear ring it becomes less rigid.

Removal of harder epinucleus

If the epinucleus is slightly harder it does not easily fold out of the bag. The ring of peripheral epinucleus resists the required deformation.

The rigidity of this ring is broken by aspirating a small sector of peripheral epinucleus. This can also be achieved using the chopper to break off a sector of the bowl. The resulting discontinuity in the ring allows it to deform and be aspirated. If the maneuver is performed at 2 sites 180^0 apart the removal of the rest of the epinucleus becomes straightforward.

Illustration 10.3 Breaking the epinuclear ring

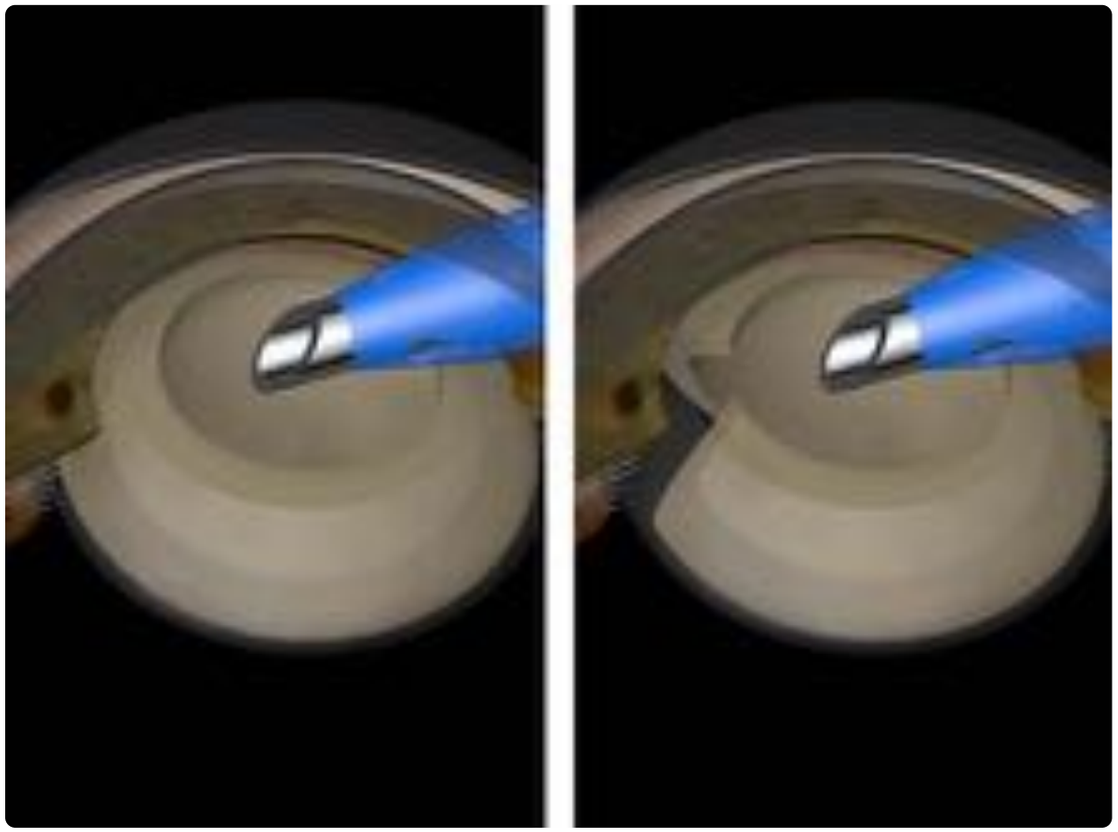

The structural integrity of a firm epinucleus (left) is destroyed by aspirating a small peripheral sector (right).

Movie 10.9 Breaking the epinuclear ring

Dealing with adherent epinucleus

Adequate hydrodissection is the best strategy for avoiding the problem of epinucleus stuck to the capsule.

It may be dealt with by hydro or viscodissection.

Movie 10.10 Adherent epinucleus

This problem may be avoided with a good cortical cleaving hydrodissection technique.

Movie 10.11 Viscodissection of adherent epinucleus

Viscodissection is used to strip adhesions between the posterior and peripheral epinucleus and the capsule.

Dealing with adherent epinucleus (2)

If viscodissection is unsuccessful it may be tempting to attempt to engage peripheral epinucleus (beyond the margin of the capsulorrhexis) with the phacoemulsification probe. This temptation should be resisted as there is a very high risk of damage to the capsule.

It is safer to use an irrigation aspiration instrument to loosen the peripheral epinucleus and draw it towards the centre of the eye, stripping the cortico-capsular adhesions. Try to always keep the aspiration port facing forwards. Grasp any free cortical fibres at the edge of the rhexis as they can be pulled to strip off the underlying epinuclues. The risk of capsular trauma is less than when using the phacoemulsification prob because:

- The port is smaller.
- The port is side facing so can engage the subcapsular lens material without risk of aspirating more peripherally.

Once the epinucleus has been loosened the epinucleus may be aspirated.

Movie 10.12 Use of irrigation/aspiration to remove adherent epinucleus

The adherent epinucleus is stripped off the undersurface of the anterior capsule rim. Once free it may be aspirated with the phacoemulsification probe or (very slowly, as in this case) with the irrigation/aspiration handpiece.

Illustration 10.4 Loosening adherent epinucleus

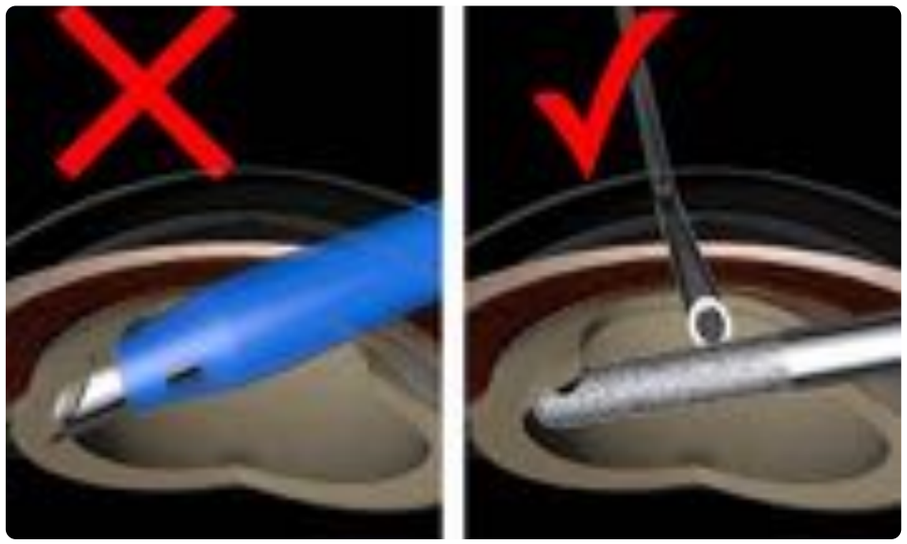

The phacoemulsification probe should not be used to aspirate peripheral epinucleus. An irrigation/aspiration instrument is much safer because of its smaller port and side opening.

Knowledge Review

Movie 10.14 Surgical video 1a

Movie 10.13 Surgical video 1b

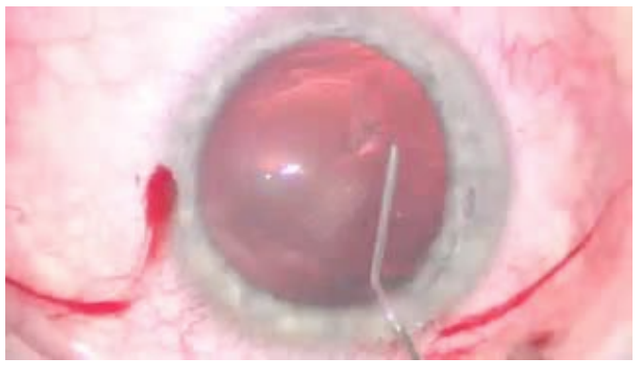

Look at these 2 videos. They show different stages of the same operation. The eye has a mild nucleosclerotic cataract with no sign of posterior capsular plaque or defect.

1. What is happening during Movie 1a?

2. How could it be managed?

3. Watching Movie 1b , what factors can you see that lead to this outcome?

CHAPTER 11

Removal of lens cortex

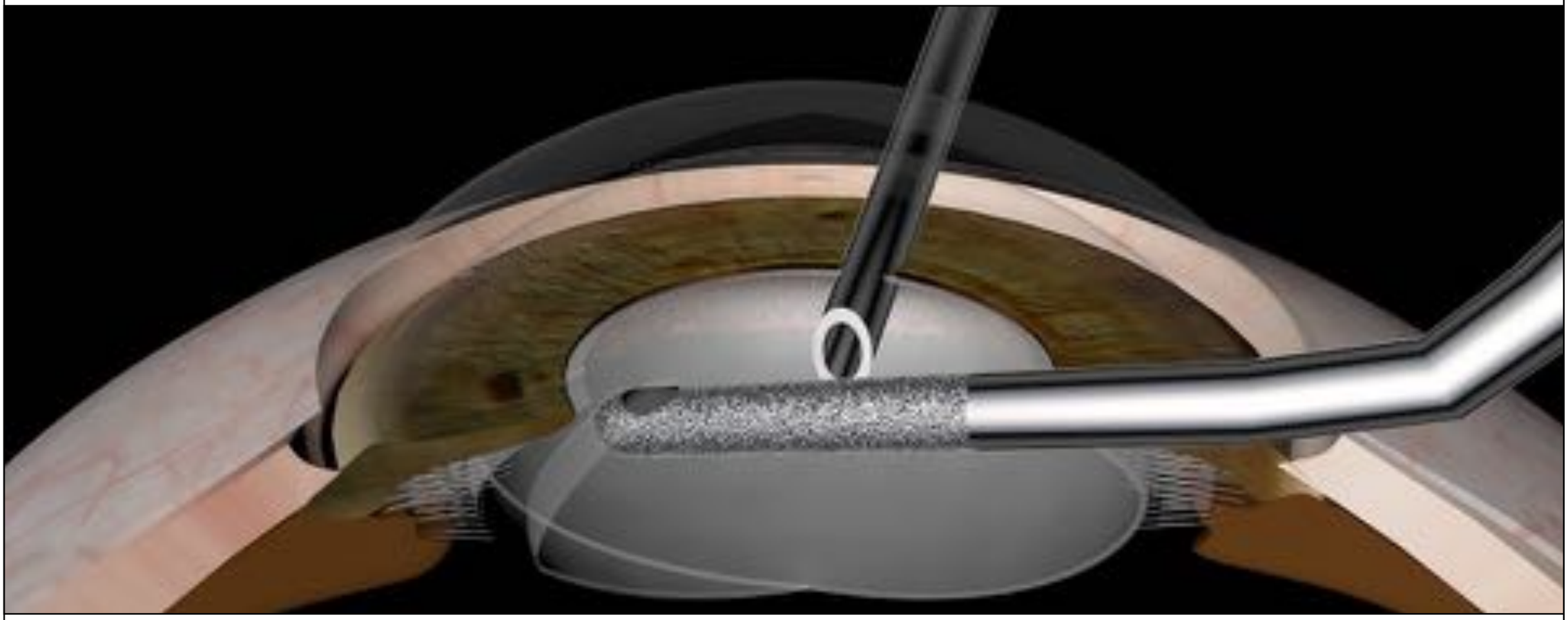

During irrigation/aspiration of residual cortex the capsule is exposed and vulnerable. This is the stage at which most capsular ruptures occur. The risk of this may be reduced by following some simple rules.

General principles

Figure 11.1 Posterior capsule opacification.

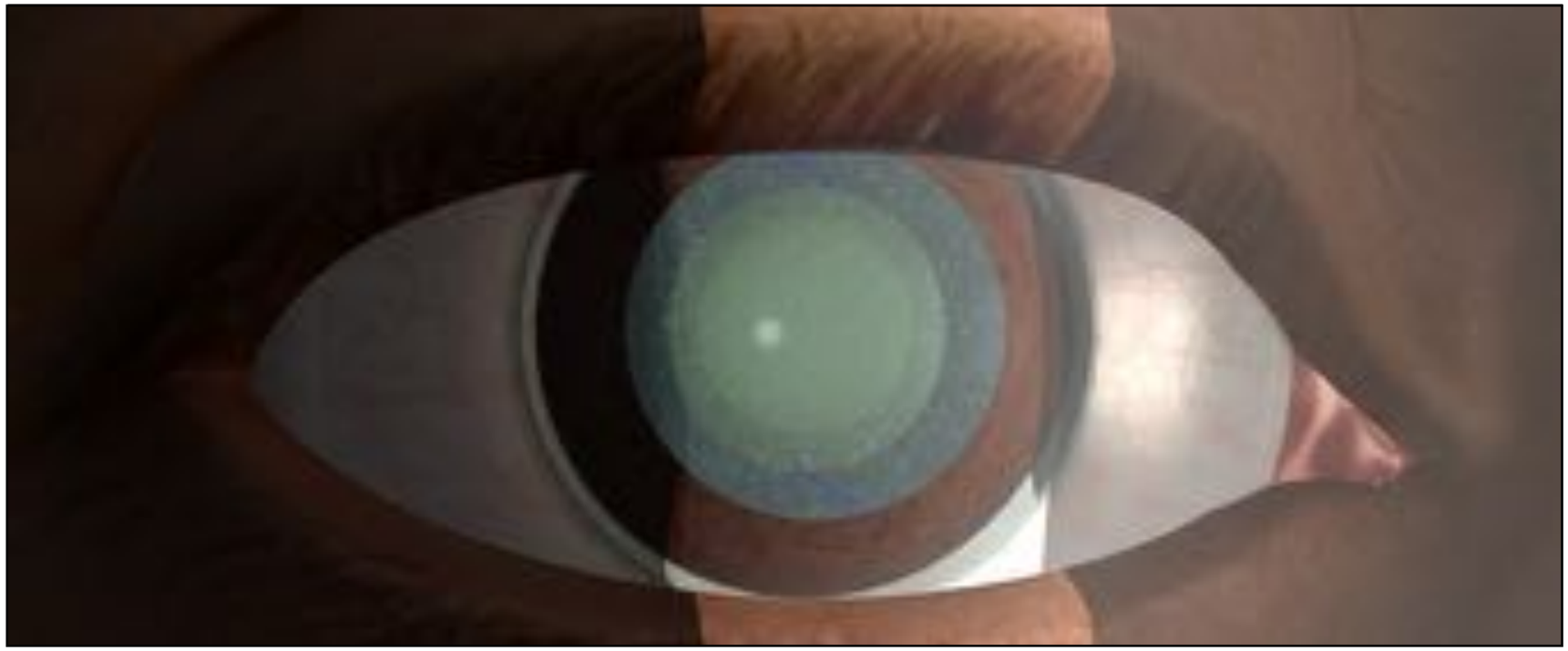

If cortical cleaving hydrodissection has been carried out correctly very little adherent cortex should remain after the nucleus has been removed.

The remaining cortical fibers are adherent to the capsular bag. Their removal is desirable to:

- Reduce posterior capsule opacification, which is a consequence of proliferation of residual lens epithelial cells.
- Reduce post operative inflammation (as these immunologically sequestered proteins are recognized as antigenically foreign by the immune system).

Irrigation/aspiration technique

Whichever instrument is used to remove residual cortex, the technique used is:

1. Move the instrument so that the tip lies just beyond the edge of the capsulorrhexis. The instrument is orientated with port facing upwards.
2. Aspirate gently to engage the cortex. Once the port is occluded the instrument is moved towards the centre of the eye, increasing the vacuum and stripping the cortex.
3. Circumferential sweeps may be made under the capsule while aspirating in order to gather lens material into the aspiration port. This increases the grip of the port on the cortex when stripping it off the capsule.
4. Once the cortex is in the safe zone the vacuum is increased to a level sufficient to aspirate the (now free) cortical material.
5. The risk of posterior capsule aspiration is reduced by keeping the port facing upwards, which is nearly always possible.

Illustration 11.1 The principles of irrigation/aspiration

The cannula is placed, port facing up, against the cortex just outside the capsular rim. Foot position 1 is used (continuous irrigation is helpful so that inadvertent movement into Foot position) does not cause anterior chamber collapse).



Movie 11.1 Circumferential sweeps to increase the grip on the cortex

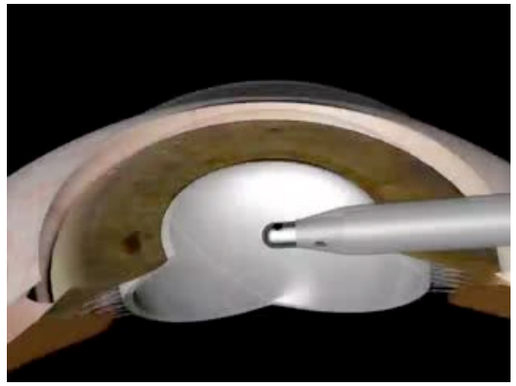

The Subincisional Cortex - remove it first

The capsular bag is initially splinted open by the cortex. As this cortex is removed the anterior and posterior capsule collapse together. Finally it becomes more difficult to establish the plane between the leaves. For this reason it is advisable to remove the subincisional cortex first, while the capsular bag remains open. This is particularly important when using a coaxial irrigation/aspiration instrument.

Illustration 11.2 The capsular bag



The presence of the cortex is splinting the capsular bag open.



Residual strands of cortex

Fine residual strands of cortex which are too thin to occlude the aspiration port may be removed by engaging them with circumferential sweeps of the aspiration cannula more peripherally in the capsular bag. Great care should be taken when doing this as there is a risk of capsular injury. Alternatively these strands may be left as they generally resorb post operatively. *Perfect* can be the enemy of *good*.

Movie 11.2 Residual strands of cortex (1)

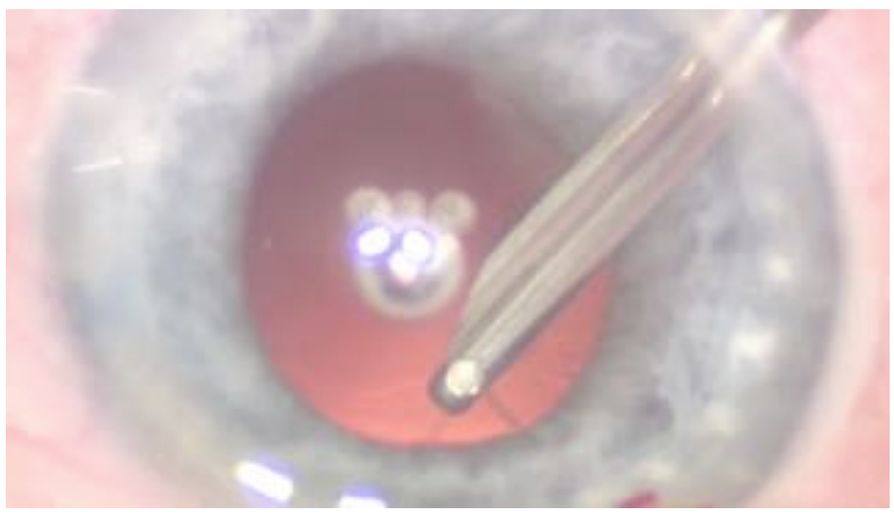

Pulling on the loose ends of these whispy fibers is ineffective. They are simply too thin to occlude the aspiration port.

Movie 11.3 Residual strands of cortex (2)

The only way of removing them is too engage them more peripherally, with circumferential sweeps in the periphery of the capsular bag if necessary.

Irrigation/aspiration instruments

Figure 11.2 Irrigation/aspiration instruments

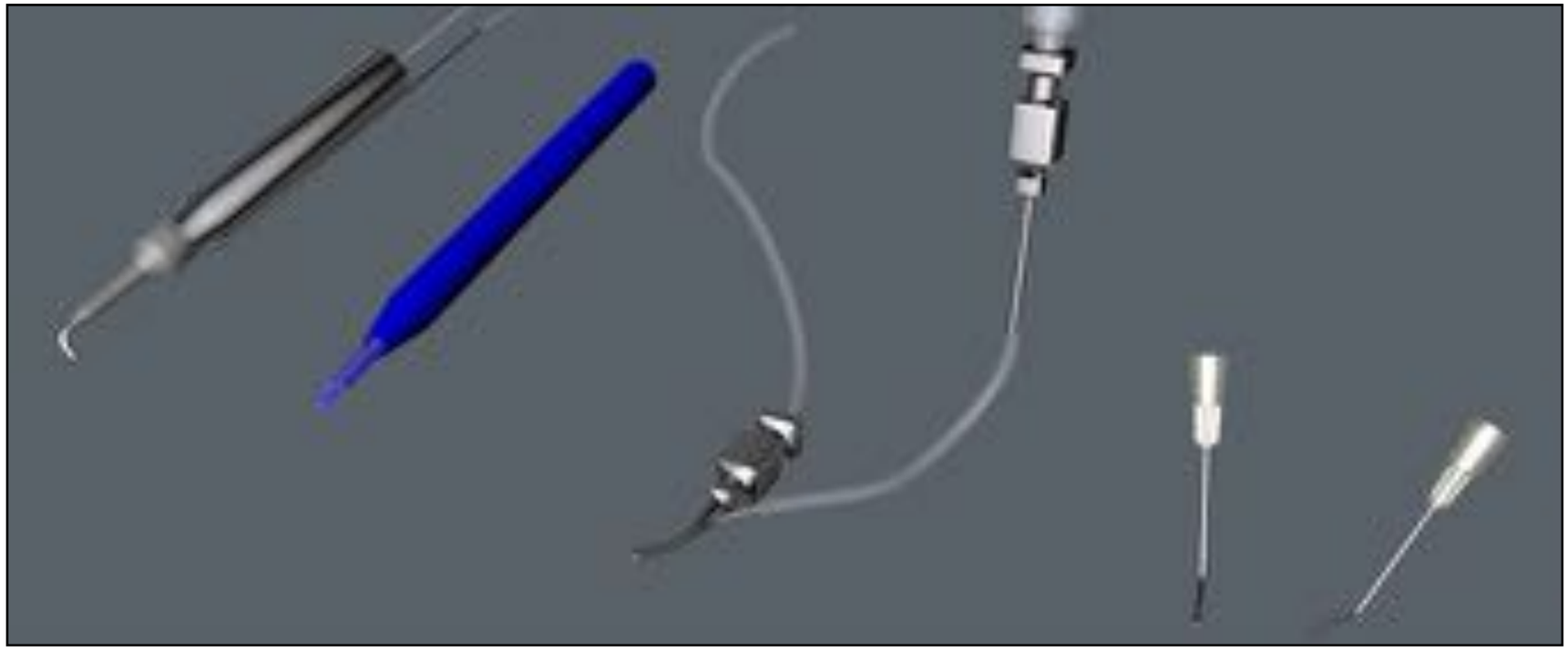

From the left: a coaxial irrigation-aspiration instrument, a silicone tipped coaxial handpiece. a Simcoe cannula and a bimanual irrigation-aspiration system.

Irrigation/aspiration systems may be classified as:

- Manual (e.g. the Simcoe cannula).
- Unimanual automated (e.g. the coaxial irrigation/aspiration system).
- Bimanual automated.

Manual irrigation-aspiration systems

Manually driven aspiration systems such as the Simcoe cannula offer very precise control of aspiration.

One disadvantage to their use is that the infusion flow is parallel with the axis of the instrument and therefore tends to blow mobile pieces of cortex away from the instrument.

Because of its' rigidity and linear form it may be difficult to remove subincisional cortex. The axial rotation and torque required of the instrument causes corneal distortion which degrades the view and encourages wound leakage with chamber instability. This may be addressed by making further side ports, the correct width of which needs to be estimated by the surgeon.

Illustration 11.3 The Simcoe cannula

The system is manually driven using the thumb.



Movie 11.4 The Simcoe cannula in use

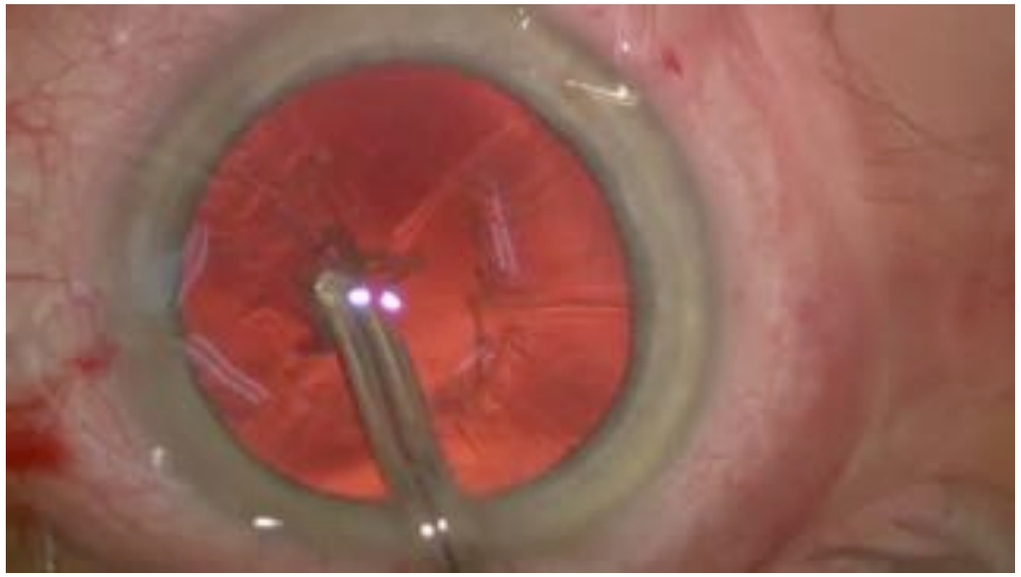

Use of a side incision allows the subincisional cortex the be dealt with. While the coaxial infusion tends to blow lens matter away from the tip it does help to keep the capsular bag inflated. This is a vitrectomized eye: the frequent changes in pupil diameter are a consequence of infusion deviation syndrome.

Automated coaxial cannulas

The vacuum, generated by the machine pump, is under linear foot pedal control.

Because of their diameter these cannulas can be used only through the main incision.

It is therefore particularly important to deal with the subincisional cortex first with these systems, while the capsular bag is held open.

The aspiration port should ideally be held facing forwards towards the surgeon, minimising the risk of capsule aspiration. This is largely achievable through pivoting within the incision rather than axial rotation of the handpiece, which should be resisted as much as possible.

Illustration 11.4 Automated coaxial irrigation/aspiration cannulae



The traditional straight tip. Compressible infusion sleeves like this one conform to the wound, reducing leakage and increasing anterior chamber stability.



Movie 11.5 The subincisional cortex

When a straight cannula is used it is tilted port sideways to achieve occlusion then rotated port upwards when occlusion has developed. In practice this causes corneal distortion which increases incisional leakage and distorts the view which is not shown in this animation.

Angled automated coaxial cannulas

As well as the linear form a number of angled tips are available to allow easier access to the subincisional cortex without undue corneal distortion.

The introduction of a silicone sleeve reduced incisional leakage, allowing for a more stable anterior chamber.

Movie 11.6 Removal of subincisional cortex using an angled "hockey stick" coaxial i/a cannula

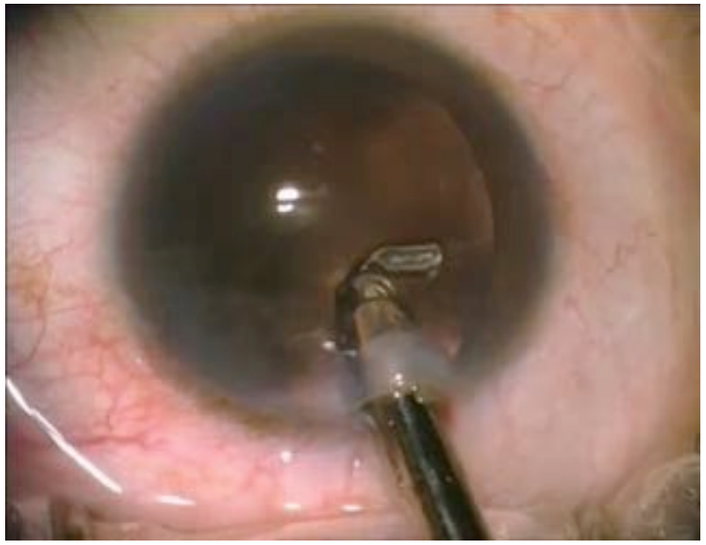

A combination of rotation of the cannula, pivoting in the wound and movement into the eye strips the cortex from the capsule. In this case there is no soft silicone sleeve - note the incisional leakage around the rigid metal cannula.

Movie 11.7 Silicone sleeve

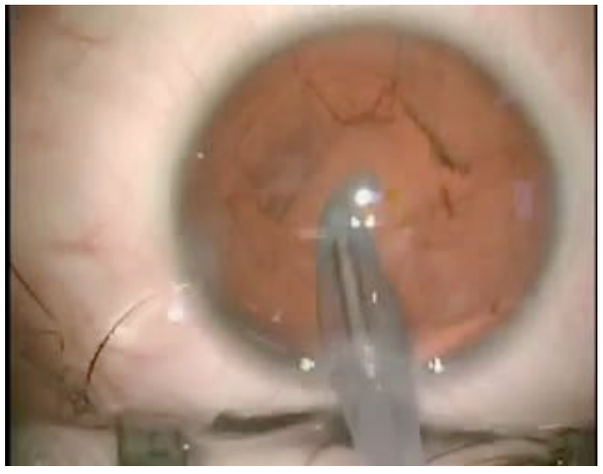

Note the reduced incisional leakage.

Silicone tipped automated coaxial cannulas

Silicone tipped coaxial aspiration instruments have several advantages:

- Smooth aspiration ports and elimination of sharp edges reduces the risk of capsular trauma
- The flexible tip facilitates access to anterior, peripheral and subincisional capsule
- The semitransparent sleeve improves the view
- The adhesive properties of the silicone tip facilitate cortical stripping and lens dialling

Illustration 11.5 Soft silicone tip aspiration

There is evidence that use of a silicone tip reduces the risk of capsular trauma during cortical cleanup.

Movie 11.8 Silicone tipped coaxial cannulas

Note the atraumatic capsular engagement (indicated by the appearance of star folds).

Bimanual automated irrigation/aspiration systems

A bimanual approach eliminates the problem of subincisional cortex and allows firmer pieces of cortex to be dealt with by mashing them into the aspiration port.

Different bimanual cannulas share many features but there are some significant differences (for example in their length, calibre and aspiration port number, orientation and diameter) which should be understood before using them in they eye. These make significant functional differences to fluid balance and chamber stability. A short, open-ended irrigation cannula allows a high flow rate due to its low resistance.

Illustration 11.6 Bimanual i/a systems - aspiration

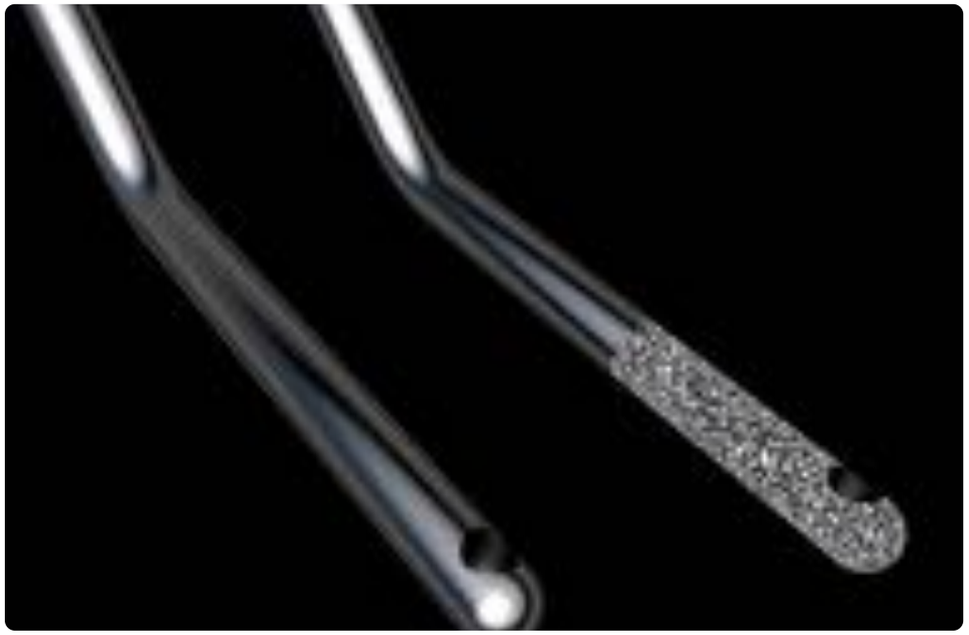

Bimanual aspiration cannulas. All have a 40-50^0 bend with a port on the upper surface. Some have textured tips to facilitate capsule polishing.

Illustration 11.7 Bimanual i/a systems - irrigation



Bimanual infusion cannulas. The orientation of the infusion port varies, which affects the direction of flow of infusion fluid. The resistance varies widely. This has to be taken account of when setting machine parameters to avoid anterior chamber collapse.

Bimanual automated irrigation/aspiration

Bimanual systems allow instruments to be exchanged between ports. This facilitates access to subincisional cortex.

Wound neutrality, a universal principle in cataract surgery, is particularly important when two instruments are in the eye simultaneously. Failure to pivot at the wound may stress the incisions, leading to wound gape and anterior chamber collapse.

Illustration 11.8 Bimanual i/a in use

The infusion cannula is introduced first. It sits in the middle of the bag to keep it inflated. The aspiration cannula crosses the midline to aspirate cortex on the other side of the eye. The instruments are then swapped to complete the cortical clean up. When they are swapped the aspiration cannula is removed before the infusion cannula to prevent chamber collapse.

Movie 11.9 Bimanual i/a in use

Note that if occlusion is not readily achieved sweeps under the capsule may help. The infusion cannula is used to mash harder cortex into the aspiration port, which allows a lower vacuum to be used. The infusion cannula is always first instrument in and last instrument out.

Capsular trauma during irrigation/aspiration

Capsule trauma during irrigation/aspiration: zonule dialysis and capsular star folds

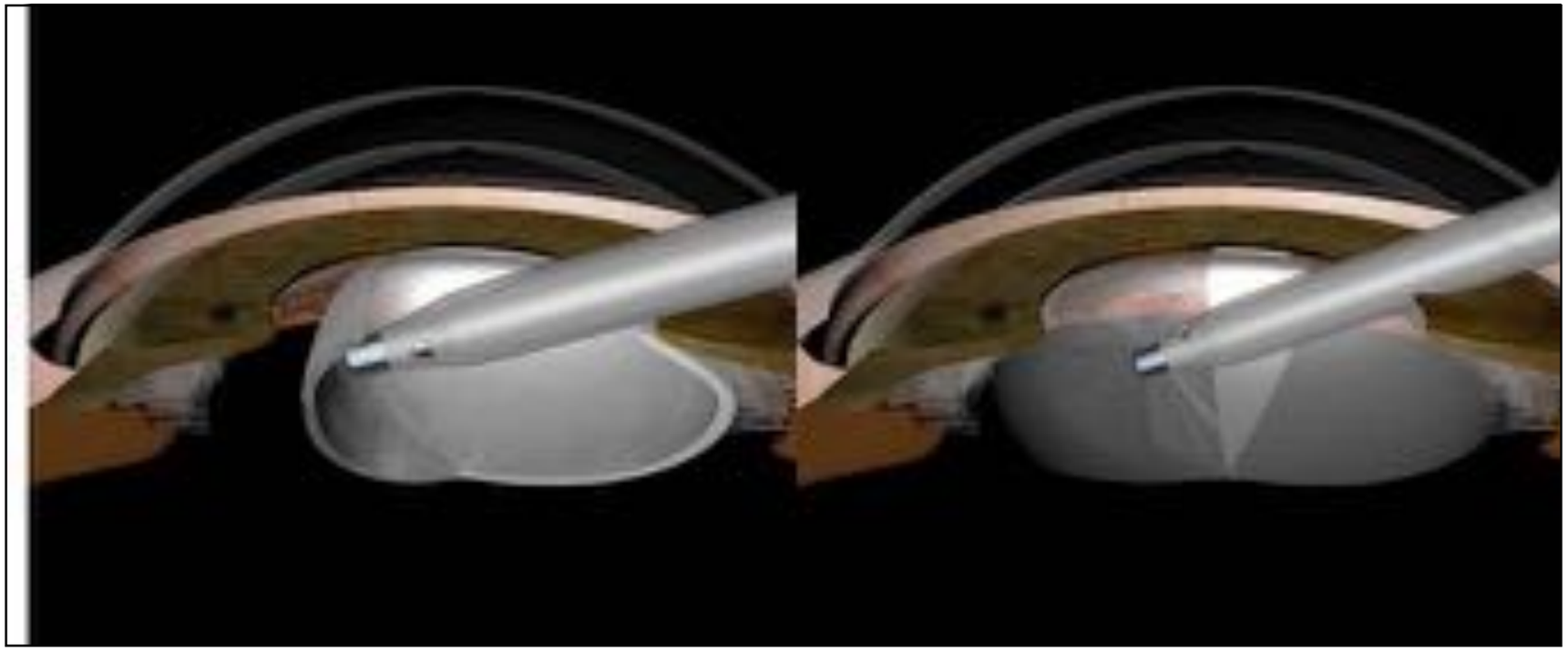

Zonular dialysis and posterior capsular tear may occur during irrigation/aspiration. There are useful visual clues that these are about to occur.

Star folds.

The capsule is only moderately elastic. If a portion is aspirated into the cannula then folds radiating outward from the tip of the cannula ('star folds') develop. The slightest movement of the cannula at this stage is liable to puncture the capsule.

Many manufacturers now produce "soft (silicone)-tipped" aspiration cannulas which minimize the risk of capsular tear after aspiration.

If star folds are seen:

- The cannula should be kept completely still.
- The foot switch should be moved from position 2 to foot position 1. Depending on the machine settings this may cause reflux with release of the capsule.
- If the star folds do not disappear reflux should be initiated using the appropriate footpedal control (this varies - the trainee should practice this before surgery so that it can be performed easily if required).

Movie 11.10 Star folds

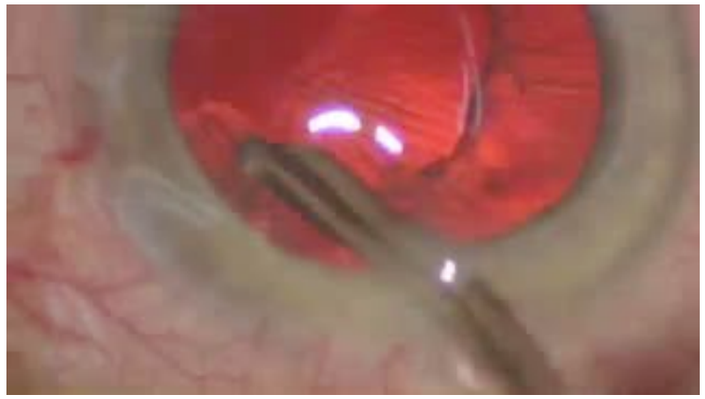

Note that the capsule is released without capsular puncture. This is because aspiration is immediately stopped and the cannula is held perfectly still until the capsule is released by moving into foot position 1.

Illustration 11.9 Footpedal reflux

Reflux of aspirated capsule using the footpedal. Vacuum must be discontinued before doing this.

Zonule dialysis

If the peripheral lens capsule is aspirated into the port the capsular bag may be stripped away from it's zonular adhesions when the cannula is drawn centrally. A linear lucency appears that must be central to the pupil margin to be visible. This is the edge of the capsular bag. If released it tends to snap rapidly back towards its' original position (unless there has been very severe zonular trauma).

Illustration 11.10 Zonule dehiscence vs. aspirated cortex

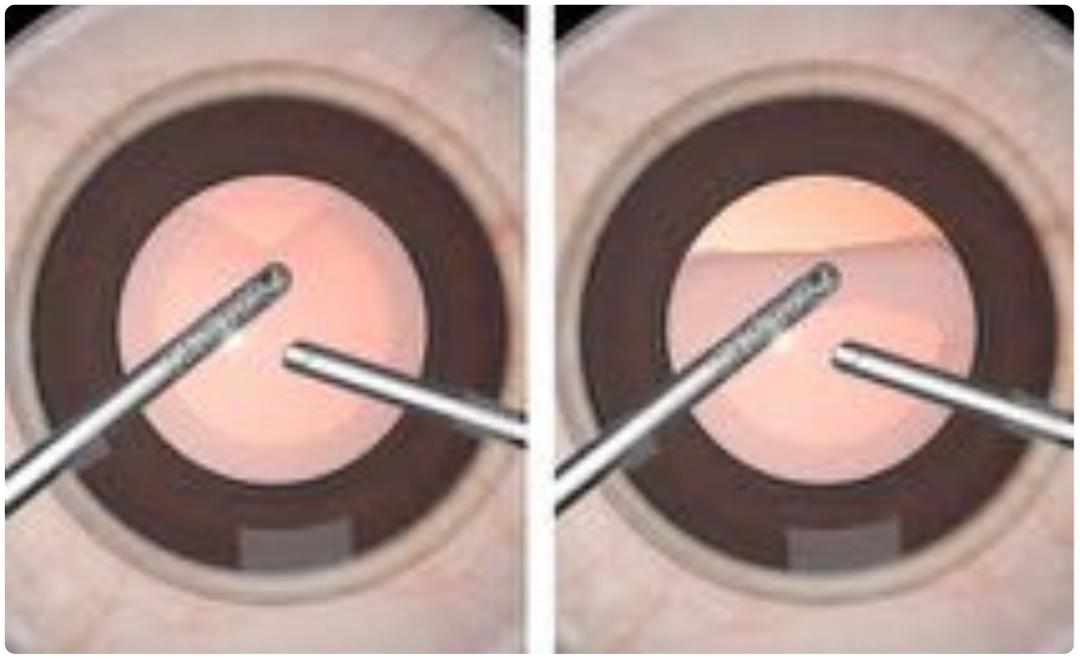

The cortex usually peels off in thin triangular strips but if it is very thick this triangle may be quite broad. In this situation confusion may arise regarding whether the cortex or the whole capsular bag is being pulled. The image on the left shows a wide strip of cortex being separated. The image on the right shows engagement of the capsule with zonular dehiscence. Note that in the image on the left the capsulorhexis does not move and the delaminating edge of cortex has a more bowed appearance than the linear lucency at the edge of the bag in the image on the right.

Movie 11.11 Zonule dehiscence

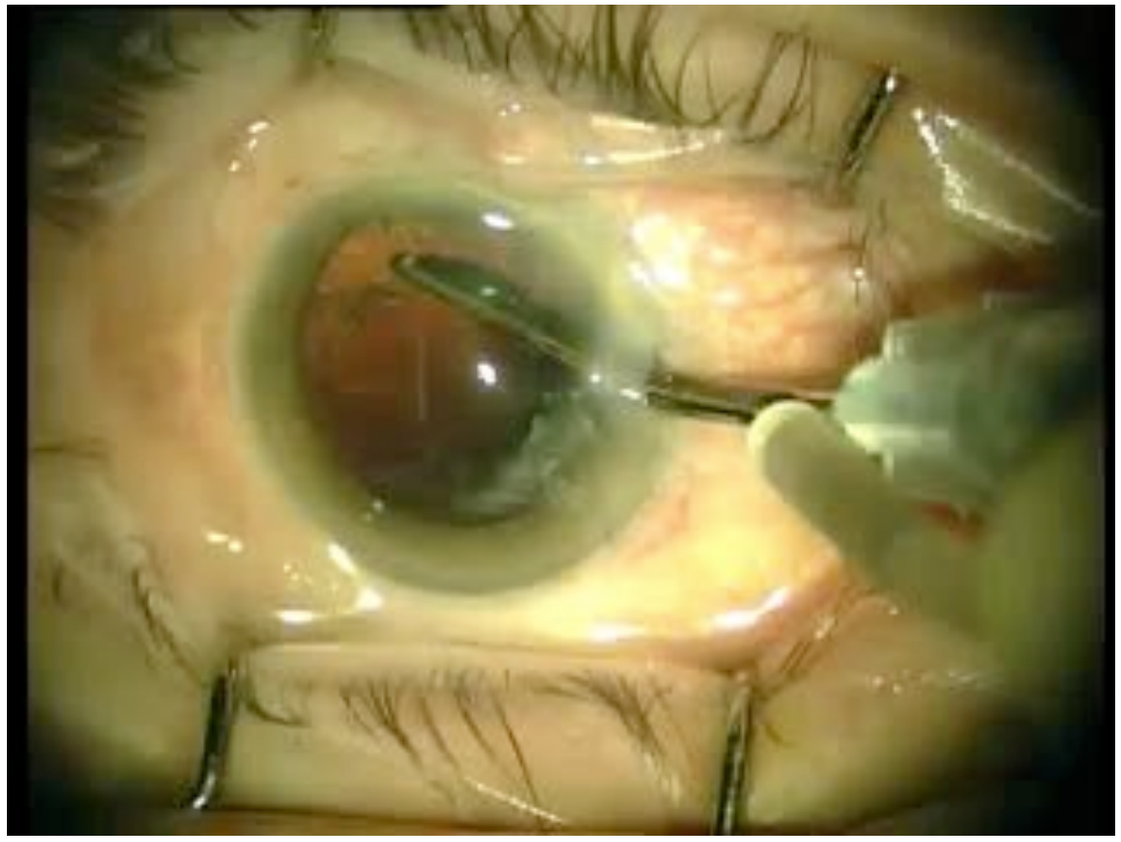

The surgeon is aspirating the capsular bag, presumably assuming that the edge which comes into view is the edge of a piece of cortex being stripped away from the capsule. The capsular edge is more linear in appearance than the delaminating border of a strip of cortex.

Zonule dialysis - warning signs

A useful warning sign is a change in the shape of the margin of the capsulorhexis, which flattens off as the local zonules are stretched or broken. This is a cue to release occlusion (move into foot position 1). The capsule snaps rapidly back into position.

Movie 11.12 Aspiration of capsule

Note the change in the shape of the capsulorhexis.

Movie 11.13 Aspiration and release of capsule

The anterior capsule is being polished, the bag has been inflated with viscoelastic. Note how quickly the capsule snaps back into position.

Management of capsule dehiscence

If a localized zonular dehiscence develops:

- It is considered best practice to insert a capsular tension ring (CTR) straight away to immediately protect the remaining zonules and minimise the risk of extending the dialysis.
- The cortex in unaffected areas can be carefully removed *before* insertion of a CTR but should be abandoned if there is any sign that the dehiscence is extending.
- A capsular tension ring is then inserted.
- In both cases the remaining cortex is aspirated with cicumferential sweeping movements.

Movie 11.14 Management of zonule dehiscence

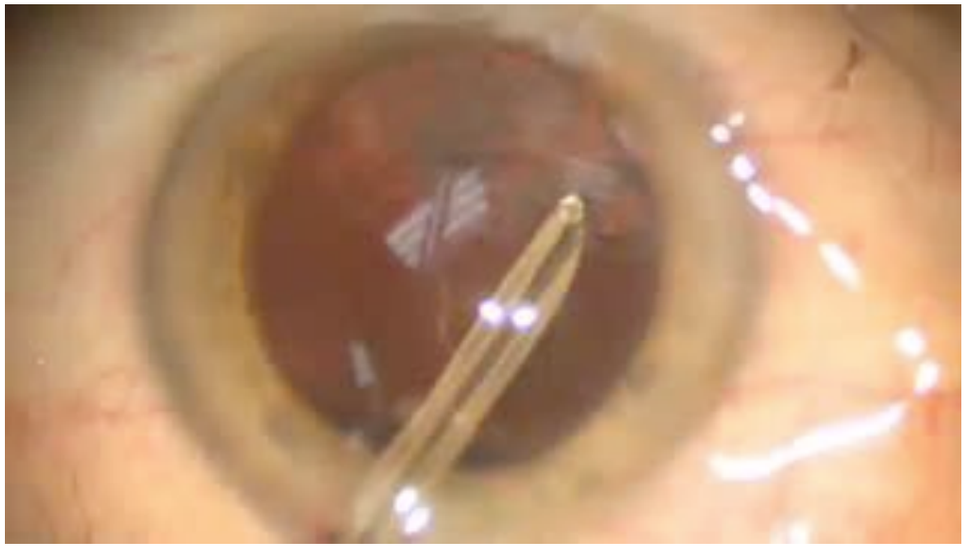

Insertion of a Morcher ring allows aspiration of residual cortex.

Capsule polishing

Figure 11.3 Capsule polishing

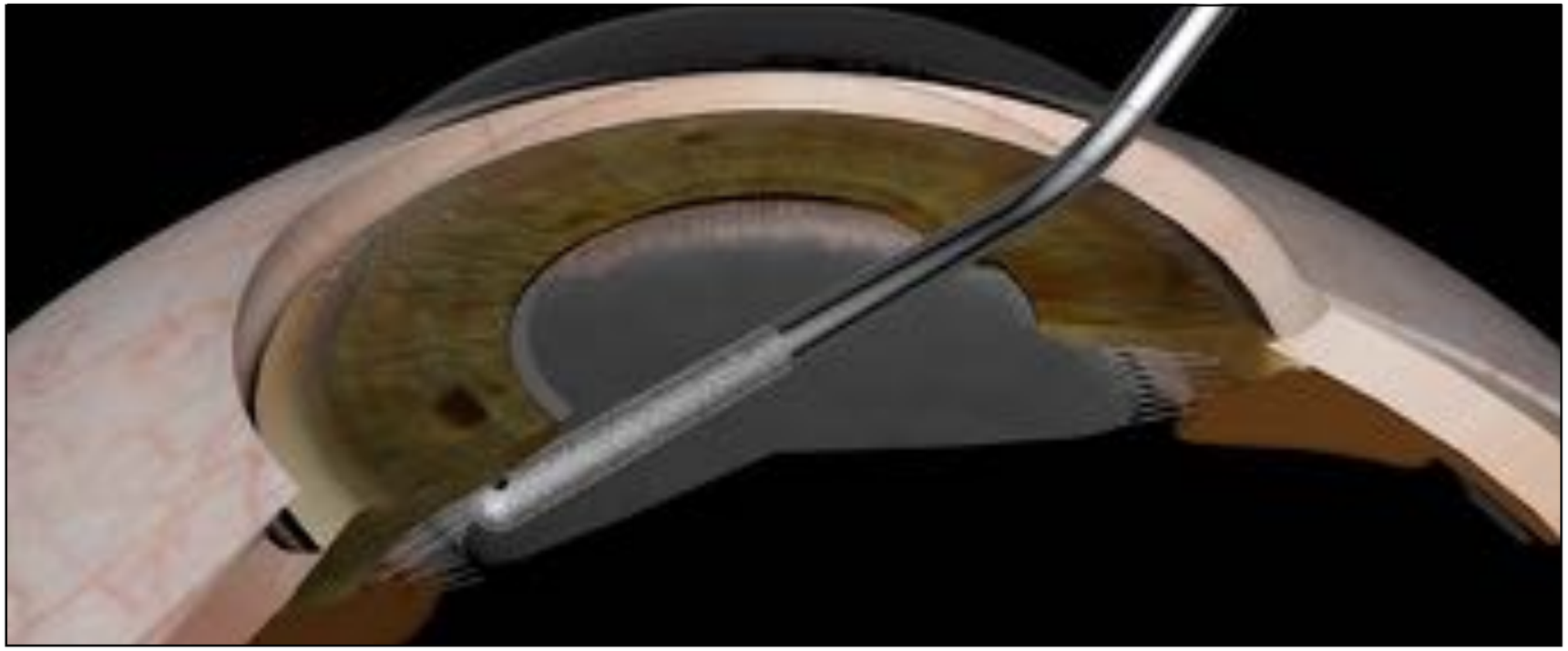

A Kratz polisher removing epithelial cells from the under surface of the anterior capsule

Very small fragments of lens material may remain after cortical clean up:

- Residual epithelial cells on the anterior capsule may contribute to capsular opacification and (in particular) capsular phimosis.
- Longstanding plaques on the posterior capsule may be quite adherent. A pragmatic judgement must be made on a case by case basis regarding the degree of capsular polishing to be undertaken. A delayed YAG laser capsulotomy is preferable to an intraoperative capsular tear.

Instruments for capsule polishing

Specialized instruments such as the Kratz polisher have textured tips for polishing. When the instrument is stroked along the lens capsule the roughened surface removes loosely adherent lens material. These instruments have an infusion port whose principle purpose is to maintain the anterior chamber. The jet of fluid from the infusion also helps to dissect partially separated sheets from the capsule.

The aspiration cannula of many bimanual instruments also has a textured tip for polishing: friction from the roughened surface of the aspiration cannula loosens lens material which may then be aspirated. The design of these instruments is important. Ideally the port aperture should be smoothly polished or chamfered rather than roughly punched out or drilled. This greatly reduces the likelihood of any aspirated capsule being torn, especially when polishing the undersurface of the anterior capsule.

A soft silicone tip is particularly useful for capsular polishing.

Illustration 11.11 Polishing instruments

The Kratz polisher has a roughened tip and an upward facing infusion aperture.

Anterior capsule polishing

Proliferation of epithelial cells on the anterior capsule causes postoperative capsular opacification.

Migration of these cells to the posterior capsule may be prevented by the combination of a square edged lens implant with a capsulorhexis which just overlaps the margin of the lens optic.

Residual epithelial cells may still contribute to anterior capsule opacification which can cause the capsulorhexis to phimose, causing troublesome glare. For this reason many surgeons prefer to remove any visible cells on the anterior capsule. In addition, removing cells from the under-side of the anterior capsule statistically-significantly reduces the capsulorhexis shrinkage (phimosis).

Illustration 11.12 Anterior capsule phimosis

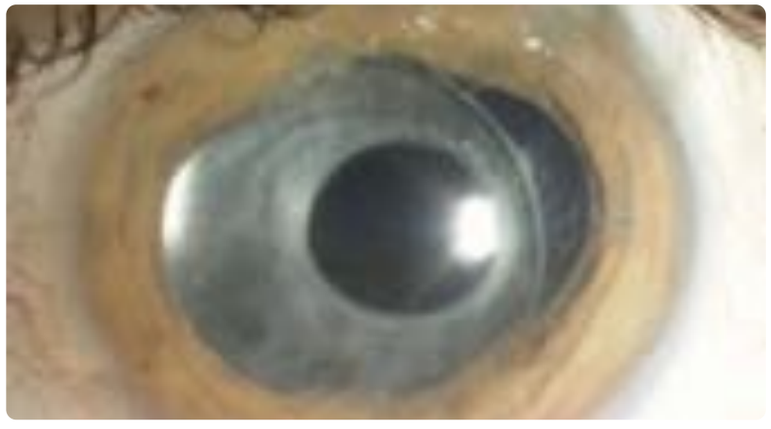

Proliferation of epithelial cells on the anterior capsule, some of which develop fibroblastic characteristics and subsequent contraction. This patient had disabling glare.

Movie 11.15 Anterior capsule polishing

In this case the capsular bag was inflated with viscoelastic - this is not always necessary.

Posterior capsule polishing

Residual lens material may be removed by a combination of abrading the capsule with a textured tip, hydrodissection with jets of infusion fluid and aspiration of any free edges. If the capsular bag is too flaccid then viscoelastic inflation puts it under tension.

Very adherent plaques which resist attempts at polishing are best left alone. The risks of subsequent YAG laser capsulotomy are very low.

Illustration 11.13 Posterior capsule polishing

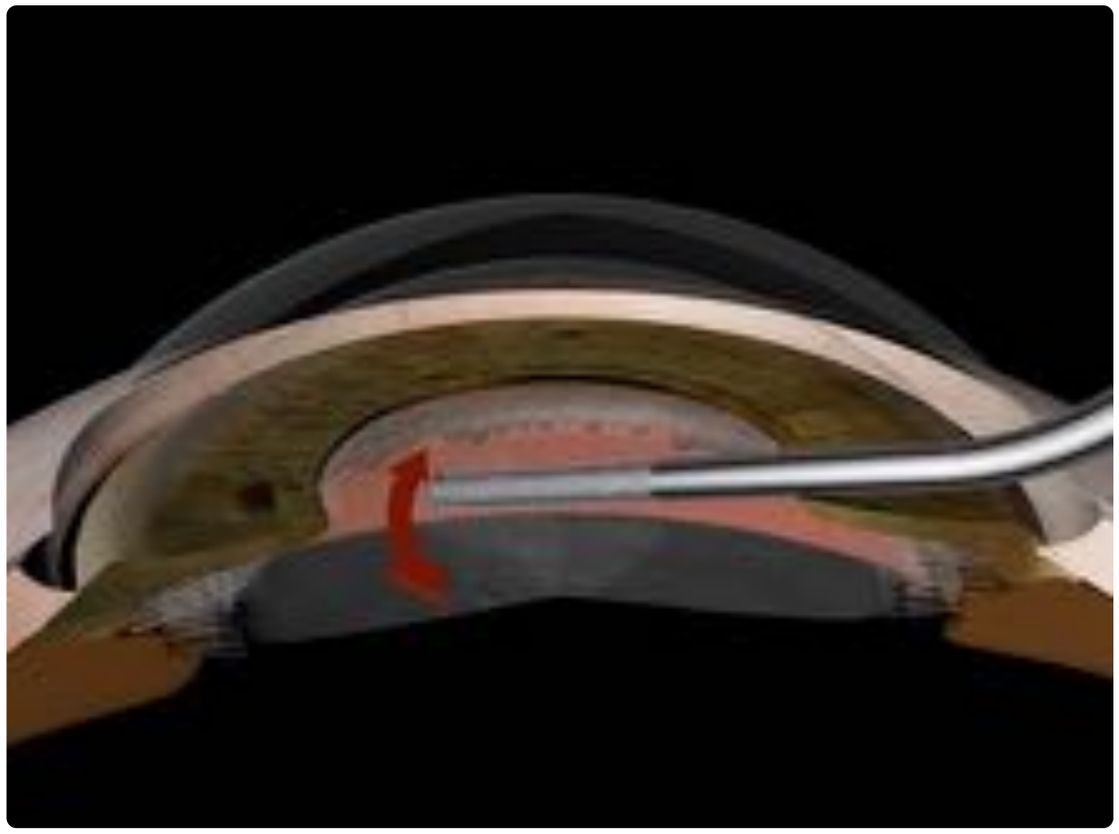

The plaque is repeatedly brushed with the polisher, working particularly on the edges.



Knowledge Review

Movie 11.16 Clinical video 1

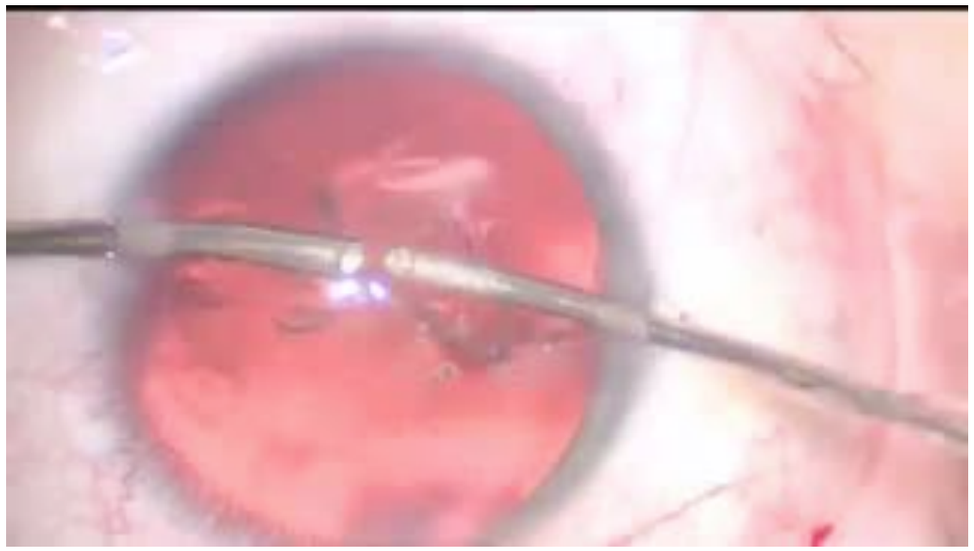

What does this video show?

Why does it happen?

What are the possible consequences?

(Scroll down for the answers)

Movie 11.17 Clinical video 2

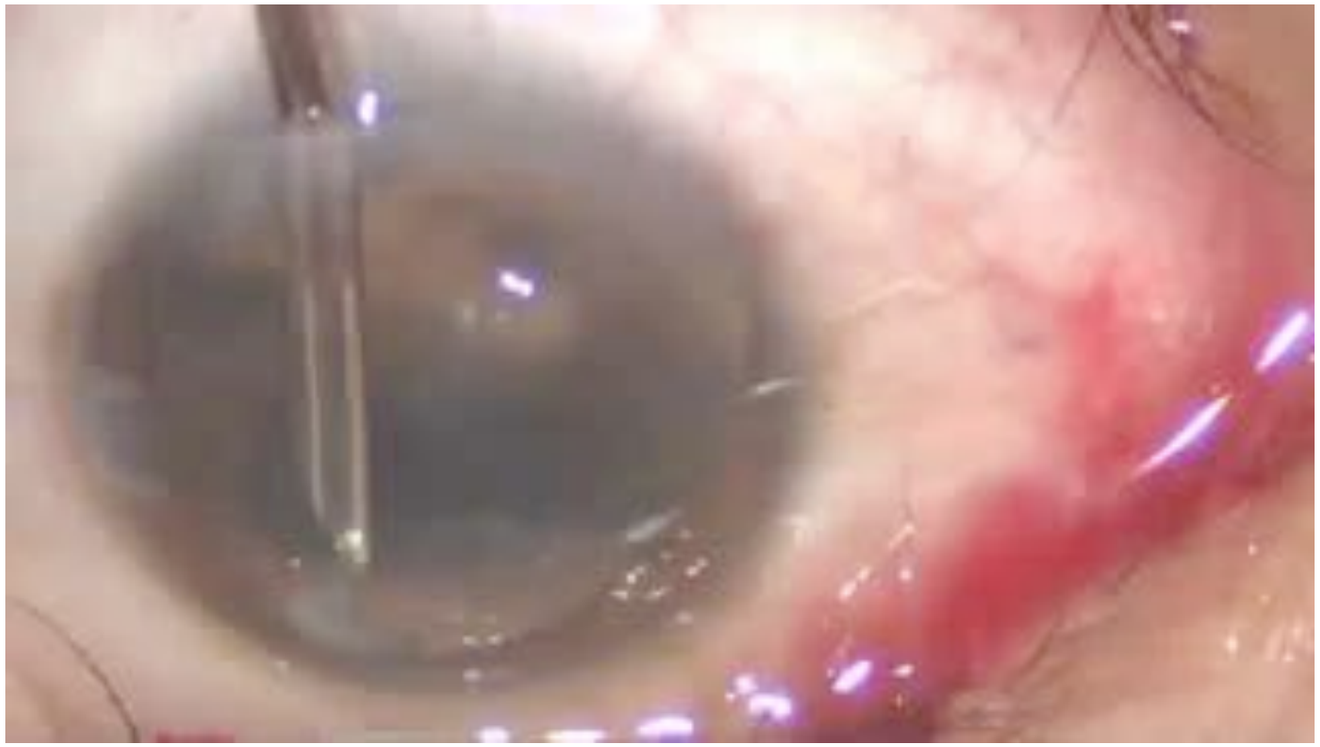

Why is this trainee experiencing difficulty aspirating this piece of lens material?

(Scroll down for the answer)

CHAPTER 12

Intraocular lens implantation

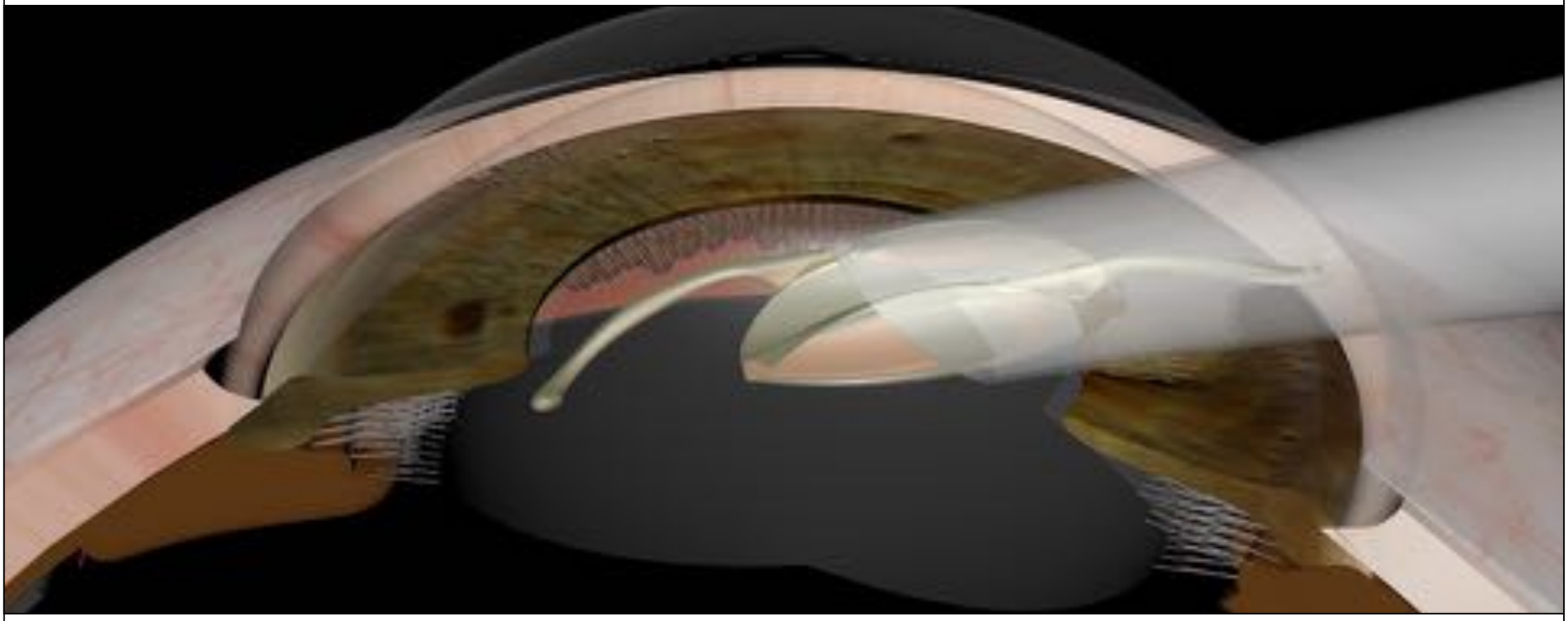

The enormous variety of intraocular lens design precludes a comprehensive review of this subject. This chapter will discuss the principles involved in injection of foldable intraocular lenses (IOLs).

Intraocular lens design

Figure 12.1 A very small sample of the myriad intraocular lenses available



From left: a 3 piece IOL with polypropylene haptics, an acrylic foldable IOL, a plate haptic IOL, a yellow acrylic IOL with a blue filter, an Oguchi lens with suture ringlets, a rigid anterior chamber IOL, a toric IOL with anti-vaulting loop haptics.

Design features of intraocular lenses have important implications for their clinical use.

Intraocular lens design

Intraocular lenses are composed of optics (the focussing element) and haptics (lightly sprung curvilinear extensions which maintain centration of the lens).

Illustration 12.1 The components of an intraocular lens

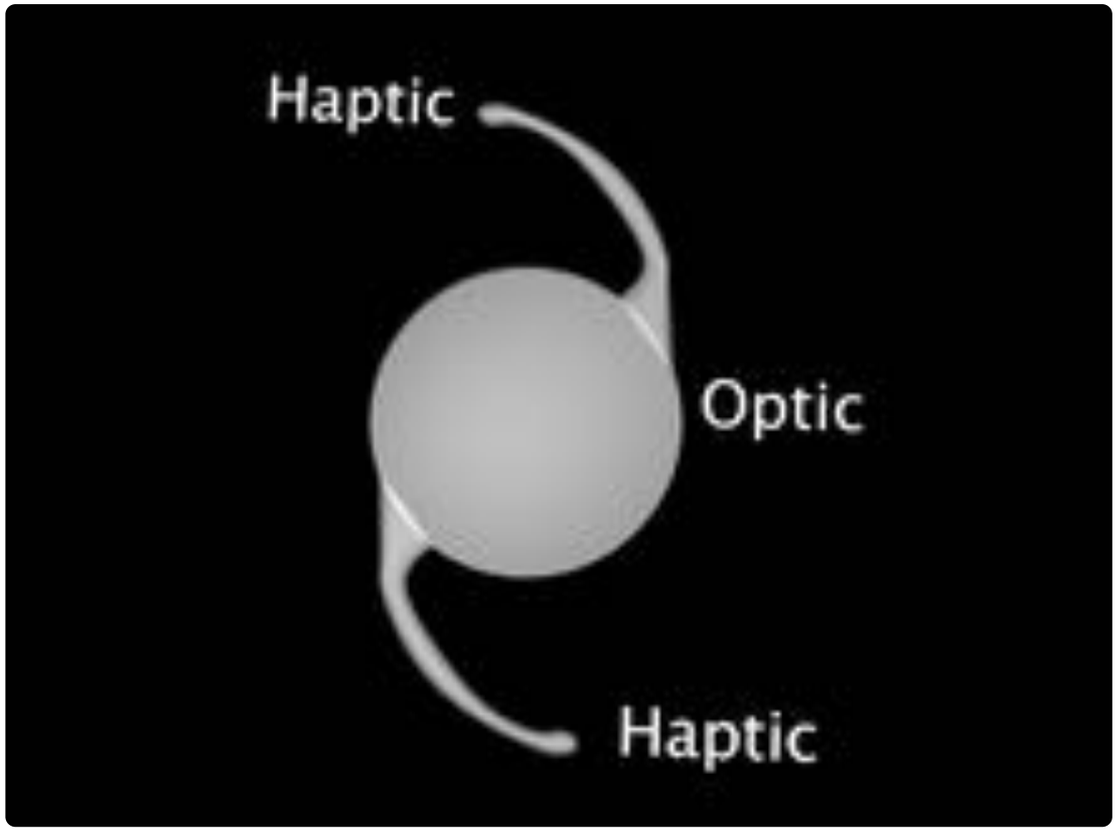

The haptics, unless damaged during insertion, maintain centration of the optic.

Illustration 12.2 One piece vs 3 piece design



The lens on the left is composed of a single piece of acrylic (in this case it has been dyed yellow to color filter low wavelength light which may be implicated in the pathogenesis of age related macular degeneration). The lens on the right has an optic composed of acrylic and 2 haptics composed of nylon - i.e. it is a 3-piece lens.

The square edge of the optic resists posterior capsule opacification as long as the edge of the capsulorhexis overlaps the anterior edge of the optic around its entire circumference.

The square edge may cause problems if the optic is placed in the sulcus. The edge may chafe on the iris as it expands and contracts. This may lead to:

- Iritis
- Glaucoma (as dispersed pigment from the iris blocks the trabecular meshwork).
- Bleeding from the iris

This combination is referred to as the UGH (Uveitis, Glaucoma, Hyphaema) Syndrome. The only single-piece acrylic IOLs that are licensed for implantation in the ciliary sulcus are low dioptre piggy-back lenses. Those licensed for implantation into the capsular bag are unsuited for use in the sulcus as they are too small (diameter), too thick and too sharp (the edges of the optic and haptics).

Illustration 12.3 Square edge optic

The square edge, when in contact with the capsular bag, inhibits lens epithelial cell migration. This reduces the incidence of posterior capsule opacification.

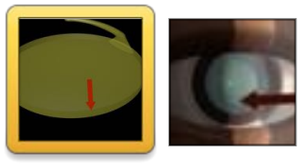

Intraocular lens design - angulation of the haptics

If the lens optic is biconvex and the haptics are not vaulted it does not make any difference optically which way round it is inserted.

Often however the optic is planoconvex or the haptics are vaulted, usually anteriorly so that the optic is pressed backwards against the posterior capsule. Implantation back to front alters the refractive power of the IOL.

The lens should be inserted so that the haptics make the shape of a Z rather than an S to achieve the correct location of the lens. The 'A' constant used in biometry assumes that this is the orientation used, and that the implant therefore lies in the capsular plane. Reversal of this orientation may lead to 'refractive surprise' as the optic lies in a different plane.

Illustration 12.4 Haptic vaulting

This is a 3 piece lens with 5^0 anteriorly vaulted haptics. (The cornea is to the left on this picture).

Illustration 12.5 Intraocular lens orientation



The haptics should make the shape of an Z not an S.

Intraocular lens injection

Figure 12.2 Viscoelastic injection

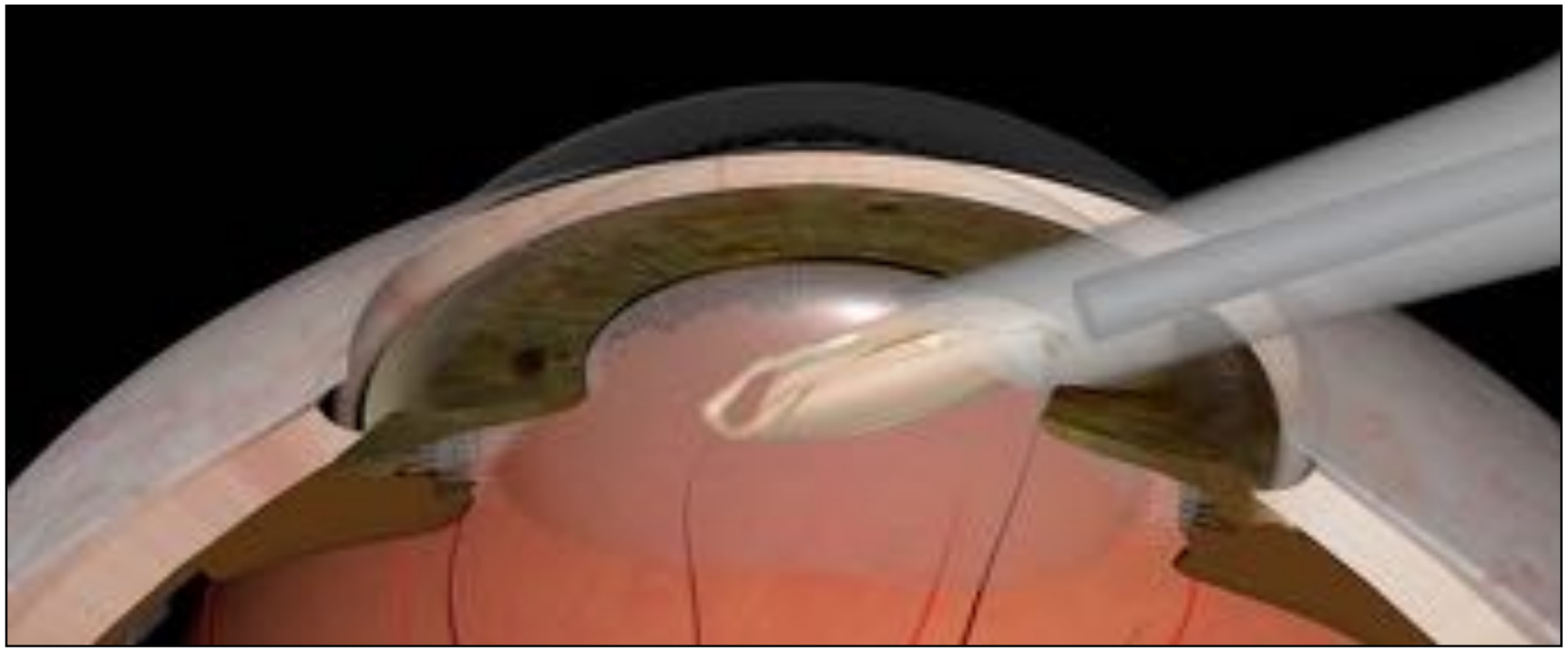

In order to prepare the eye for implantation viscoelastic is injected into the eye. The anterior chamber should not be overfilled - the aim is to inflate the capsular bag (to facilitate placement of the implant in the bag) and to place some viscoelastic over the subincisional iris (to prevent it catching on the implant).

Enlarging the incision

Modern injectors are designed to deliver the lens through the main incision without enlargement. If enlargement is required it is performed using sideways cuts with the edge of the keratome in order to retain the self-sealing architecture of the wound.

Injection of viscoelastic

In order to prepare the eye for implantation viscoelastic is injected into the eye. The anterior chamber should not be overfilled - the aim is to inflate the capsular bag. This facilitates placement of the leading haptic in the bag and reduces the chance of capsular tear.). Some viscoelastic is also injected over the sub-incisional iris (to push it back and prevent it catching on the implant).

Illustration 12.6 Injection of viscoelastic

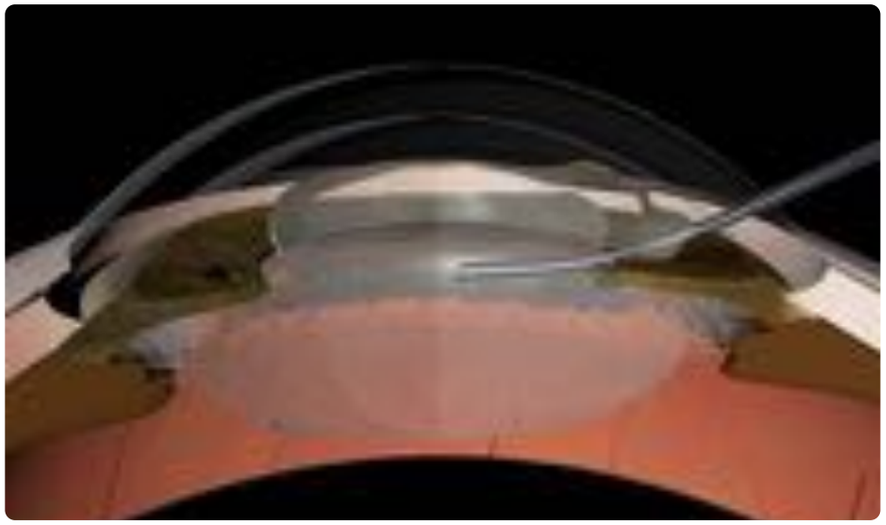

The capsular bag is inflated and there is a protective cushion under the incision over the iris.

Movie 12.1 Injection of viscoelastic

A wave is seen as the viscoelastic opens the capsular bag.

Preparation of the lens

Customized injection systems are available for each type of lens implant. They come with detailed instructions which must be followed to the letter. Failure to do so may lead to damage to the implant. A particularly common problem is damage to the trailing haptic, which is liable to get stuck between the plunger and the wall of the injection cartridge. The haptic can sometimes be released by slightly advancing the plunger. The traction deformation required for forcible disengagement may irreversibly damage the haptic.

Movie 12.2 Example video loading a lens into an injection cartridge

The manufacturers give very detailed instructions how to do this (for example how to press on the optic and fold the trailing haptic) - these should be followed closely.

Illustration 12.7 Poor lens preparation

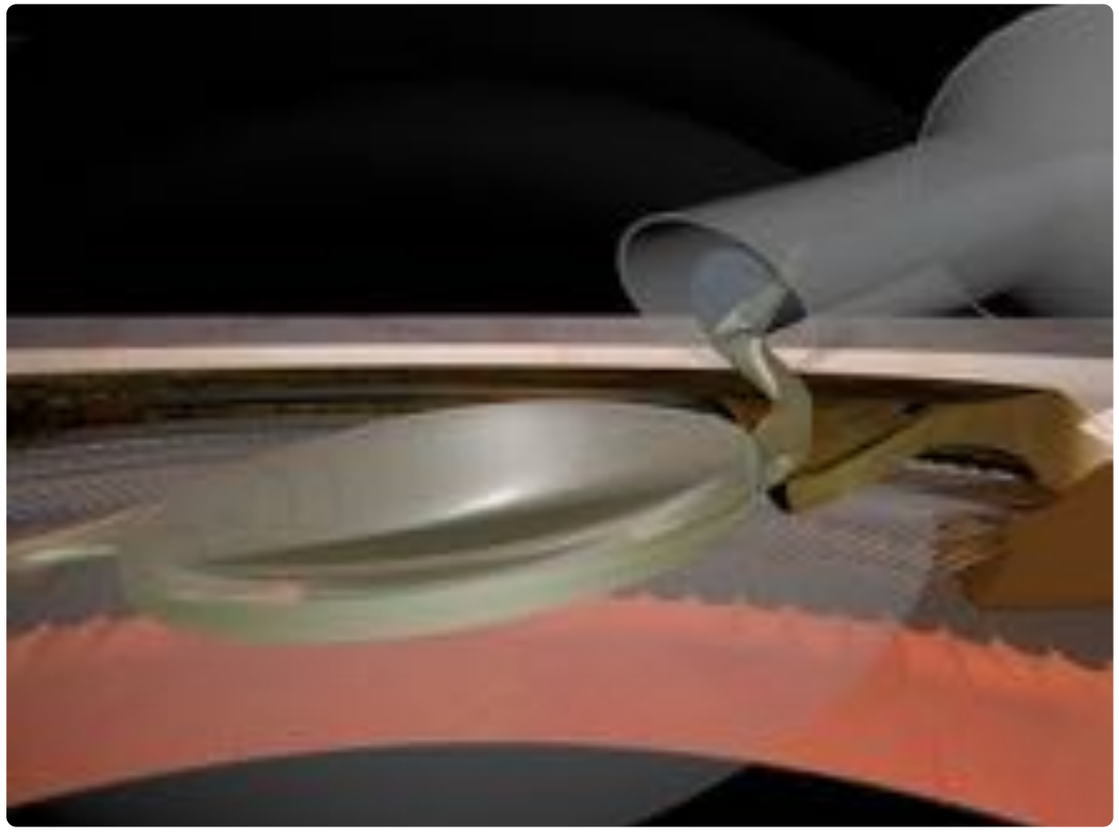

The trailing haptic has become jammed between the plunger and the wall of the injection cartridge. This is usually a result of failure to follow the manufacturers guidelines for mounting the implant in the cartridge.

Insertion of the cartridge into the eye

The injector is placed bevel down just posterior to the incision, pressed down slightly and advanced into the incision.

The globe usually needs to be stabilized when this is done, either by grasping the episclera with forceps or using an instrument in the side port in order to provide counter-traction. The roof of the incision tunnel should not be grasped as this is thin and may easily tear. Firm pressure is required to advance the tip of the injector into the tunnel. Simultaneous twisting back and forth can facilitate its entry. If the injector does not pass easily into the eye the incision should be slightly enlarged.

Movie 12.3 Insertion of the injector into the anterior chamber

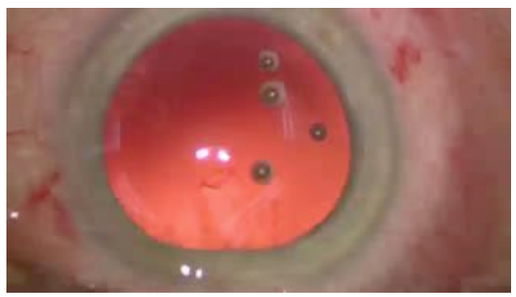

Movie 12.4 Insertion through a too-small incision

Difficulty inserting the injector through a small incision resulting in a small tear of Descemets membrane. Once slightly enlarged the injector is easily inserted.

Movie 12.5 Grasping the roof of the incision - tunnel roof tear

This should be avoided as it may tear the roof of the tunnel

Injection of the lens

One popular technique is to tilt the injector posteriorly and inject the leading haptic of the intraocular lens directly into the bag.

This leaves the trailing haptic outside the bag. Injectable lenses unfold slowly. The trailing haptic can usually be pushed into the capsular bag using pressure on the lens optic before the lens has fully unfolded. A second instrument or the plunger of the injection system may be used for this.

Movie 12.6 Injection of the leading haptic into the capsular bag

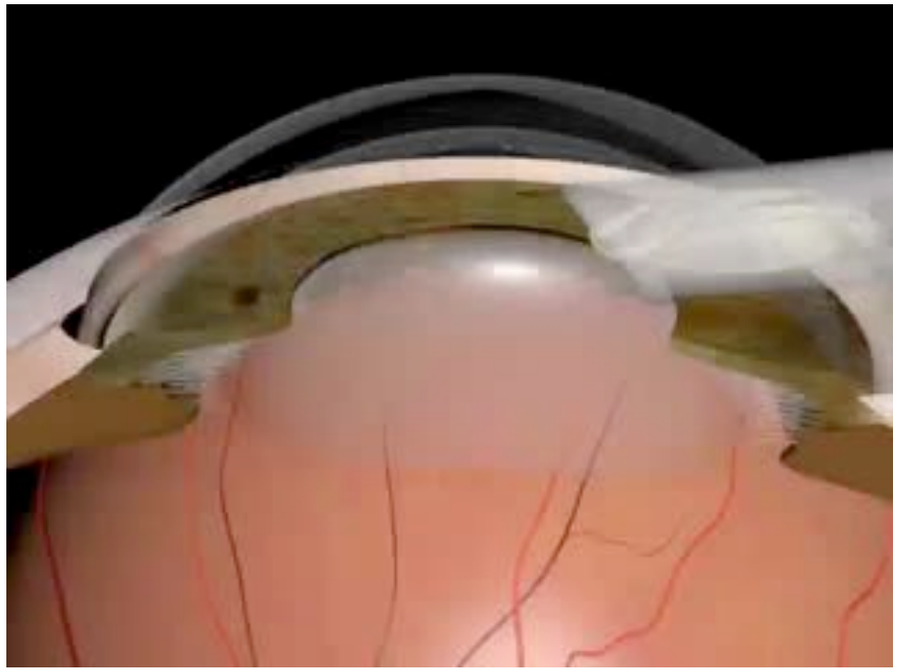

Note that the injector is tilted backwards to deliver the leading haptic into the capsular bag. The lens unfolds quite slowly and it would have been possible to push the optic posteriorly so that the whole lens lay in the bag.

Movie 12.7 Injection into the bag

The leading haptic can clearly be seen to pass under the edge of the anterior capsule. The trailing haptic is manipulated into the bag before it unfolds.

The trailing haptic (1)

The haptics of 3 piece lenses unfold quickly. It is not always possible to deliver them directly into the capsular bag.

If the lens unfolds with the trailing haptic outside the bag it may be dialed into position:

- Cohesive viscoelastic is injected anterior to the implant to push it backwards.
- The haptic/optic junction is engaged with a second instrument such as Sinskey hook
- The lens is rotated clockwise while gently pushing downwards until the capsular edge is seen to flip over the haptic. It is particularly important to see this happen to ensure the trailing haptic is inside the capsular bag.

Illustration 12.9 Second instruments

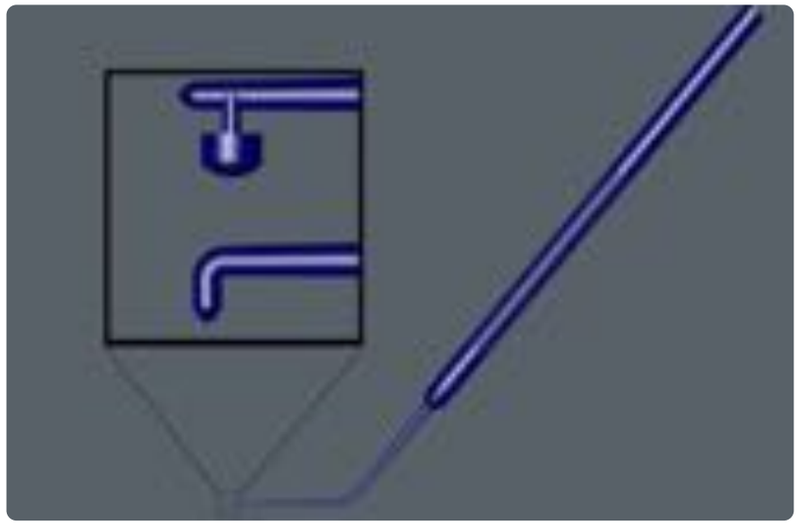

A variety of second instruments are available for dialing and manipulating the implant in the eye. The inset shows the tips of the Kuglen hook (top) and Sinskey hook (bottom).

Illustration 12.8 Dialing the implant

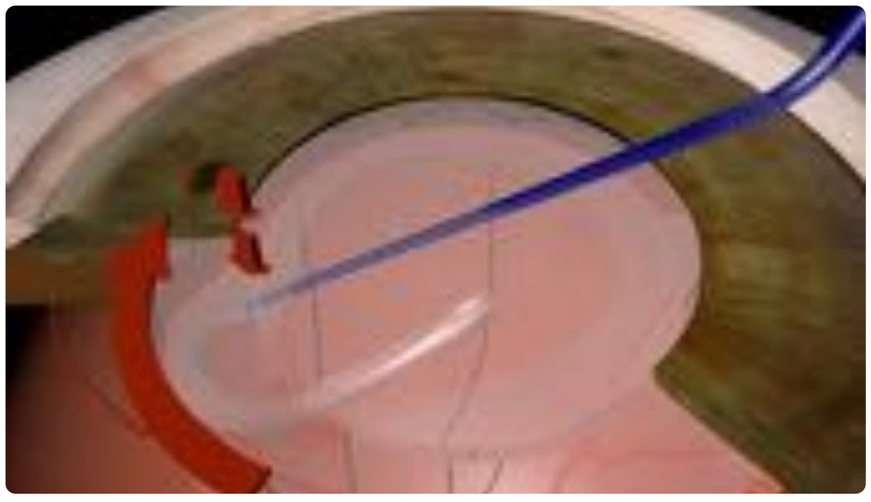

Note how the capsule flips up over the edge of the implant.

Movie 12.8 Dialling the trailing haptic into the bag

Note that the continuous circular profile of the capsulorhexis over the lens confirms that the haptic has been successfully placed in the capsular bag.

The trailing haptic (2)

If the trailing haptic is left outside the incision an alternative strategy may be employed to place it in the bag:

- The tip of the haptic is grasped by forceps.
- The haptic is flexed and pushed into the centre of the anterior chamber.
- The wrist is pronated (supinated if the left hand is being used). This flexes the shoulder of the haptic into the capsular bag.
- The haptic is released.

Illustration 12.10 Placing a trailing haptic in the capsular bag using forceps

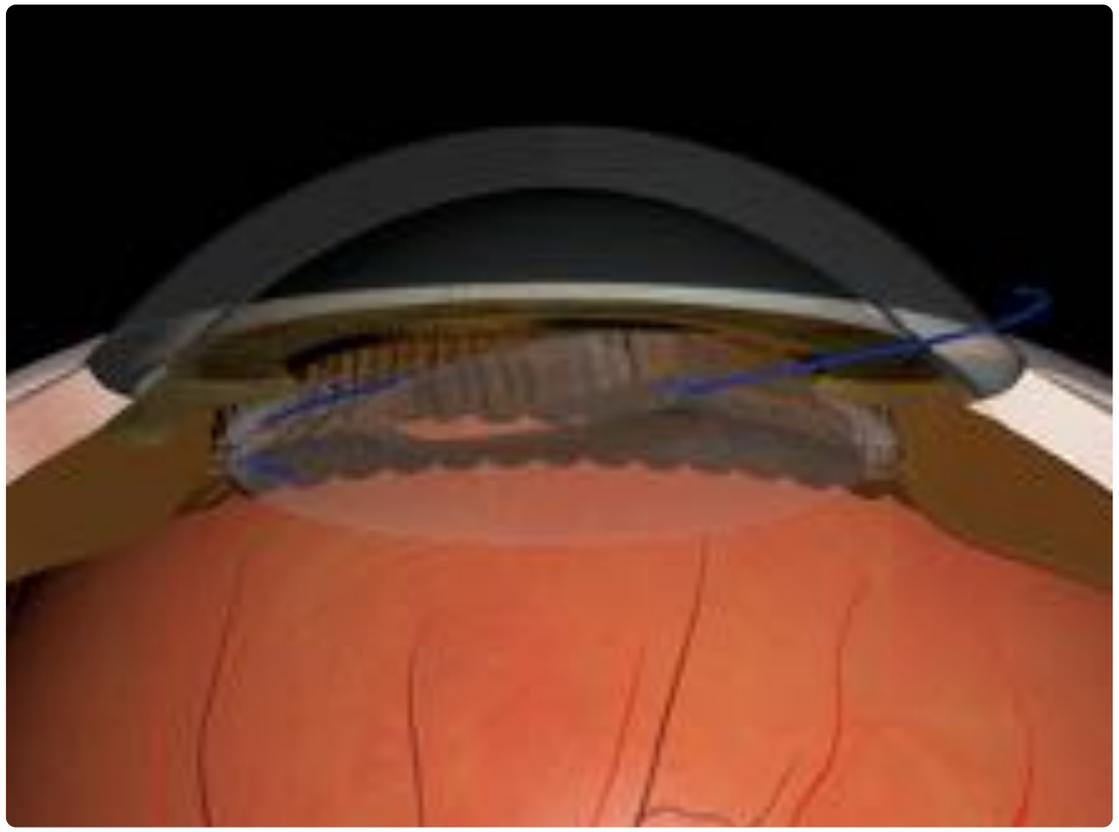

The optic and trailing haptic are outside the capsular bag

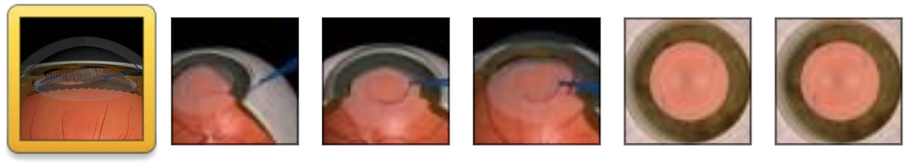

Implantation problems

Figure 12.3 Problems with the implant

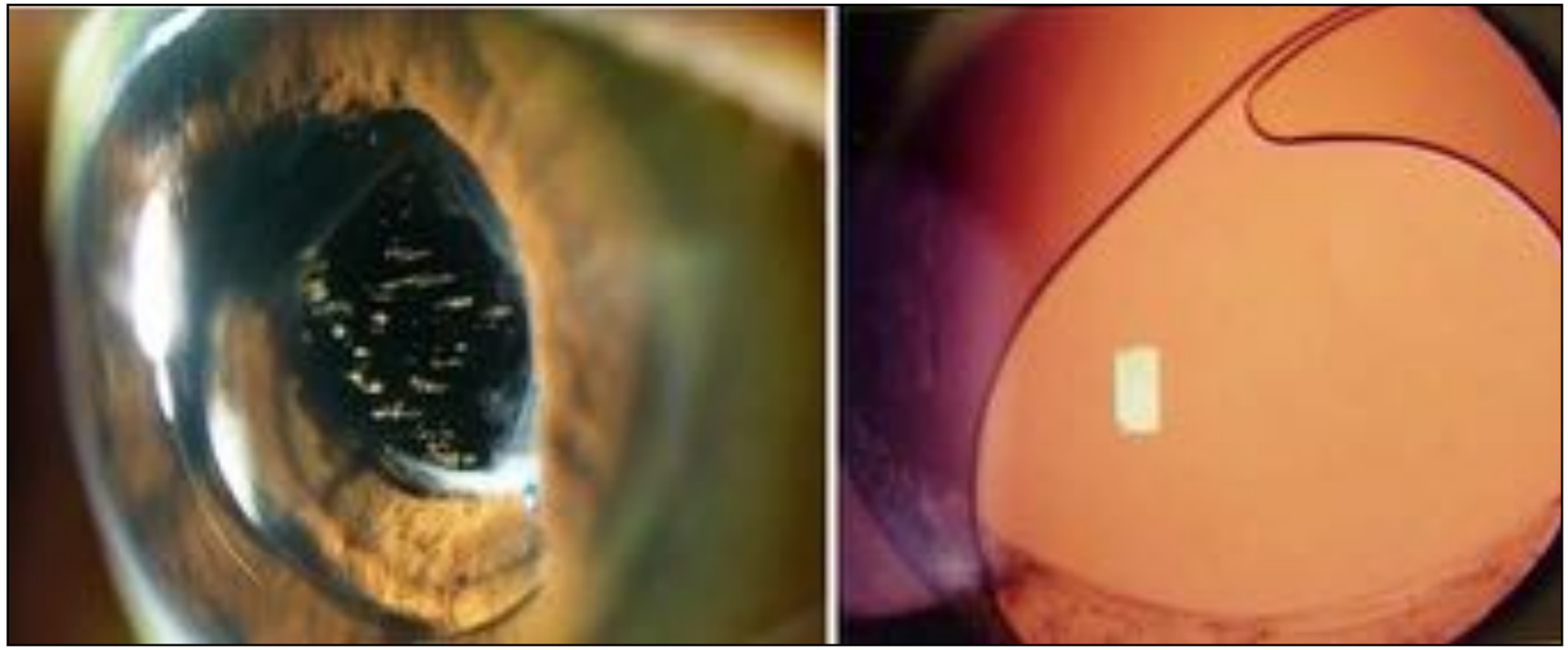

Many problems which manifest postoperatively are due to intraoperative errors.

Avoidable errors when implanting the intraocular lens include haptic damage due to poor loading technique, leaving one haptic in the sulcus and placing the IOL back to front.

Damage to the implant

The haptics may be deformed or broken if the implant has not been mounted in accordance with the manufacturers' instructions.

If the haptics are damaged the lens the implant must be removed and replaced.

Cutting the optic symmetrically in (almost) half allows the lens to be dialed out of an un-enlarged incision. This is referred to as the "Packman" technique after the figures in the early electronic game of that name.

However, using this technique it can be difficult to control the movement of the second half of the lens as the first half is being removed, leading to some acrobatics and engagement of the iris or damage to the endothelium.

To avoid this just bisect the optic completely and remove the two halves of the IOL separately.

Movie 12.9 Cutting and removal of a foldable lens implant

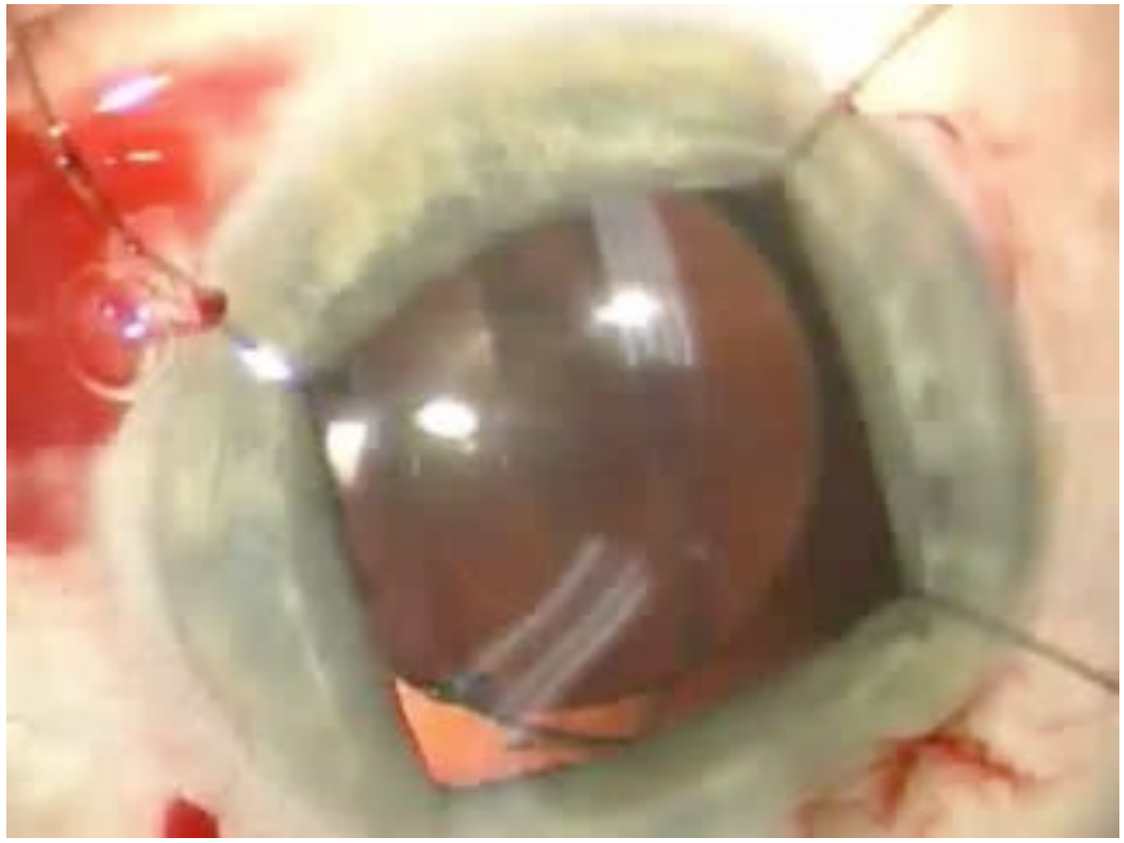

Non serrated scissors repel the lens, which must be stabilized using a second instrument. Serrated scissors (such as the Osher scissors) grip the lens and can be used with one hand.

Implant in the sulcus

Intraocular lenses with adequate diameter haptics and non-square edges may be implanted in the sulcus. Generally these are rigid non injectable lenses made of polymethylmethacrylate (perspex).

If an injectable lens that was explicitly designed for endocapsular implantation is placed into the sulcus, this may lead to:

- Implant mobility and decentration (as the overall diameter is less than the sulcus).
- Chafing on the iris giving rise to uveitis,glaucoma and hyphema (UGH syndrome).
- Myopic shift of about 1 dioptre as the implant is sitting more anteriorly.

If a square edged optic must be implanted in the sulcus an optic capture technique may be used. This avoids the problems listed above. It is generally easier to achieve with a 3 piece lens because of the narrow haptics and more acute angles at the optic/haptic junction which prevent the capsulorhexis slipping over the shoulder of the junction.

Movie 12.10 Optic capture of a sulcus placed intraocular lens

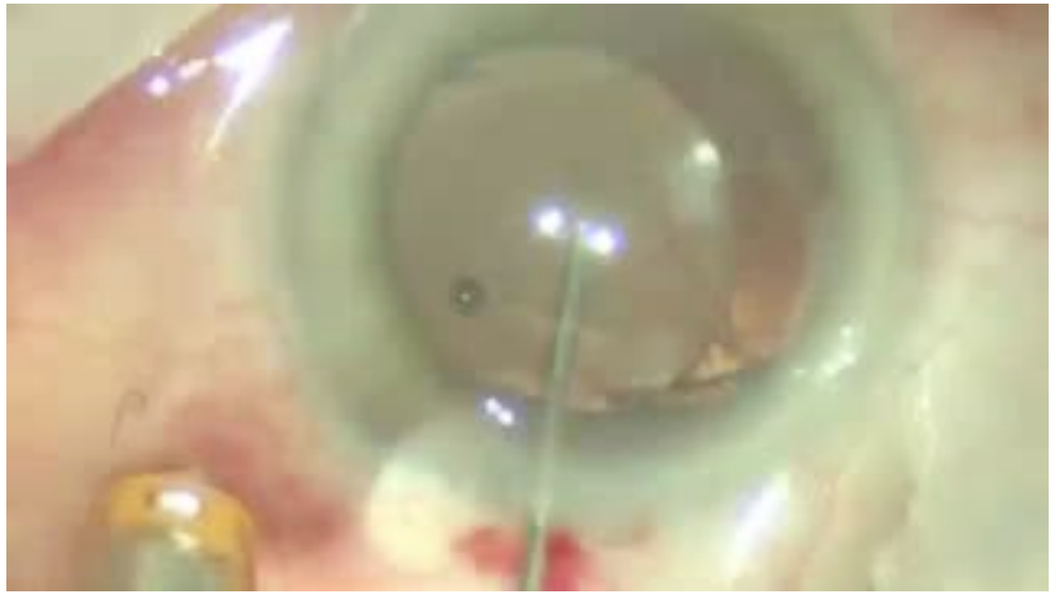

A rocking motion while pressing posteriorly pushes each lip in turn of the optic behind the edge of the capsulorhexis. The capsulorhexis adopts a "cats' eye", shape conforming successful optic capture.

Single haptic in the sulcus

Placement of a single haptic in the sulcus usually leads to post operative decentration. This is due to the asymmetric forces placed on the implant when the capsular bag contracts.

To avoid this both haptics must be seen to pass under the capsulorhexis rim.

The signs that a single haptic is in the sulcus are:

- The capsulorhexis is no longer round.
- The implant does not rotate freely.

Illustration 12.11 One haptic in the sulcus

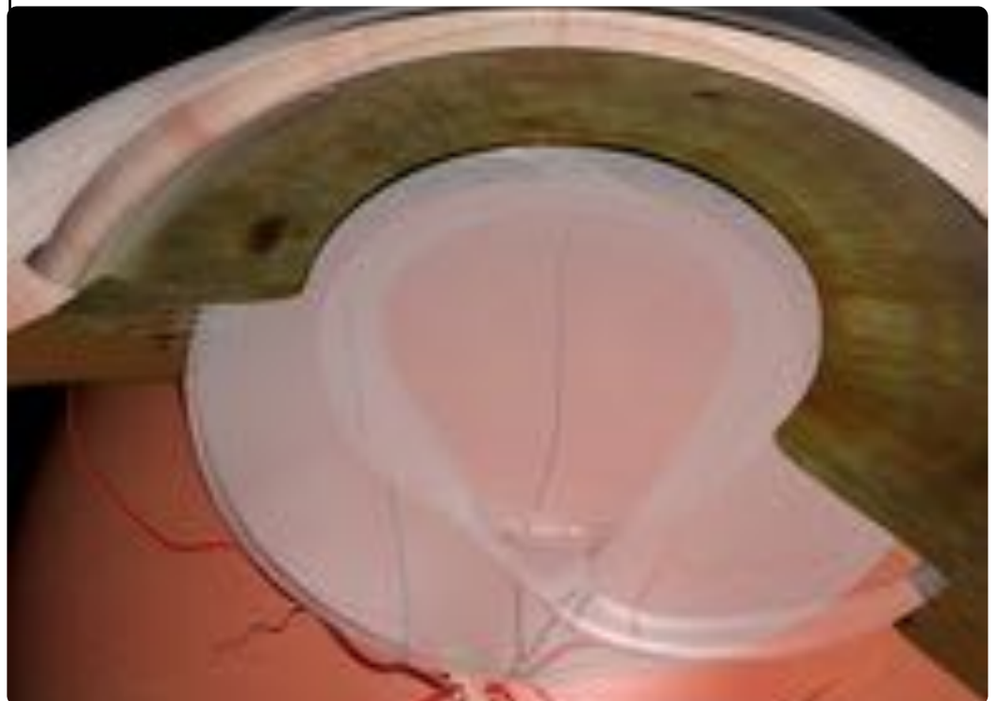

This will cause the intraocular lens to sublux unless dealt with at the time of surgery.

Movie 12.11 IOL haptic in the sulcus

The IOL is difficult to rotate because one haptic is in the bag and one in the sulcus. It is reposited using a second instrument by pushing posteriorly and rotating. Following this the capsulorhexis can be seen to resume its circular shape (black arrow).

Inverted intraocular lens

The intraocular lens must have the correct anteroposterior orientation.

A lens which is back to front may be flipped bimanually using two second instruments. Viscoelastic should be injected first to create space in the anterior chamber for the maneuver and to protect the corneal endothelium.

Movie 12.12 Inverted intraocular lens

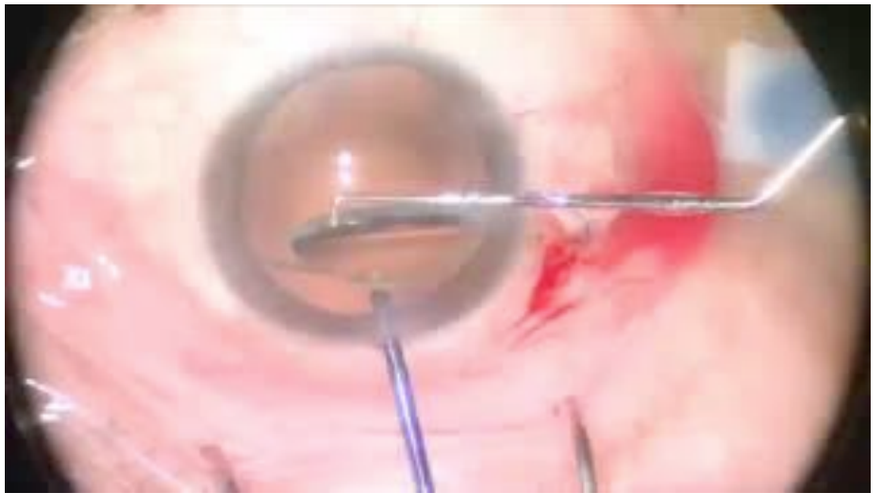

Viscoelastic has been injected. Note how the trailing haptic impedes the reorientation until it too has been reorientated.

Knowledge review

Review 12.1 IOL orientation

Which implant is correctly orientated?

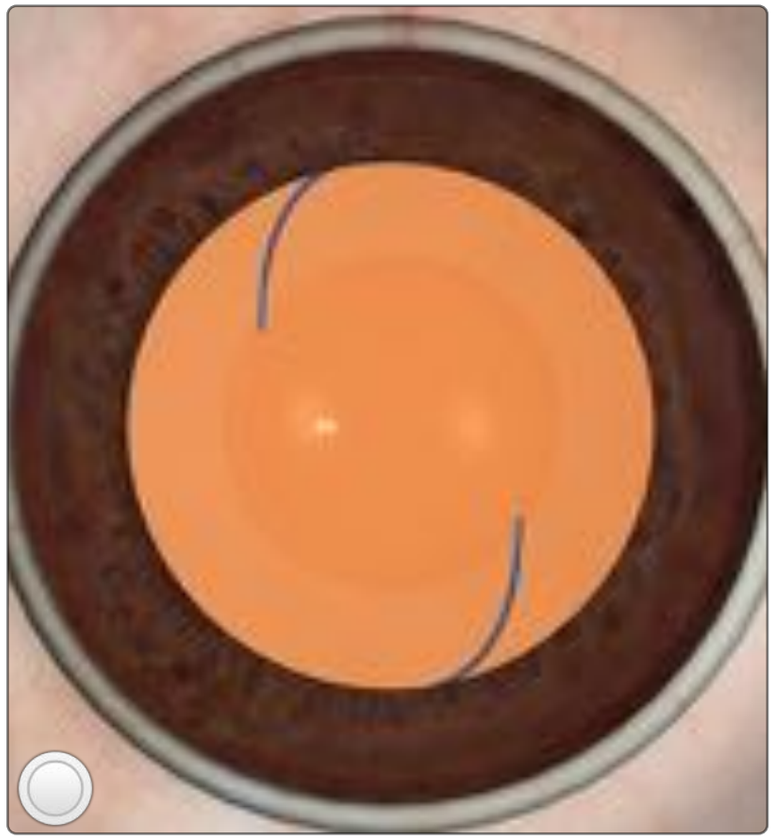

Check Answer

Movie 12.13 Clinical video 1

What error does this video show?

Why does it happen?

What are the possible consequences?

What should be done about it?

(Scroll down for the answers)

Review 12.2 Peaking of the capsulorhexis

What is the implication of the peaking of the capsulorhexis shown here?

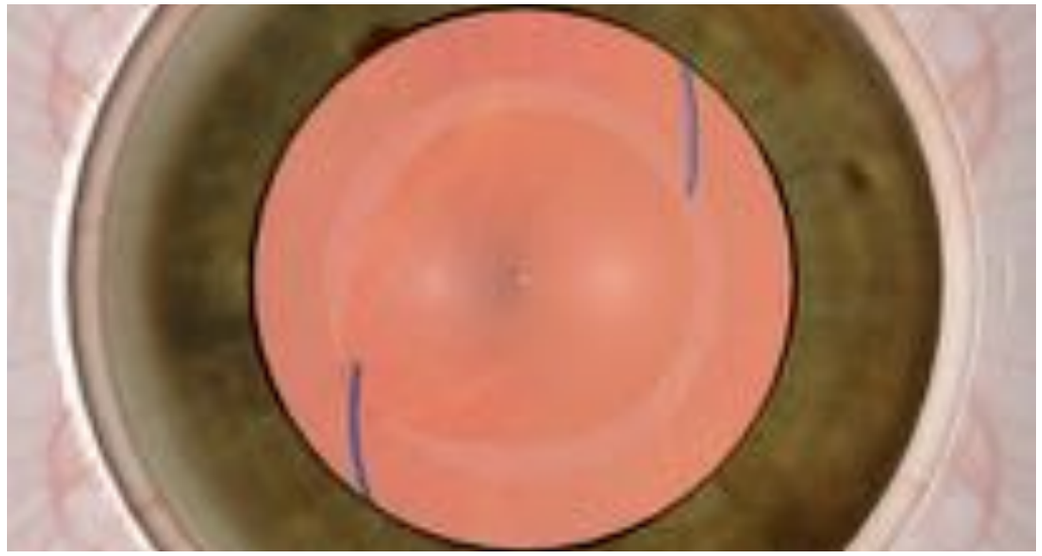

- **A.** Both haptics are in the capsular bag
- **B.** Both haptics are in the ciliary sulcus
- ✓ **C.** One haptic is in the ciliary sulcus

Check Answer

CHAPTER 13

Intraocular lens selection

The techniques of modern biometry and keratometry allow very accurate determination of the intraocular lens power required to meet the desired post operative refraction ("target" refraction). Increasingly this involves the use of toric and multifocal intraocular lenses. In this basic book the use of standard monofocal lenses only will be described.

Keratometry

Figure 13.1 The importance of the cornea in refraction

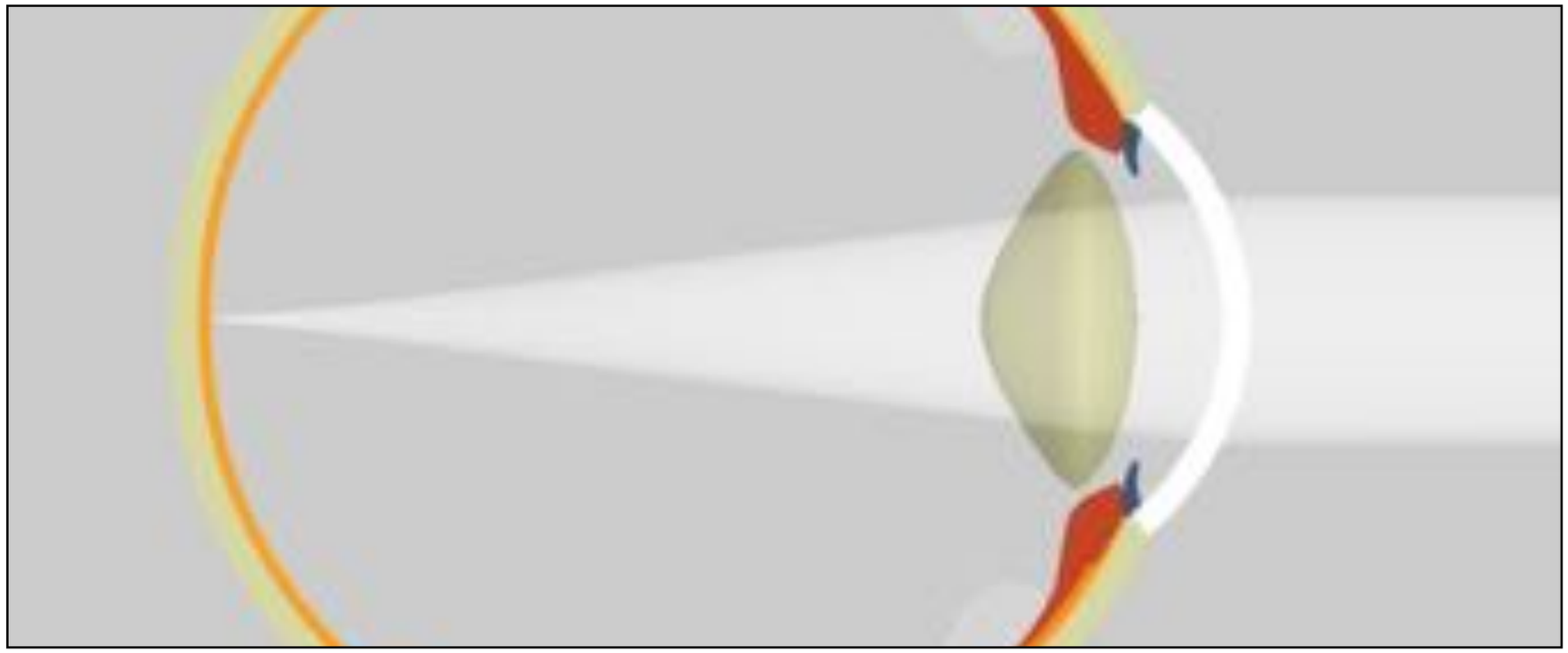

Notice that most of the beam focussing occurs as it passes through the cornea

The corneal radius of curvature is a major determinant of the focal power of the eye.

It may be measured by manual keratometry, corneal topography and automated keratometry.

Most modern optical biometry systems have integrated automated keratometry functions.

Whichever method of keratometry is used contact lenses should be left out before measurement.

Specular reflexes

The term speculum means mirror.

The tear film on the corneal surface reflects a tiny proportion of incident light.

Analysis of these reflections is the basis of keratometry. In terms of Gaussian optics, the cornea acts as a convex mirror.

Illustration 13.1 Specular reflections

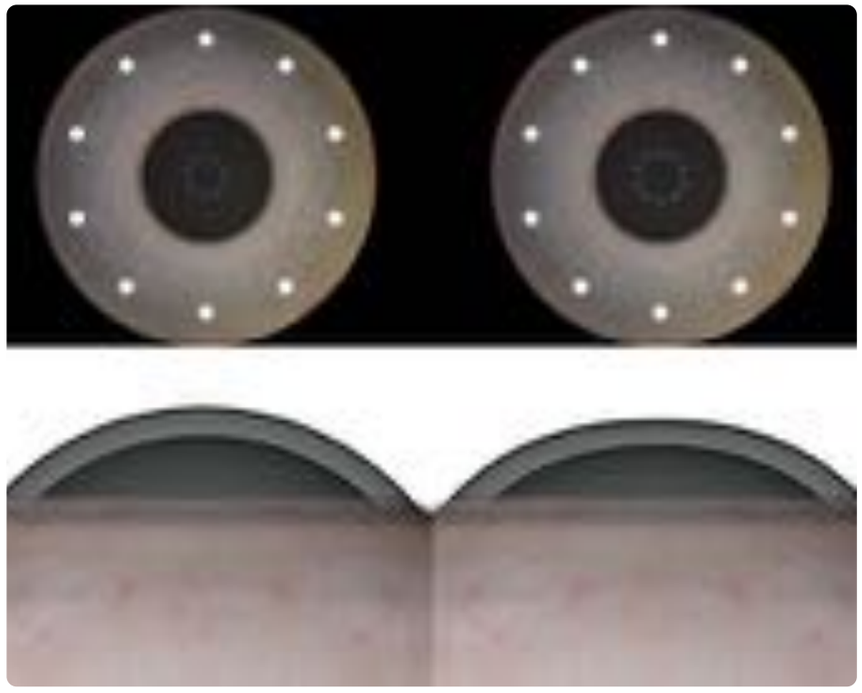

The array of lights produces a ring of specular reflections. The cornea on the right is more flattened centrally so the ring appears larger.

Illustration 13.2 Effect of malalignment



A ring is only produced if the visual axis is correctly aligned (the eye is fixated on the center of the array of lights). In this case the eye is not looking at the centre of the array.

Manual keratometers

The general principles of manual keratometry are illustrated with reference to the Javal-Schiotz keratometer. This section may be more intelligible after reading the section on astigmatism.

Interactive 13.1 The Javal-Schiotz keratometer.

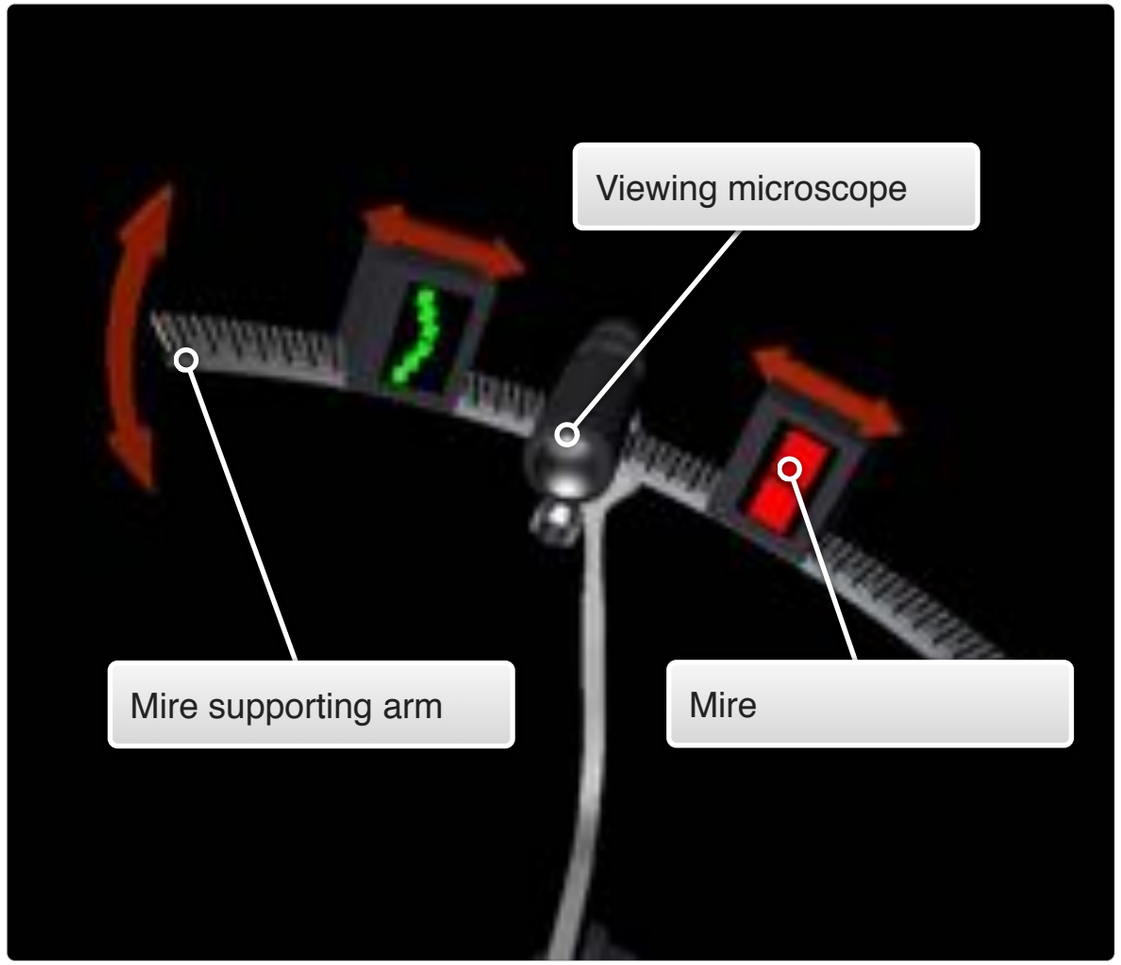

Illustration 13.3 Using the Javal-Schiotz keratometer

The operator views the images of the mires through the microscope and manipulates them to achieve the correct alignment.

Automated keratometry

Many optical biometry machines have incorporated automated keratometers. The image formed by reflection of an array of light emitting diodes is used to determine the refractive power of the cornea.

Illustration 13.4 Automated keratometry.

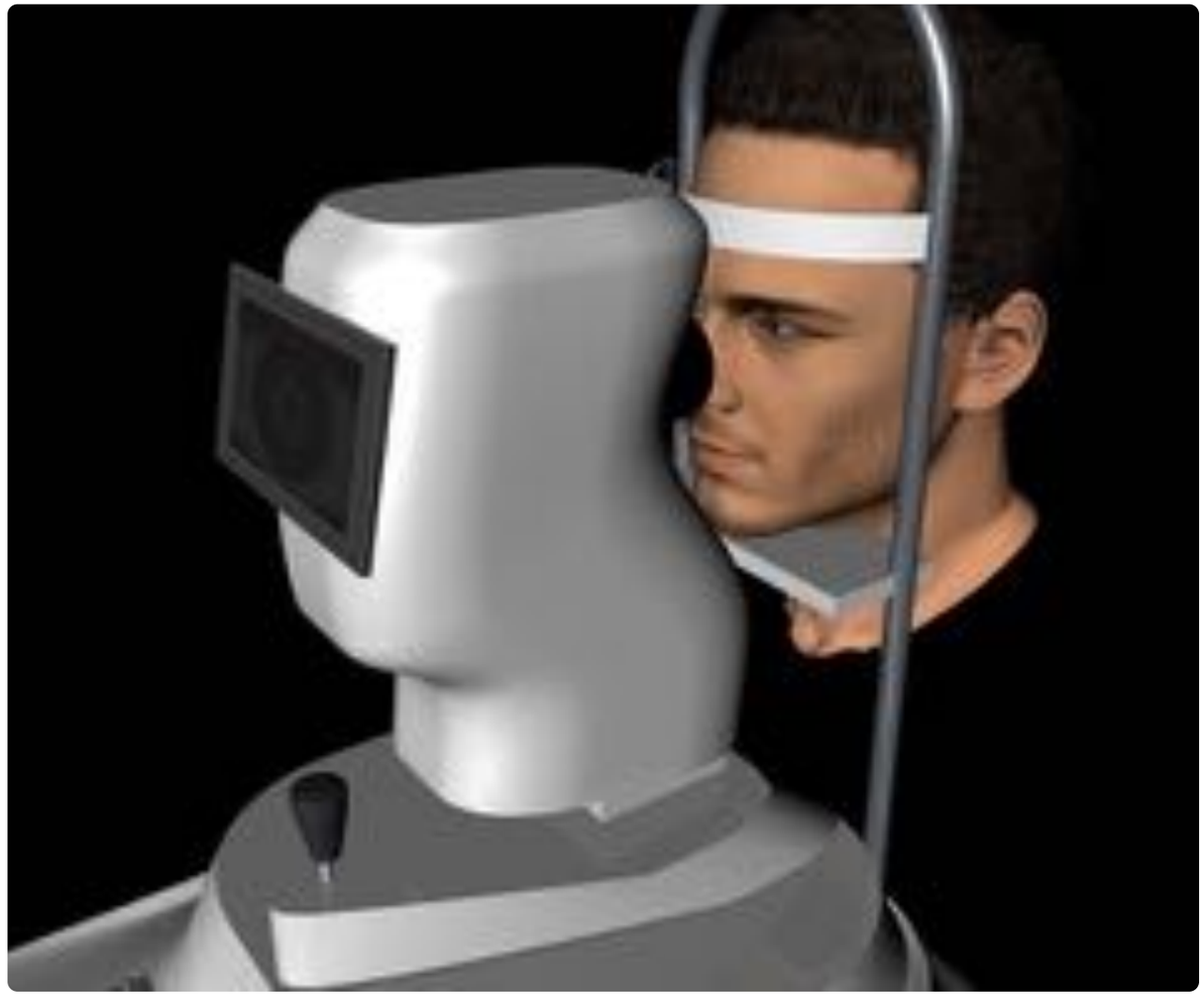

An optical biometry machine with incorporated keratometer.

Biometry

Figure 13.2 Ultrasound biometry of an emmetropic eye

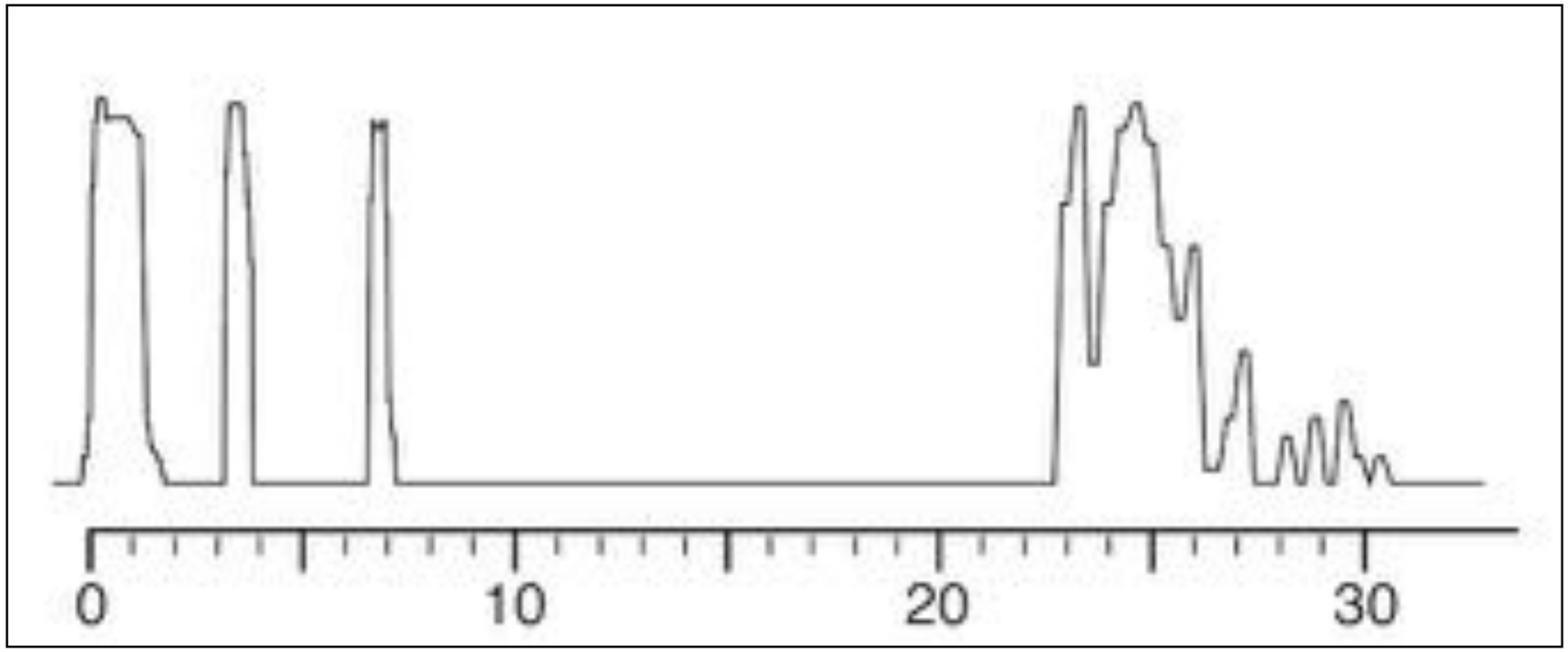

The refraction of the pseudophakic eye is determined by its' length and the position of the intraocular lens. The first lens power calculation formulas used the axial length only. The position of the intraocular lens was derived from the axial length making a number of assumptions. More modern formulae require measurement of the anterior chamber depth as well as the length of the eye. The position of the intraocular lens can be more accurately determined, increasing precision of the measurements.

Ultrasound biometry: general principles

Ultrasound biometry uses the piezoelectric phenomenon. Its' main advantage is the ability to penetrate visually opaque media.

Pulses of ultrasound produced by the transducer are reflected at interfaces with differing sonic conduction speed (for example between the posterior lens capsule and the vitreous). These reflected waves are detected by the transducer and converted to electrical energy. Just as energy may be transduced into sound, the piezoelectric effect allows sound to be converted to energy. Plotting this signal (on the y axis) against time (on the x axis) gives a trace which indicates the distance of the ocular structures from the transducer tip.

The accuracy of any form of ultrasound biometry is limited by the wavelength of ultrasound.

Ultrasound is ineffective if there is an air pocket between the transducer and the cornea, as the very high signal from the air/cornea interface drowns out all the other signals to the transducer. This problem may be solved in several ways.

Movie 13.1 The principles of ultrasound biometry

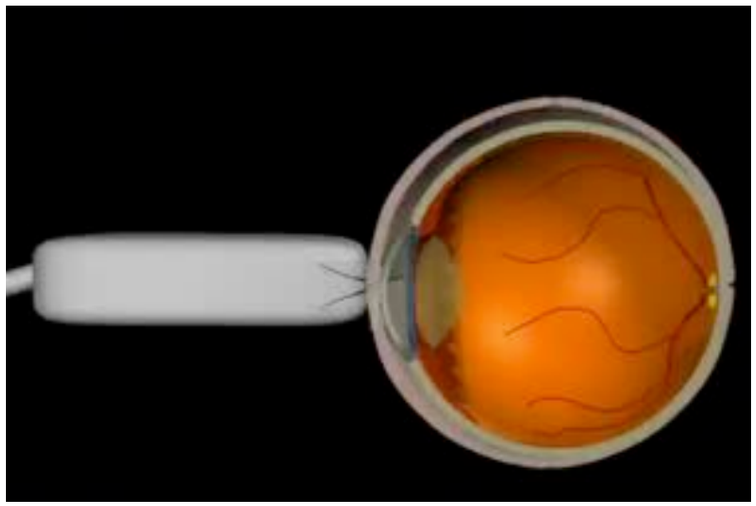

The time the sonic wave takes to return to the transducer depends on the distance of the reflective interface from the transducer.

Illustration 13.5 Ocular structures on axial scan

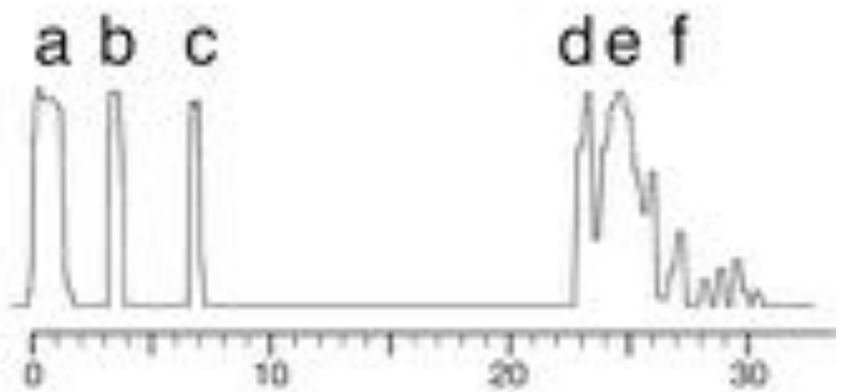

An 'A scan' produced by plotting signal amplitude (y axis) against time (x axis). The machine converts time into distance by allowing for the velocity of conduction in different media.

The signals produced by sonic interfaces are:

a = cornea b = anterior lens capsule c= posterior lens capsule d = retina e = sclera f = orbital fat

A scan biometry

"A scan" (A = axial) biometry analyzes the reflected sound waves in a single axis. It may be performed by applanation or immersion.

Although most axial length measurements are now mostly performed using optical biometry immersion biometry is still sometimes used in eyes in eyes with opaque media (although B scan biometry has many advantages in this situation).

Applanation. The transducer touches the cornea. The direct contact between the transducer probe and the cornea removes the air pocket. The corneal indentation slightly alters the axial length. As a result of the induced errors this technique is no longer widely used.

Immersion. A pocket of saline is placed between the transducer probe and the cornea. There are many ways of doing this. In the past the patient was asked to lie recumbent while a tube filled with saline was placed on the cornea. Some modern devices use a silicone sleeve which fits securely around the transducer tip. When this is filled with

Illustration 13.6 Immersion biometry

A shell connected to an infusion is applied to the cornea. The infusion fills the well above the level of the transducer tip so that there is no air interface between the transducer and the cornea.

B scan biometry

A scan biometry detects and analyzes reflections in **one** dimension, producing a graph of time vs amplitude. B scanning (B = brightness) detects and analyzes reflections in **two** dimensions using lateral excursions of the ultrasound beam. This produces an image of a small horizontal slice of the eye.

Simultaneous A and B scanning allows the observer to determine the axis at which the A scan is being performed in relation to other structures in the eye such as posterior staphylomas. Alternatively markers are manually placed on the scans from which the axial length is determined.

Optical biometry

The major advantages of optical biometry are:

- No contact with the eye is required, avoiding errors due to corneal distortion.
- The technique is easy to perform and seems to be less 'operator dependent' than ultrasound biometry.
- The very short wavelength of the light greatly increases the axial resolution.
- Use of a single machine for keratometry and biometry.

Because light travels so quickly it is not possible to measure the time elapsed between generation of the pulse and the echo, as is done with ultrasound. The signal is therefore analyzed using interferometry.

Two types of optical biometry machine are available. The IOLMaster (*Carl Zeiss, Jena*) uses partial coherence tomography. The LenStar (*Haag Streit, Koeniz*) uses optical low coherence reflectometry. At the time of writing there is no clear consensus which machine is better. The rate of development and incorporation of new technologies in both machines has been very rapid.

Illustration 13.7 Optical interferometry (simplified).

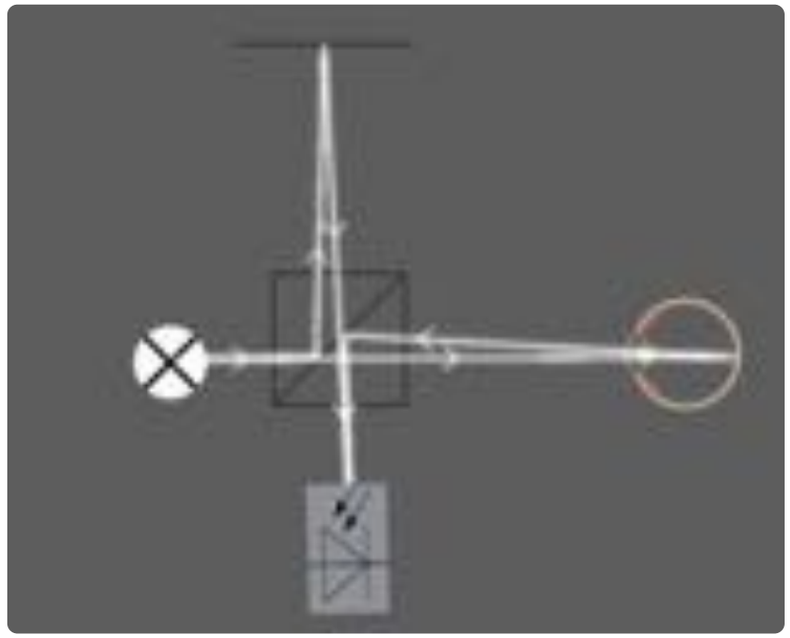

The central beam splitter splits the beam from the light on the left. One beam (the reference beam) passes upwards and is reflected in the mirror at the top before passing down into the photodetector at the bottom of the image. The other beam (the sampling beam) passes into the eye and is reflected back via the beam splitter to the photodetector. The optical measurements are derived from interference between these 2 beams.

Biometry outputs

Some examples of signal traces are given here using an IOLMaster. Those produced by the Lenstar differ and more closely resemble immersion biometry A scans.

The next page is an interactive guide to the principles of interpreting the measurement sheets. These sheets vary widely. Every trainee should become familiar with the one in regular use in their department.

Illustration 13.8 IOLMaster signals

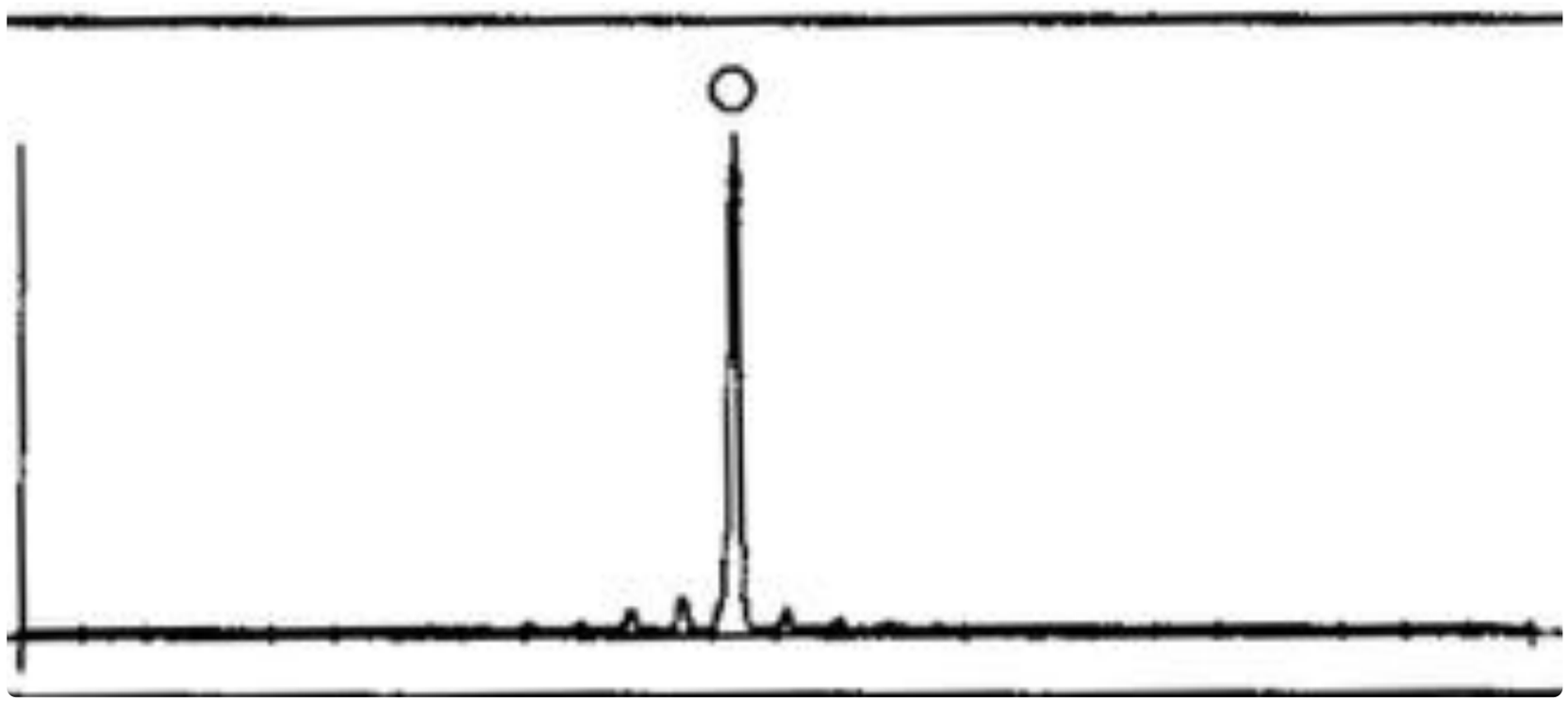

This is a good quality scan. The circle above the retinal peak indicates the measurement point used by the machine in determining the axial length. The small spikes are artifacts called secondary maxima. Note that they are placed symmetrically around the primary maximum signal.

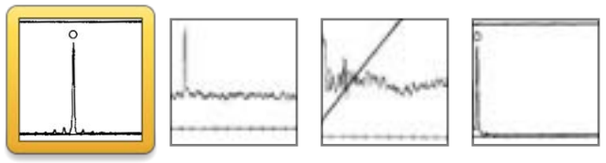

Interactive 13.2 IOLMaster measurement sheet example

Interactive 13.3 The IOLMaster calculation sheet

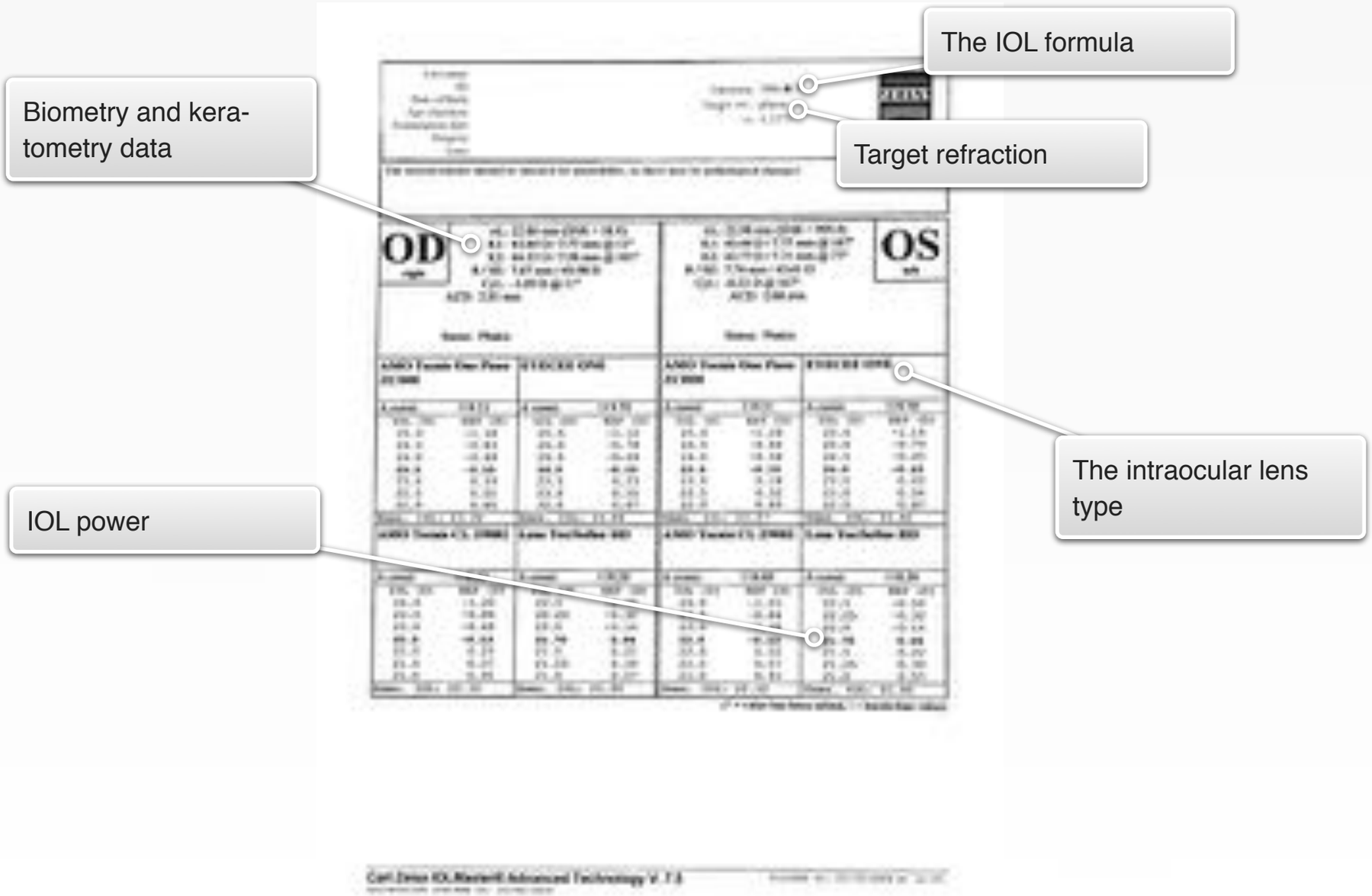

Selection of an intraocular lens

The first step in choosing an intraocular lens is a careful assessment of the patients' current refraction, past refractive history (especially laser refractive surgery and contact lens usage) followed by a discussion with the patient regrading the desired refractive outcome.

Some general principles governing the choice of a monofocal intraocular lens are:

- A postoperative refraction of 0 diopters will allow the patient to be spectacle independent for distance vision but require reading glasses.
- A postoperative refraction of -2.5 diopters will allow the patient to be spectacle independent for near at 40cm but require distance glasses.*
- Patients may not tolerate postoperative anisometropia greater than 2.5 -3.00 diopters without contact lenses.
- A refraction of -2.5 in one eye and 0 in the fellow eye will in theory allow the patient to become spectacle independent by using one eye for near work and one eye for distance (monovision). However patients vary in their tolerance of anisometropia (asymmetric refraction) due to the resulting aneisokonia (asymmetric image size with spectacle correction). In practice many surgeons are more conservative, aiming for -1.5 in the reading eye and -0.5 in the distance eye ("micro"or mini" monovision). Tolerance for greater degrees of monovision may be assessed from the patients refractive history or by a preoperative trial of contact lens.
- Myopic patients dislike being left hypermetropic.
- The use of multifocal intraocular lenses is beyond the scope of this basic textbook.

* the optical power, measured in diopters, is the reciprocal of the focal length measured in meters. The reciprocal of -2.5 is -0.4m which is 40 cm.

Management of preoperative astigmatism - understanding the spherical equivalent

The spherical equivalent is an important concept in determining the desired post operative refraction in astigmatic patients.

It is determined by adding the half of the cylindrical power of the corrective lens to its' spherical power.

A patient wears a prescription of +2/+1.5 at 180^0. The spherical equivalent is +2 + 1.5/2 = +2.75.

A patient wears a prescription of -3/+2.5 at 90^0. The spherical equivalent is -3 + 2.5/2 = -1.75.

Spherical equivalence exercise.

A patient wears a prescription of -3/-1.5 at 90^0.

What is the spherical equivalent?

Scroll down for the answer.

Management of preoperative astigmatism (ctd).

There are a number of strategies for reducing astigmatism.

- 'On meridian' surgery uses the surgically induced astigmatism of an incision to reduce pre-existing astigmatism. Modern phacoemulsification incisions induce very little astigmatism however.
- Limbal relaxing incisions (LRIs) may be made during surgery. Their effect can be a little unpredictable and significant residual postoperative astigmatism is frequently seen. The use of a femtosecond laser may increase the accuracy of LRIs.
- Toric intraocular lenses are are spherocylindrical lenses that are aligned to the axis of astigmatism using visible markers on the lens. Correct alignment depends on preoperative placement of accurate reference marks on the eye.
- The alignment should be carefully checked at the end of surgery, after complete removal of viscoelastic, as misalignment significantly reduces their effectiveness (every 1 degree of misalignment reduces the power of the cylinder by 3.3%, therefore misalignment by only one clock hour (30 degrees) entirely negates the cylindrical power of the toric IOL).

Illustration 13.9 A toric intraocular lens

Note the alignment marks on the optic.

IOL power calculation formulas

The only ocular parameters required in the earliest formulas were keratometry and axial length. These formulas made assumptions about other parameters or extrapolated them from the axial length. The drive to increased refractive precision has increased the number of parameters which are measured directly.

The A constant is a variable specific to the intraocular lens to take account of variations in measurement and surgical technique. The A constant must be altered (optimized) according to the biometry technique.

It is possible to personalize the A constant if audit of an individual surgeons' refractive outcomes reveals a consistent discrepancy with the expected outcomes. This may be less critical now due to:

- Widespread use of optical biometry (which has low inter-observer variability).
- Consensus on optimal capsulorhexis size (which affects the intraocular lens position).

FORMULA	YEAR	BIOMETRIC MEASUREMENTS	NUMBER OF "A" CONSTANTS
Holladay 1	1988	Axial length, keratometry	1
SRK/T	1990	Axial length, keratometry	1
Hoffer Q	1993	Axial length, keratometry	1
Haigis	2000	Axial length, keratometry, anterior chamber depth	3 (varies with axial length)
Olsen	2006	Axial length, keratometry, anterior chamber depth, refraction, lens thickness	1
Holladay 2	2006	Axial length, keratometry, anterior chamber depth, refraction, lens thickness, patient age, horizontal corneal diameter	1

Knowledge review

Review 13.1 Contact lens wear

While performing keratometry it transpires that a patient wore a hard contact lens the day before. The patient is desperate for surgery as quickly as possible. Which answer is correct?

- **A.** The measurements are made normally.
- **B.** The measurements are made but a special corrective factor must be applied to obtain accurate keratometry.
- **C.** Accurate keratometry is impossible and the patient should be asked to abstain from hard contact lens wear for one week.
- ✓ **D.** Accurate keratometry is impossible and the patient should be asked to abstain from hard contact lens wear for one month.

Check Answer

Intraocular Lens Selection Test Question

Larry has come to you for cataract surgery on his right eye. He is a keen amateur photographer and wishes to have good distance vision. Select an appropriate lens implant from this information and the biometry print out on this page.

The answer (scroll down)

Illustration 13.10 Intraocular lens selection test

CHAPTER 14

Finishing the operation

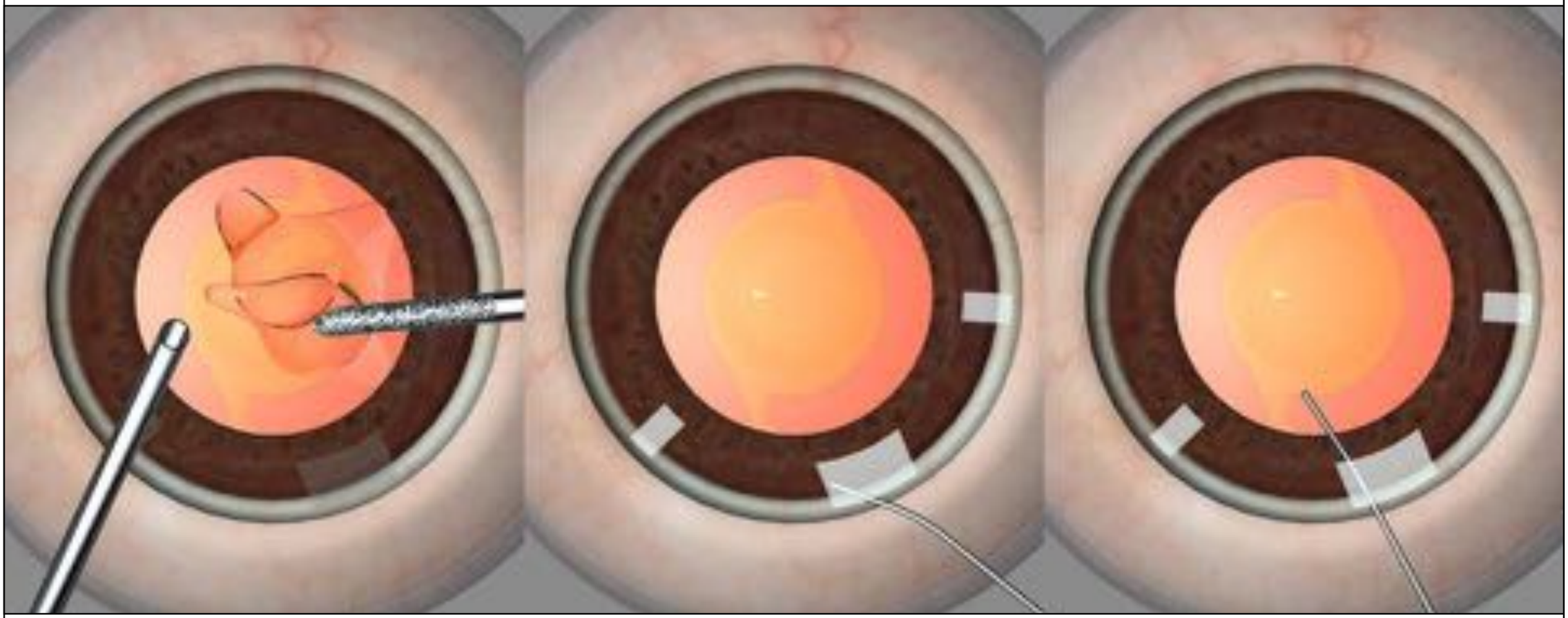

After the intraocular lens has been inserted the viscoelastic must be removed, the incisions made water-tight and intracameral antibiotics administered.

Removal of viscoelastic

Figure 14.1 Removal of viscoelastic

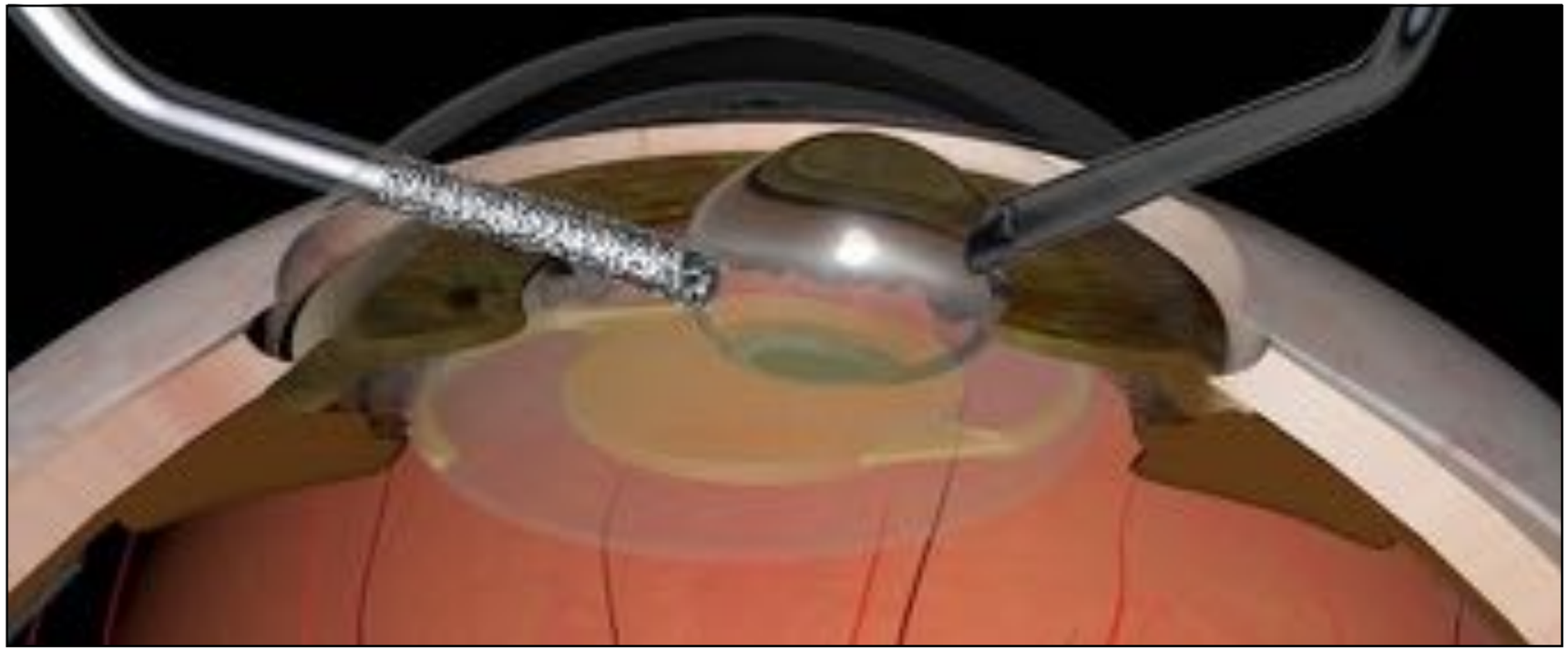

Viscoelastic agents are very useful during phacoemulsification but must be completely removed at the end of surgery as retained viscoelastic causes many problems.

The problems with retained viscoelastic.

- A large amount of viscoelastic in the anterior chamber interrupts aqueous flow, leading to very high intraocular pressure. If the anterior chamber contains alot of viscoelastic all the particulate matter in the anterior chamber appears stationary as the normal circulation of cells in aqueous stops.
- Even a small amount of some viscoelastics (especially dispersive viscoelastics) may exacerbate postoperative intraocular inflammation.
- Viscoelastic trapped behind the implant may lead to capsular block syndrome. The intraocular lens may be pushed forward inducing myopia. Slit lamp examination shows a characteristic posterior bowing of the posterior capsule.

Gallery 14.1 Intraocular pressure

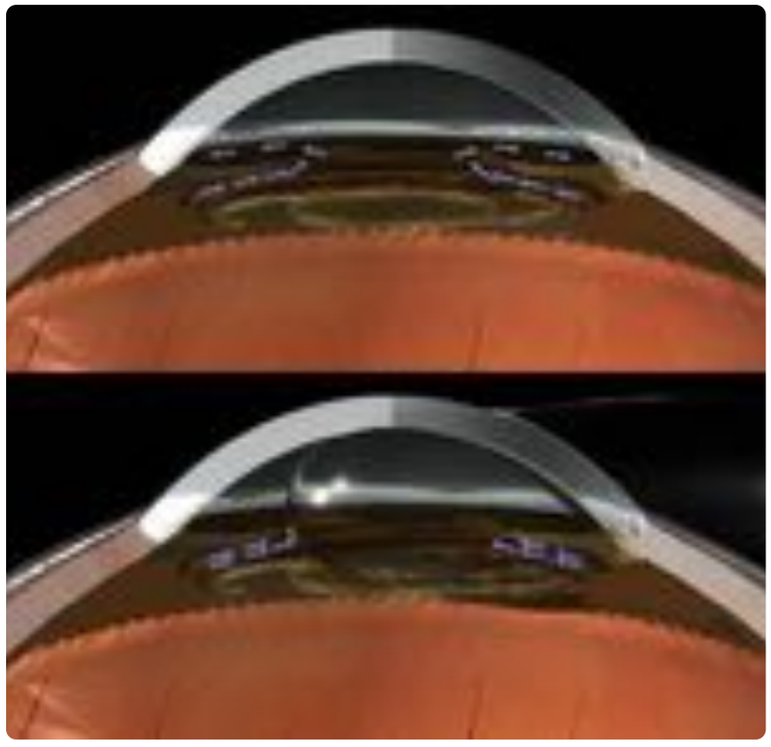

Viscoelastic (bottom picture) obstructing aqueous outflow though the iridocorneal angle.

Gallery 14.2 Capsular block syndrome



Retained viscoelastic behind the lens: as the located space between the lens and posterior capsule swells due to osmotic pressure, the posterior capsule is pushed posteriorly and the intraocular lens vaults forward. The resulting myopia is relieved by laser capsulotomy.

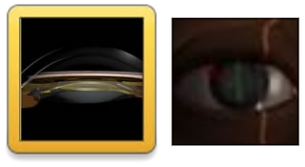

Removal of viscoelastic anterior to the intraocular lens

If a cohesive viscoelastic is used most of it will come out if an instrument with an infusion is inserted into the anterior chamber.

The instrument used for irrigation/aspiration is used to remove the residual viscoelastic.

Signs of complete viscoelastic removal

The anterior chamber is free of mobile visible streaks of viscoelastic and the intraocular lens wobbles with the jets of infusion fluid.

Gallery 14.3 Removal of viscoelastic

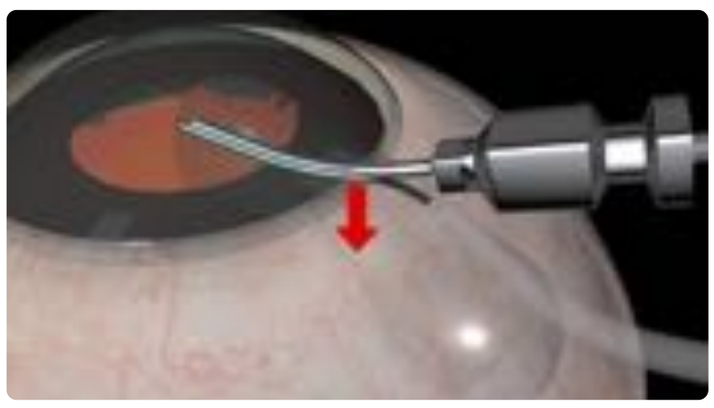

Slight downward pressure on the incision with the Simcoe cannula releases viscoelastic from the anterior chamber.

Removal of viscoelastic posterior to the intraocular lens

The aspiration instrument is placed behind the lens optic with the port facing anteriorly. Alternatively, repeated downward pressure is applied to the optic to push the trapped viscoelastic into the anterior chamber - this must be done repeatedly until it is clear that no viscoelastic remains.

Movie 14.1 Removal of viscoelastic

The viscoelastic behind the lens is removed by repeatedly pushing the optic posteriorly until no more streaks of viscoelastic appear and the implant starts to wobble with the jet of infusion fluid.

Movie 14.2 Removal of viscoelastic behind the lens

The aspiration port faces upwards (away from the posterior capsule) when aspirating. This eye had previously undergone penetrating keratoplasty)

Movie 14.3 Removal of posterior viscoelastic using a soft tipped aspiration instrument

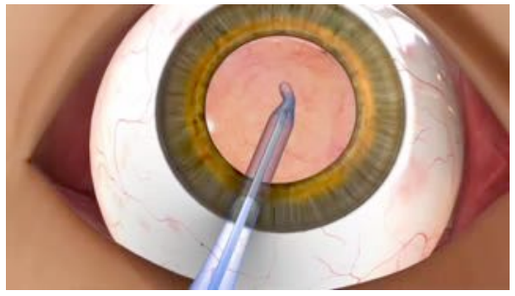

The safety margin using a silicone tip allows a more confident approach.

Incision closure

Figure 14.2 Incision closure

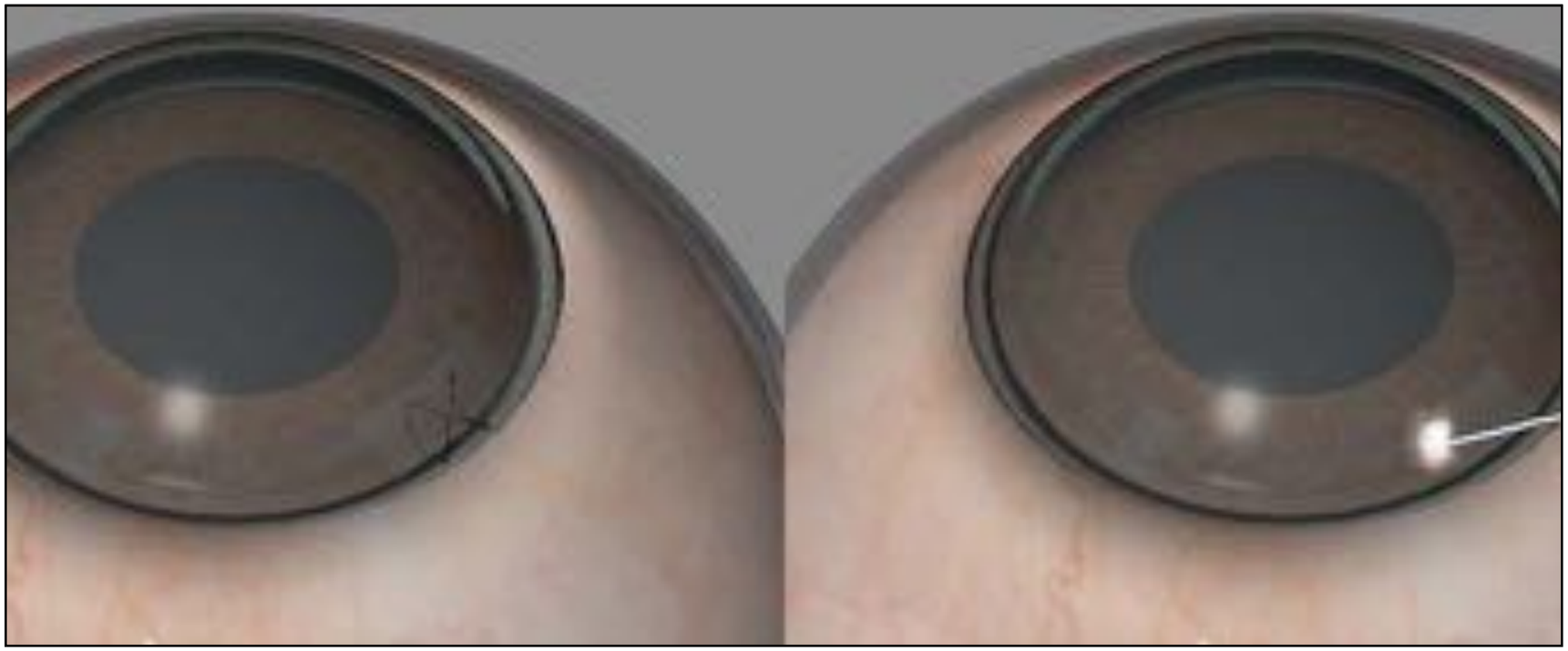

An insecure wound probably increases the risk of endophthalmitis.

Most wounds are either self sealing or close easily with stromal hydration: wound suturing is less commonly needed than it used to be due to the smaller incision used.

Stromal hydration

Injection of saline into the corneal stroma at each extremity of the incision causes the stroma to bulge, apposing the tissues.

Stromal hydration is a highly effective way of securing small incisions. It's effect lasts for at least 24 hours, giving time for tissue reactions to provide a permanent seal.

Checking wound integrity

Pressure is applied to the eye away from the incision site while the wound is observed for leakage. Many perfectly adequate self-sealing wounds will leak if local pressure is applied behind the incision - this is not an indication for suturing.

Indications for suturing

Suturing is very rarely required for routine phacoemulsification.

The threshold for suturing should however be low if there has been a wound burn or iris prolapse.

Movie 14.5 Check wound integrity.

The hydrated wounds remain water tight when the intraocular pressure is elevated.

Movie 14.4 Stromal hydration

Saline is injected into the corneal stroma the edge of the incision.

Injection of intracameral antibiotics

Figure 14.3 Prevention of post operative endophthalmitis.

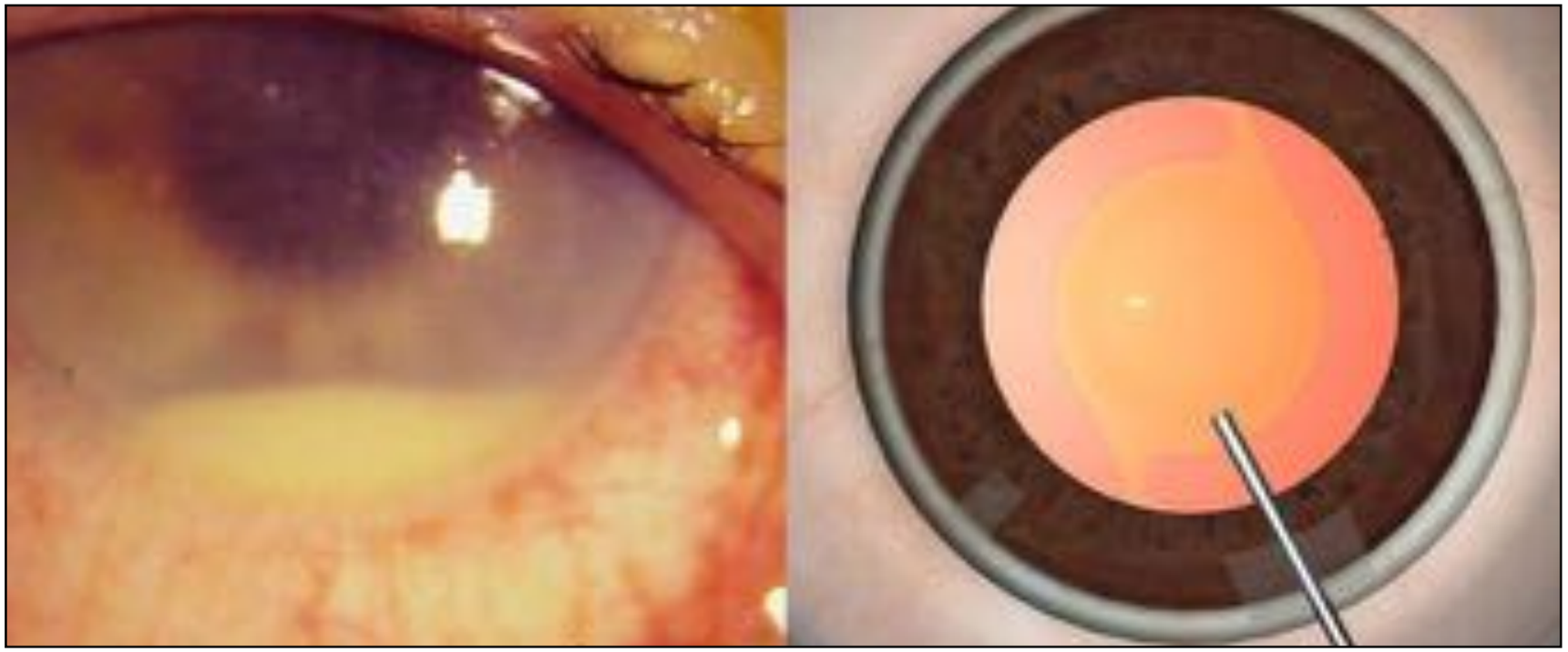

Injection of intracameral cefuroxime at the end of surgery is highly effective in preventing post operative endophthalmitis.